

Fibrosarcoma originating in the mandible

Andresa Borges Soares¹, Lauro Henrique Sousa Lins², Adriana Parizzoto Mazedo², Joao Sarmiento Pereira Neto³, Pablo Agustin Vargas¹

(1) Department of Oral Diagnosis, Oral Pathology Section, Dental School of Piracicaba, State University of Campinas, Piracicaba

(2) Faculty of Odontology of Plateau Catarinense, Lages

(3) Department of Orthodontic, Dental School, State University of Campinas, Piracicaba – SP, Brazil

Correspondence:

Prof. Dr Pablo Agustin Vargas,

Dpto. de Diagnostico Oral, Disciplina de Patologia,

Faculdade de Odontologia de Piracicaba-UNICAMP.

Av. Limeira 901, Piracicaba-SP, Brasil. Caixa Postal 52,

CEP:13414-903,

E-mail:pavargas@fop.unicamp.br

Received: 4-08-2005

Accepted: 10-03-2006

Indexed in:

-Index Medicus / MEDLINE / PubMed
-EMBASE, Excerpta Medica
-Indice Médico Español
-IBCS

Soares AB, Lins LHS, Macedo AP, Pereira-Neto JS, Vargas PA. Fibrosarcoma originating in the mandible. *Med Oral Patol Oral Cir Bucal* 2006;11:E243-6.

© Medicina Oral S. L. C.I.F. B 96689336 - ISSN 1698-6946

ABSTRACT

Fibrosarcoma is a malignant mesenchymal neoplasm of fibroblasts that rarely affects the oral cavity and can cause local recurrences or metastasis. In this article we describe a case of primary fibrosarcoma in the mandible in a 16-year-old girl. Microscopically the tumor showed an intense proliferation of spindle-shaped cells, varying little in size and shape and arranged in parallel bands, partly crossing each other, the mitotic activity was increased and there was nuclear pleomorphism. Immunohistochemically the cells only showed immunoreactivity for vimentin and negativity for S-100 protein, CD 68, cytokeratin cocktail, HMB-45, CD34, pan actin HHF 35, desmin, smooth muscle actin and epithelial membrane antigen (EMA). Based on clinical, radiological, histological and immunohistochemical findings the final diagnosis was high-grade intra-osseous fibrosarcoma. The treatment choice was radical surgery with mandibular reconstruction. After one year and nine months of the treatment the patient displayed multiple metastases. Radiation therapy and chemotherapy were used as adjuvant treatment. Unfortunately, the girl died two years after initial diagnosis.

Key words: Fibrosarcoma intra-osseous, immunohistochemistry, mandible.

INTRODUCTION

Fibrosarcoma is a malignant neoplasm of the fibroblastic origin. It can occur in any location being the bone extremities the main affected site. Occurrences in the maxilla are rare with an incidence ranging from 0 to 6.1% of all primary fibrosarcoma of the bone (1,2).

Radical surgery seems to be the best treatment option to fibrosarcoma (1). Radiation therapy has been used as adjuvant treatment in unresectable tumors and chemotherapy is only used for palliative treatment (3,4).

We reported a case of a fibrosarcoma originating in the mandible of a 16 year- old girl, which showed multiple metastases.

CASE REPORT

A 16-year-old girl was referred to the University of Planalto Catarinense, Brazil, in June 2001, with a painless swelling in the region of the right mandibular canine. Intraoral examination revealed a mild swelling in vestibular and lingual mandibular region. The orthopantomography revealed a little radiolucency lesion in the region of the right mandibular second premolar (Fig. 1). The patient has been using orthodontic appliance for one year because of posterior crossbite. The medical history showed no abnormalities. The general dentist preferred to follow-up this lesion because his supposed that the bone resorption was caused by the orthodontic appliance. One month later, in the new clinical examination, it was possible to observe an extensive swelling from the region of the right mandibular lateral incisor to the right mandibular second premolar (Fig. 2).

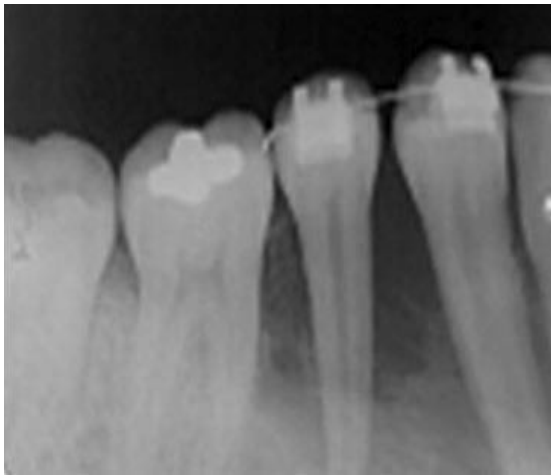


Fig. 1. Initial orthopantomography examination (June, 2001). The radiograph displayed a mild radiolucent lesion involving the right mandibular second premolar.

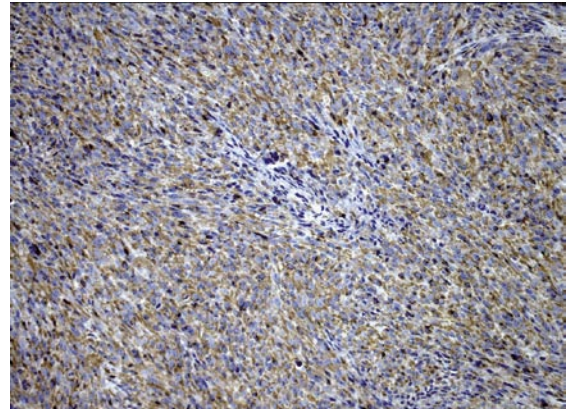


Fig. 5. Neoplastic cells displaying intense immunoreactivity for vimentin. (Immunohistochemistry for vimentin, x200).

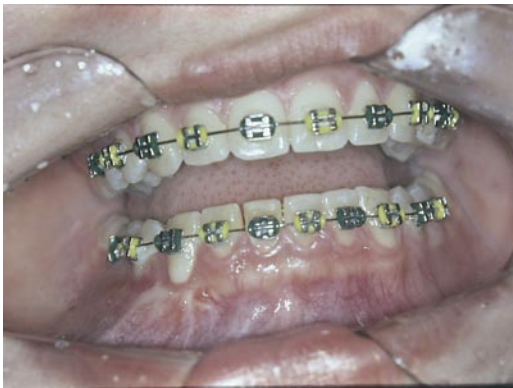

Fig. 2. Clinical appearance of intraosseous fibrosarcoma (august, 01, 2001) with extensive swelling from region of the right mandibular lateral incisor to the right mandibular second premolar.

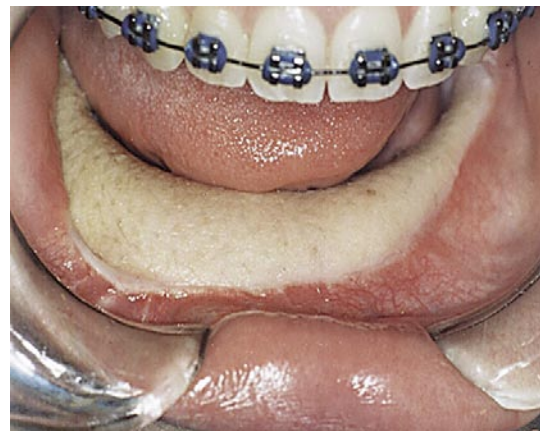

Fig. 6. Clinical aspect after total mandibulectomy.

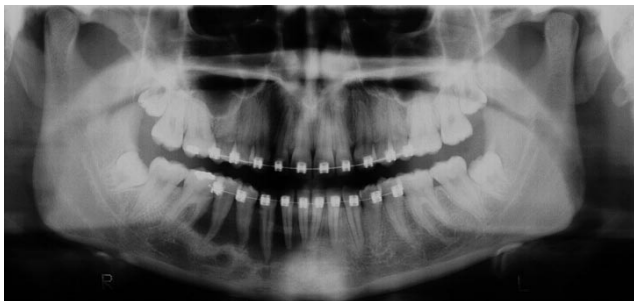


Fig. 3. Subsequent orthopantomography examination (august, 01, 2001). The radiograph showed a radiolucency undefined lesion extending from region of the left mandibular central incisor to the right mandibular first molar.

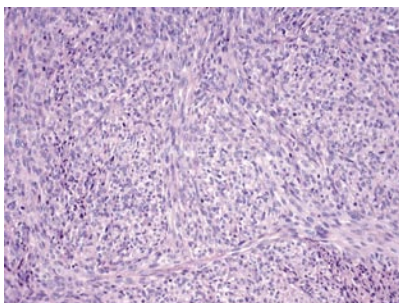


Fig. 4. High-power view showing high cellularity, intense proliferation of spindle-shaped cells and variable deposition of collagen (original magnification, H/E, x200).

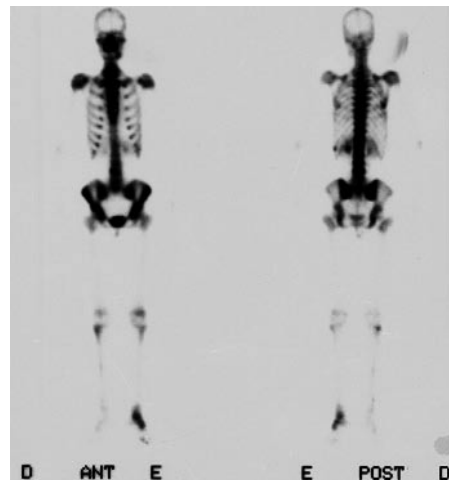


Fig. 7. Scintigraphy exhibiting metastases in articulations.

The radiographs displayed an undefined radiolucency lesion extending from region of the left mandibular central incisor to the right mandibular first molar (Fig. 3). An incisional biopsy was performed. Histopathological findings revealed an intense proliferation of spindle-shaped cells, varying little in size and shape and arranged in parallel bands, partly crossing each other. A high cellularity with a variable deposition of collagen was seen. The mitotic activity was increased and there was nuclear pleomorphism (Fig. 4). Immunohistochemically was carried out for the following markers: S-100 protein (Dako, Denmark, Glostrup, 1:10.000); CD68 (PG-M1; Dako, Denmark, Glostrup, 1:400); Cytokeratin cocktail (AE1/AE3; Dako, Denmark, Glostrup, 1:500); HMB-45 (Dako, Denmark, Glostrup, 1:200); CD34 (QBEnd10; Dako, Denmark, Glostrup, 1:50); Pan actin HHF35 (Dako, Denmark, Glostrup, 1:800); Vimentin (Vim3B4; Dako, Denmark, Glostrup, 1:400); Desmin (D33; Dako, Denmark, Glostrup, 1:1.000); Smooth muscle actin (1A4; Dako, Denmark, Glostrup, 1:400); Epithelial membrane antigen (E29; Dako, Denmark, Glostrup, 1:500). Immunohistochemically, vimentin positive cells were abundant (Fig 5), while other immunomarkers were negative. The final diagnosis was high-grade intra-osseous fibrosarcoma.

The treatment choice was radical surgery (mandibulectomy) with mandibular reconstruction (Fig 6). One year later we detected a suggestive area of lung metastasis analyzing a chest X-ray. An incisional biopsy in the lung was performed. Histopathological and immunohistochemical findings were similar to the primary mandibular tumor. The patient was treated by chemotherapy for three months. After six months, the patient showed numerous metastases (sternum, lung, kidney, spleen and articulation) (Fig 7). Radiation therapy and chemotherapy were used for more three months. Unfortunately, the patient died one month later.

DISCUSSION

Fibrosarcoma rarely affects the jaws bone. It is a tumor of mesenchymal origin and the epidemiologic factors are still unknown, but many authors report radiation therapy history as a possible one (3). In our case the patient had no history of previous radiation, and she was using orthodontic appliance for one year when the mandible fibrosarcoma occurred.

Fibrosarcoma can arise in soft tissues or within bone. Intra-osseous fibrosarcomas may develop endosteally or possibly periosteally, the latter affecting bone by spread from adjacent soft tissue (1,5). Occasionally, the lesion erodes the roots of involved teeth.

Clinically the lesion can cause pain, swelling, paraesthesia, and occasionally losing of teeth and ulceration of the overlying mucosa (1,6-8). Radiographically the tumor is seeing like an osteolytic lesion, with ill-defined borders, equally those seen in chondrosarcoma and osteolytic osteogenic sarcomas (1,5,8).

Histologically, the degree of differentiation is variable being comparable to a benign fibroma or an anaplastic tumor,

becoming a challenging diagnosis. Fibrosarcoma can be graded in low and high grade of malignancy. Low grade fibrosarcoma show spindle cells arranged in fascicles with low to moderate cellularity with a herringbone appearance. There is a mild degree of nuclear pleomorphism and rare mitosis, with a collagenous stroma (1,3,9). High-grade lesion showed an intense nuclear pleomorphism, greater cellularity, and atypical mitosis. The nuclei can be spindle shaped, oval or round nuclei (3). The histological appearance of high-grade fibrosarcoma may be similar to other tumors, as malignant fibrous histiocytoma, liposarcoma or synovial sarcoma (1). The positive immunostaining for vimentin, together with negativity for muscular immunomarkers help to diagnosis the fibrosarcoma. Another lesion that could be considered for differential diagnosis is fibromatosis, but in fibromatosis, generally, mitoses are absent and the grade of cellular atypia is very low (1). The intra-osseous fibrosarcoma affecting the jaws bone must be distinguished from odontogenic sarcomas as well. These tumors are classified in ameloblastic fibrosarcoma, ameloblastic fibrodentinosa sarcoma, ameloblastic fibro-odontosarcoma and odontogenic carcinosarcoma (10). Differently, oral intra-osseous fibrosarcoma not present hard or soft odontogenic tissues which are always seen in the odontogenic sarcomas (11).

The treatment choice to fibrosarcoma is radical surgery (1,7,12). Radiation therapy and chemotherapy can be used in the inoperable cases or as a palliative treatment (1,7,13). Prognosis is directly related to histological grade, tumor size and adequate surgery treatment with margins free (3).

REFERENCES

- Lo Muzio L, Mignogna MD, Pannone G, Staibano S, Testa NF. A rare case of fibrosarcoma of the jaws in a 4-year-old male. *Oral Oncol* 1998;34:383-6.
- Richardson JF, Fine MA, Goldman HM. Fibrosarcoma of the mandible: a clinicopathologic controversy: report of a case. *J Oral Surg* 1972; 30:664-8.
- Mark RJ, Sercarz JA, Tran L, Selch M, Calcaterra TC. Fibrosarcoma of the Head and Neck. The UCLA experience. *Arch Otolaryngol Head Neck Surg* 1991;117:396-401.
- McKenna WG, Barnes MM, Kinsella TJ, Rosenberg SA, Lack EE, Glatstein E. Combined modality treatment of adult soft tissue sarcomas of the head and neck. *Int J Radiat Oncol Biol Phys* 1987;13:1127-33.
- Van Blarcom CW, Masson JK, Dahlin DC. Fibrosarcoma of the mandible. A clinicopathologic study. *Oral Surg Oral Med Oral Pathol* 1971; 32:428-39.
- Sadoff RS, Rubin MM. Fibrosarcoma of the mandible: a case report. *J Am Dent Assoc* 1990;121:247-8.
- Handlers JP, Abrams AM, Melrose RJ, Milder J. Fibrosarcoma of the mandible presenting as a periodontal problem. *J Oral Pathol* 1985; 14:351-6.
- Pereira CM, Jorge Junior J, Di Hipólito O, Kowalski LP, Lopes MA. Primary intraosseous fibrosarcoma of jaw. *Int J Oral Maxillofac Surg* 2005;34:579-81.
- Antonescu CR, Erlandson RA, Huvos AG. Primary fibrosarcoma and malignant fibrous histiocytoma of bone – a comparative ultrastructural study: evidence of a spectrum of fibroblastic differentiation. *Ultrastruct Pathol* 2000;24:83-91.
- Mosqueda-Taylor A, Meneses-García A, Ruiz-Godoyrivera Lm, Suárez-Roa MI, Luna-Ortiz K. Malignant odontogenic tumors. A retrospective and collaborative study of seven cases. *Med Oral* 2003;8:110-21.
- Huguet P, Castellvi J, Avila M, Alejo M, Autonell F, Basas C, et al.

Ameloblastic fibrosarcoma: report of a case. Immunohistochemical study and review of the literature. *Med Oral* 2001;6:173-9.

12. Yamaguchi S, Nagasawa H, Suzuki T, Fujii E, Iwaki H, Takagi M et al. Sarcomas of the oral and maxillofacial region: a review of 32 cases in 25 years. *Clin Oral Invest* 2004;8:52-5.

13. Lukinmaa PL, Hietanen J, Swan H, Ylipaavalniemi P, Perkki K. Maxillary fibrosarcoma with extracellular immuno-characterization. *Br J Oral Maxillofac Surg* 1988;26:36-44.

Supported by: The State of Sao Paulo Research Foundation (FAPESP) and The National Council for Scientific and Technological Development (CNPq).