

This is an Open Access article licensed under the terms of the Creative Commons Attribution-NonCommercial 3.0 Unported license (CC BY-NC) (www.karger.com/OA-license), applicable to the online version of the article only. Distribution permitted for non-commercial purposes only.

Pattern Dystrophy of the Macula in a Case of Steinert Disease

Filipe Esteves^{a, b} Rosa Dolz-Marco^b Pablo Hernández-Martínez^b
Manuel Díaz-Llopis^{b, c} Roberto Gallego-Pinazo^b

^aDepartment of Ophthalmology, Centro Hospitalar de Entre o Douro e Vouga, Santa Maria da Feira, Portugal; ^bUnit of Macula and Medical Retina, Department of Ophthalmology, University and Polytechnic Hospital La Fe, and ^cFaculty of Medicine, University of Valencia, Valencia, Spain

Key Words

Maculopathy · Pattern dystrophy · Acquired vitelliform deposit · Myotonic dystrophy · Steinert disease

Abstract

Introduction: Myotonic dystrophies are typically associated with ocular complications like ptosis, weakness of the ocular muscle and cataracts, but also with less recognized retinal changes. **Case Report:** A 41-year-old female with type 1 myotonic dystrophy complained of progressive vision loss. Slit lamp examination revealed the presence of typical bilateral polychromatic cataract with posterior subcapsular component. Dilated fundus examination was remarkable for bilateral macular depigmented changes. Multimodal imaging analysis of the macula suggested the presence of a butterfly-shaped pattern dystrophy. **Discussion:** In cases of myotonic dystrophies it is of great relevance to analyze the presence of retinal changes that might limit the visual improvement following cataract extraction.

© 2013 S. Karger AG, Basel

Introduction

Pattern dystrophies of the retinal pigment epithelium (RPE) represent a group of heterogeneous disorders characterized by the development of a variety of patterns of yellow-orange-grayish pigment deposition above the RPE within the macular area [1]. These have traditionally been subdivided into 4 major patterns: butterfly dystrophy, reticular dystrophy, fundus pulverulentus and adult-onset foveomacular vitelliform dystrophy. The phenotype may vary among affected family members and even between the 2 eyes of the

Roberto Gallego-Pinazo, MD, PhD
Department of Ophthalmology
University and Polytechnic Hospital La Fe
Bulevar Sur s/n., ES-46026 Valencia (Spain)
E-Mail robertogallegopinazo@gmail.com

same patient [2]. The age of onset is highly variable, although most patients tend to remain asymptomatic until the fourth or fifth decade. The course is usually benign, but the disease may progress, leading to geographic atrophy of the RPE and/or choroidal neovascularization, therefore resulting in severe vision loss.

Pattern dystrophies have been occasionally associated with a variety of systemic disorders. Among these, myotonic dystrophy is an inherited disorder accompanied by progressive wasting and weakness of the distal muscles and myotonia. It is typically associated with ocular complications including ptosis, weakness of the ocular muscle and cataracts [3–5]. Herein, we report a clinical case illustrating the association of a pattern dystrophy of the RPE with type 1 myotonic dystrophy.

Case Report

A 41-year-old Hispanic female diagnosed with type 1 myotonic dystrophy (Steinert disease) was referred for ophthalmologic examination with the chief complaint of progressive vision loss. Her best-corrected visual acuity was 20/32 in her right eye and 20/40 in her left eye. Ocular motility was normal. She had bilateral ptosis with abnormal elevator function. Slit lamp examination revealed the presence a bilateral polychromatic cataract with posterior subcapsular component.

Dilated fundus examination was remarkable for macular pigmentary changes with multifocal yellowish depigmented patches within the macular area in both eyes (fig. 1). Fundus autofluorescence highlighted a branching linear pattern of mixed hyper- and hypoautofluorescence limited to the macular area in both eyes (fig. 1).

Optical coherence tomography images showed diffuse subretinal hyperreflective material between the photoreceptor layer and the RPE in both eyes. Larger focal vitelliform lesions were also evidenced. No subretinal or intraretinal fluid was found in association with the deposits (fig. 2).

Discussion

Type 1 myotonic dystrophy (Steinert disease) is a chronic, slowly progressing, highly variable, multisystemic disease produced by the expansion of the cytosine-thymine-guanine (CTG) triplet repeat in the DMPK gene (chromosome 19), which codes for myotonic dystrophy protein kinase [6, 7]. It is clinically characterized by muscular dystrophy, heart conduction defects, endocrine changes and myotonia. Although several reports previously described the ocular involvement in myotonic dystrophies, the majority of them refer to palpebral ptosis, cataract or ocular motility changes [3–5]. Very few publications raise the concern of retinal involvement in these patients with anecdotal reports about lamellar macular holes and foveoschisis [8], pigmentary changes of the RPE [9–12] or uveal melanoma [13].

In conclusion, although myotonic dystrophies are typically associated with cataracts, ophthalmologists should be aware of the presence of retinal changes that might limit the visual improvement following cataract extraction.

Disclosure Statement

The authors have no conflicts of interest to disclose.

References

- 1 Marmor MF, Byers B: Pattern dystrophy of the retinal pigment epithelium. *Am J Ophthalmol* 1976;13:112–116.
- 2 Yang Z, Li Y, Jiang L, Karan G, Moshfeghi D, O'Connor S, Li X, Yu Z, Lewis H, Zack D, Jacobson S, Zhang K: A novel RDS/Peripherin gene mutation associated with diverse macular phenotypes. *Ophthalmic Genet* 2004;25:133–145.
- 3 Pénisson-Besnier I, Lamirel C: Ocular disturbances in neuromuscular disorders. *Rev Neurol (Paris)* 2008;164:902–911.
- 4 Romeo V: Myotonic dystrophy type 1 or Steinert's disease. *Adv Exp Med Biol* 2012;724:239–257.
- 5 Turner C, Hilton-Jones D: The myotonic dystrophies: diagnosis and management. *J Neurol Neurosurg Psychiatry* 2010;81:358–367.
- 6 Mahadevan M, Tsilfidis C, Sabourin L, Shutler G, Amemiya C, Jansen G, Neville C, Narang M, Barceló J, O'Hoy K, et al: Myotonic dystrophy mutation: an unstable CTG repeat in the 3' untranslated region of the gene. *Science* 1992;255:1253–1255.
- 7 Harley HG, Walsh KV, Rundle S, Brook JD, Sarfarazi M, Koch MC, Floyd JL, Harper PS, Shaw DJ: Localisation of the myotonic dystrophy locus to 19q13.2–19q13.3 and its relationship to twelve polymorphic loci on 19q. *Hum Genet* 1991;87:73–80.
- 8 Louprasong AC, Light DJ, Diller RS: Spider dystrophy as an ocular manifestation of myotonic dystrophy. *Optometry* 2010;81:188–193.
- 9 Kimizuka Y, Kiyosawa M, Tamai M, Takase S: Retinal changes in myotonic dystrophy. Clinical and follow-up evaluation. *Retina* 1993;13:129–135.
- 10 Krishnan R, Lochhead J: Spontaneous bilateral lamellar macular holes and foveal schisis associated with myotonic dystrophy type 1. *Clin Experiment Ophthalmol* 2010;38:82–84.
- 11 Makino S, Ohkubo Y, Tampo H: Butterfly-shaped pattern dystrophy in myotonic dystrophy. *Intern Med* 2012;51:2253–2254.
- 12 Kim US, Kim JS, Hwang JM: A case of myotonic dystrophy with pigmentary retinal changes. *Korean J Ophthalmol* 2009;23:121–123.
- 13 Velazquez-Martin JP, Pavlin CJ, Simpson ER: Association between uveal melanoma and myotonic dystrophy: a series of 3 cases. *JAMA Ophthalmol* 2013;131:246–249.

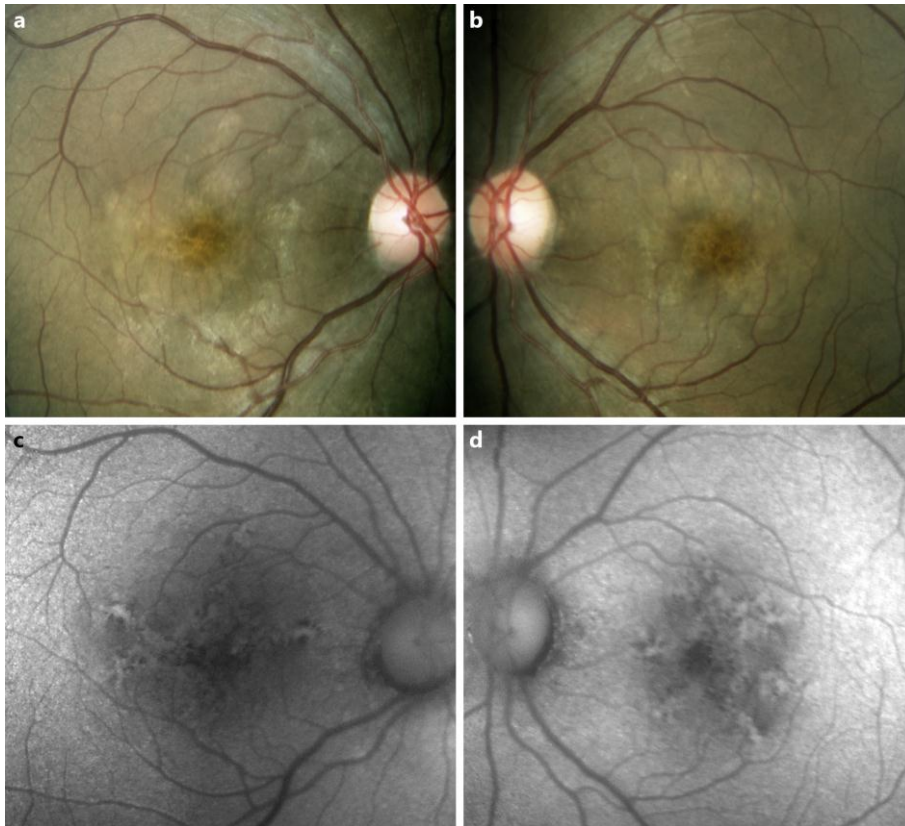


Fig. 1. Color photographs (**a**, **b**) show bilateral asymmetric irregular diffuse hypopigmented macular changes associated with focal hyperpigmented areas. A radial pattern of hyperautofluorescence was seen in the short-wavelength fundus autofluorescent images (**c**, **d**), consistent with butterfly-shaped macular pattern dystrophy. These lesions were associated with hypoautofluorescent patches corresponding to the areas of RPE hypertrophy.

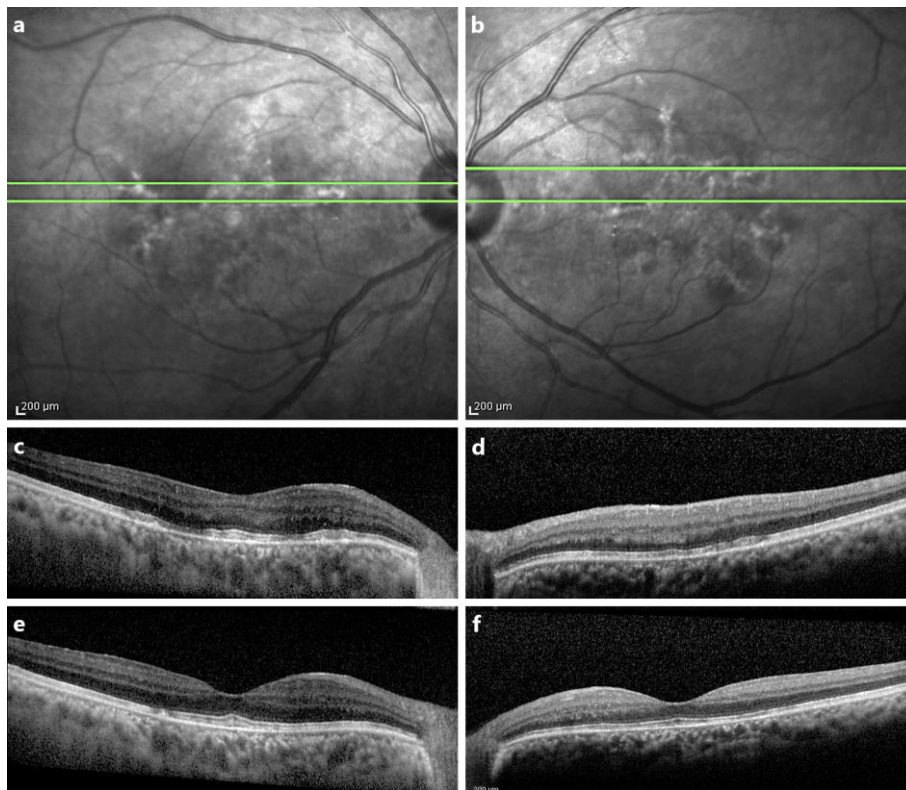


Fig. 2. The near-infrared fundus autofluorescence images (**a**, **b**) show a radial hyperautofluorescent pattern overlying a hypoautofluorescent background (butterfly-shaped macular pattern). Spectral-domain optical coherence tomography scans (**c–f**) reveal the presence of a diffuse subretinal hyperreflective material replacing the normal interdigitation zone with adjacent areas of mottled disruption of the outer retinal layers and focal hyperreflective subretinal deposits consistent with acquired vitelliform deposits.