

Ameoblastic carcinoma of mandible - A rare case report with review of literature

K Mubeen ¹, Hemant Kumar Shakya ², VR Jigna ³

¹ MDS, Professor and Head of Department, Department of Oral Medicine and Radiology, Government Dental College & Research Institute, Bangalore, India.

² Post graduate student, Department of Oral Medicine and Radiology, Government Dental College & Research Institute, Bangalore, India.

³ Post graduate student, Department of Oral Medicine and Radiology, Government Dental College & Research Institute, Bangalore, India.

Correspondence:

Dr Hemant Kumar Shakya

A-256, Mahesh Nagar, Jaipur, Rajasthan.

PIN: 302015

Email: shakyamds@gmail.com

Received: 15/02/2009

Accepted: 24/03/2010

Mubeen K, Shakya HK, Jigna VR. Ameoblastic carcinoma of mandible - A rare case report with review of literature. J Clin Exp Dent. 2010;2(2):e100-4.

<http://www.medicinaoral.com/odo/volumenes/v2i2/jcedv2i2p100.pdf>

Article Number: 678944 <http://www.medicinaoral.com/odo/indice.htm>
© Medicina Oral S. L. C.I.F. B 96689336 - eISSN: 1989-5488
eMail: jced@jced.es

Abstract

Ameloblastic carcinoma is a rare malignant lesion with characteristic histologic features and behavior that dictates more aggressive surgical approach than that of a simple ameloblastoma. However, reliable evidence of its biologic activity is currently unavailable due to the scarcity of well-documented cases. It occurs primarily in the mandible in a wide range of age groups; no sex or race predilection has been noted. It may present as a cystic lesion with benign clinical features or as a large tissue mass with ulceration, significant bone resorption and tooth mobility. Because the lesion is usually found unexpectedly after an incisional biopsy or the removal of a cyst, a guide to differential diagnosis is not usually useful. The identifying features of ameloblastic carcinoma must be known and recognized by dental practitioners. The tumour cells resemble the cells seen in ameloblastoma, but they show cytologic atypia. Moreover, they lack the characteristic arrangement seen in ameloblastoma. Direct extensions of the tumour, lymph node involvement and metastasis to various sites (frequently the lung) have been reported. We present a case of ameloblastic carcinoma of the mandible with a clinical course of typical aggressiveness and extensive local destruction in a 27 year old male patient.

Key words: Ameloblastoma, carcinoma, odontogenic carcinoma.

Introduction

Ameloblastic carcinoma (AC) is extremely rare, aggressive malignant epithelial odontogenic tumor with a poor prognosis. Two thirds of these tumors arise from the mandible while one third originate in the maxilla (1). The most common symptom is a rapidly progressing painful swelling. There is no consensus on the treatment of ACs; however, wide surgical excision with or without radiotherapy is the most common treatment modality (2).

The question of malignancy in ameloblastoma has been the subject of considerable discussion and controversy for many years. There can be little argument that an ameloblastoma that metastasizes is malignant, even if the tumour shows benign histological features. In other instances, ameloblastoma has been considered to be malignant on the basis of an aggressive clinical course in the absence of metastasis. These lesions often show unusual or atypical histological features (3). Carcinomas derived from ameloblastoma have been designated by a variety of terms, including malignant ameloblastoma, ameloblastic carcinoma, metastatic ameloblastoma and primary intra-alveolar epidermoid carcinoma. In 1971, the World Health Organization (WHO) published its classification of odontogenic carcinomas recognizing the following subtypes:

Malignant ameloblastoma

Primary intraosseous carcinoma

Other carcinomas arising from odontogenic epithelium, including those arising from odontogenic cysts.

In this classification, "malignant ameloblastoma" refers to a neoplasm in which typical histological features of ameloblastoma are seen in the primary tumour located in the jaw as well as in any associated metastatic deposits. "Primary intraosseous carcinoma" (PIOC) refers to a primary carcinoma of the jaw not having features of ameloblastoma and not arising from an odontogenic cyst. The "other carcinomas" category refers to carcinomas arising from odontogenic epithelium, including those arising from odontogenic cysts.

In 1982, Elzay (4) argued that the WHO classification does not make provision for separating tumors that are histologically identical to classic ameloblastoma and metastasize from ameloblastoma-like lesions that are histologically malignant before metastasizing. He proposed a modification of the classification in which all primary intraosseous carcinomas that do not involve the salivary glands would be classified as PIOC, which would then be sub classified as follows:

- Type 1: arising from an odontogenic cyst
- Type 2: arising from an ameloblastoma
 - a. Well differentiated (malignant ameloblastoma)
 - b. Poorly differentiated (ameloblastic carcinoma)
- Type 3: arising de novo
 - a. Nonkeratinizing

b. Keratinizing

In 1984, Slootweg and Müller (5) further emphasized that ameloblastoma may exhibit malignant features other than metastasis and suggested a modified classification system for malignant tumours with features of ameloblastoma, based on characteristics of malignancy:

- Type 1: PIOC ex odontogenic cyst
- Type 2:
 - a. Malignant ameloblastoma
 - b. Ameloblastic carcinoma, arising de novo, ex ameloblastoma or ex odontogenic cyst
- Type 3: PIOC arising de novo
 - a. Nonkeratinizing
 - b. Keratinizing

Elzay (4) and Slootweg and Müller (5) use the term ameloblastic carcinoma to convey the presence of cytologic features of malignancy. The degree of differentiation in epithelial neoplasms is usually considered to be significant in predicting biologic behaviour of metastasis. The main difference between Elzay's and Slootweg and Müller's schemes relates to the minor point of histogenesis. According to these authors, the term ameloblastic carcinoma should be used to designate lesions that exhibit histologic features of both ameloblastoma and carcinoma. The tumour may metastasize and histologic features of malignancy may be found in either the primary tumour, the metastases or both (5-7). The term malignant ameloblastoma should be confined to those ameloblastoma that metastasize despite an apparently typical benign histology in both the primary and the metastatic lesions (6,8). The incidence of ameloblastic carcinoma is greater than that of malignant ameloblastoma by a 2:1 ratio (3).

Case Report

27 year old male patient presented to the Department of Oral Medicine and Radiology, Government Dental College, Bangalore, Karnataka with a chief complaint of the pain and swelling over the left lower third of the face since 6 months (Fig. 1).

The patient gave a history of trauma to the region a year ago following which he developed pain sudden in onset, dull in nature, continuous, non-radiating, relieved partially with analgesics. Patient noticed a rapidly progressing swelling in the same region 6 months back, associated with pin and needle sensation of the lower lip. Patient had no complaint of dysphagia, trismus, dysphonia fever, chills or loss of weight and his past medical history was not significant. Clinical examination revealed a diffuse swelling over the left body of the mandible approximately 5x3 cm in size, surface smooth and overlying skin appeared normal. On palpation, the swelling was uniformly bony hard and tender with no local rise in temperature. Paresthesia of the lower lip was noted. Left submandibular lymph node was palpable,

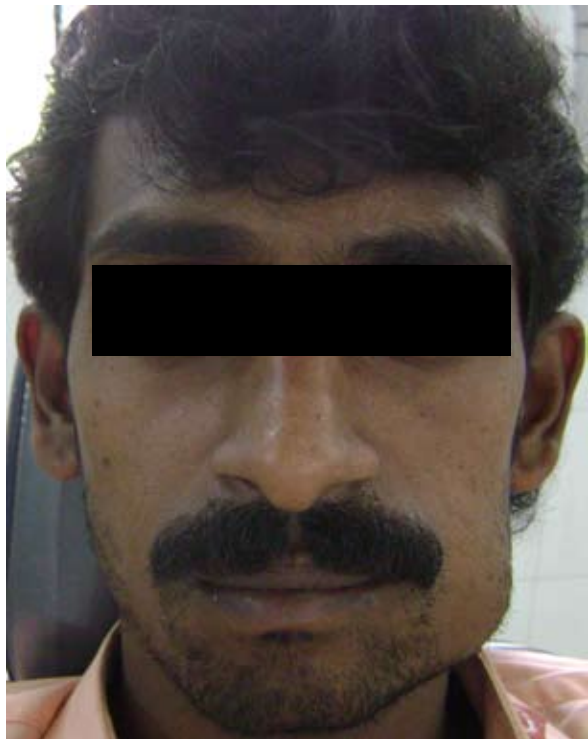

Fig. 1. Diffuse swelling over the left lower one-third of the face.

one in number, mobile, soft in consistency and tender. Intra-oral examination revealed a diffuse tender swelling of the lower buccal vestibule adjacent to 34, 35, 36, 37 and 38. A diffuse tender swelling of the lower lingual vestibule was also noted adjacent to 31, 32, 41 and 42. Hard tissue examination presented with Grade III mobility of 34, 35, 36, 37 and 38. On the basis of clinical

examination, provisional diagnosis of ameloblastoma left mandible was given. Differential diagnosis included odontogenic keratocyst, odontogenic myxoma and ameloblastic carcinoma. Patient was subject to routine radiographic investigation. The orthopantomography (OPG) showed well defined multilocular radiolucent lesion in the left angle, body of the mandible, crossing the midline to involve the right body of mandible with thinning of the lower border of mandible. OPG reveals resorption of roots of 36, 37, and 38 (Fig. 2).

Incisional biopsy taken from two sites, one from lingual aspect of 31 and 41 and second from buccal aspect of 36 and 37 showed follicles of odontogenic epithelium lined peripherally by tall columnar cells and central stellate reticulum like cells within a scanty connective stroma. Follicles showed varying histologic features like nuclear polymorphism, basal cell hyperplasia, squamous metaplasia with dyskeratosis, necrosis and cystic degeneration. The surface showed parakeratinized stratified squamous epithelium of gingiva, features suggestive of ameloblastic carcinoma (Fig. 3).

Discussion

In 1983, Shafer introduced the term ameloblastic carcinoma to describe ameloblastoma in which there had been histologic malignant transformation. Ameloblastic carcinoma occurs in a wide range of age groups, but the mean age of 30.1 years is in agreement with that reported for ameloblastomas. There is no apparent sex predilection. The most commonly involved area is the posterior portion of the mandible. The most common

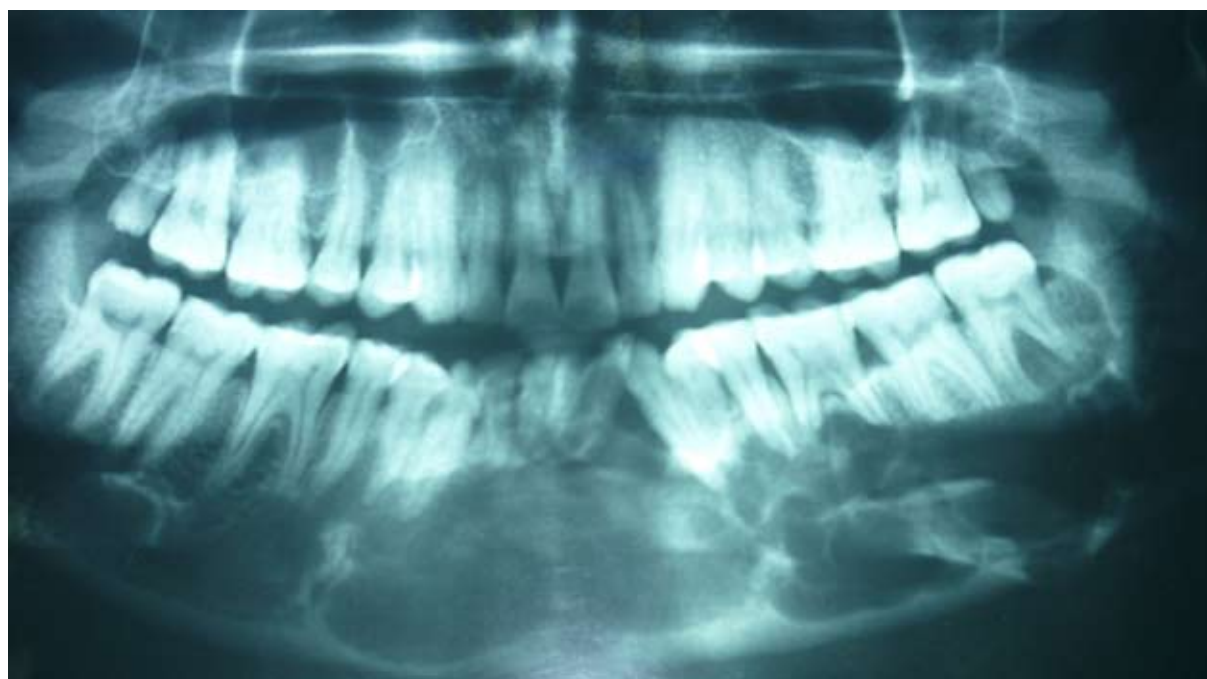


Fig. 2. Cropped OPG Showing the multilocular radiolucent lesion in left angle, body of mandible and crossing midline to involve the right body of mandible.

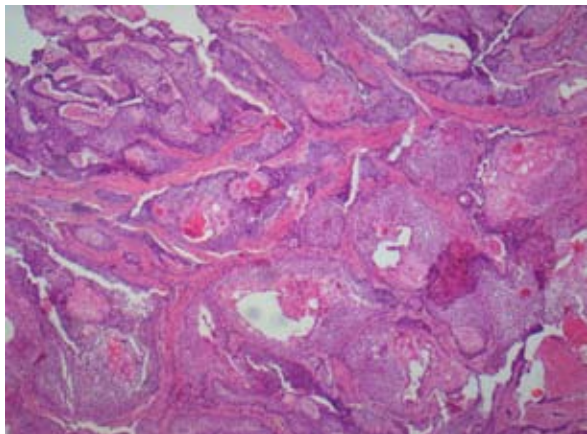


Fig. 3. Histological picture showing features of ameloblastic carcinoma.

sign described has been swelling, although others include associated pain, rapid growth, trismus and dysphonia (6). Involvement of the maxilla by ameloblastic carcinoma seems to be less frequent than that of the mandible (9-12). Histologically, ameloblastoma is a benign neoplasm that arises from the odontogenic apparatus and constitutes only 1% of tumors and cysts in the jaw. The malignant form of ameloblastoma has been controversial for many years. The term “malignant ameloblastoma” implies that lesions metastasize despite their benign histology. The term “ameloblastic carcinoma” is reserved for an ameloblastoma with a malignant morphologic appearance, regardless of the presence of metastasis. Ameloblastic carcinomas are extremely rare malignant odontogenic epithelial neoplasms and may arise de novo or from a pre-existing odontogenic lesion (13).

In our case study, the radiographic appearance of the lesion was consistent with that of an ameloblastoma except aspiration on fluid, with the histological finding suggestive of ameloblastic carcinomas.

These histologic and radiologic features are not generally seen in conventional ameloblastomas. Clinically, these carcinomas are more aggressive than most typical ameloblastomas. Perforation of the cortical plate, extension into surrounding soft tissue, numerous recurrent lesions and metastasis, usually to cervical lymph nodes, can be associated with ameloblastic carcinomas (6).

The characterization of carcinoma arising centrally within the mandible and the maxilla is an uncommon but complex problem. The first step in the staging process must be the exclusion of metastasis or invasion of bone by tumour from adjacent soft tissue or paranasal sinus. The neoplasm may be derived from a number of different sources, such as those of odontogenic origin, including ameloblastoma, odontogenic cysts or epithelial odontogenic rests, as well as entrapped salivary gland epithelium or epithelium entrapped along embryonic fusion sites. Carcinomas in the jaws metastasizing from primary locations such as the lung, the breast and the

gastrointestinal tract may mimic ameloblastic carcinoma and must always be ruled out clinically before that diagnosis is made (6,14).

Primary intra-alveolar epidermoid carcinoma must be considered in the differential diagnosis of ameloblastic carcinoma. This tumour, developing within bone, probably originates from odontogenic epithelial remnants (6). The two types of typical ameloblastoma must also be considered in the differential diagnosis of ameloblastic carcinoma. The acanthomatous ameloblastoma exhibits varying degrees of squamous metaplasia and even keratinization of the stellate reticulum portion of the tumour islands; however, peripheral palisading is maintained and no cytologic features of malignancy are found. The so-called kerato-ameloblastoma is a rare variant of ameloblastoma that contains prominent keratinizing cysts that may cause some alarm and distract the pathologist from the otherwise ameloblastomatous feature (6,14).

An additional consideration in the differential diagnosis is the squamous cell carcinoma arising in the lining of an odontogenic cyst (15).

Thus, the term ameloblastic carcinoma can be applied to our case, which showed focal histologic evidence of malignant disease including cytologic atypia and mitoses with indisputable features of classic ameloblastoma.

It is reasonable to assume that this case illustrates the malignant portion in the spectrum of ameloblastomas. It is possible that ameloblastoma shows a variety of histologic and biologic behaviours ranging from benignity to frank malignancy. Cases of ameloblastoma should thus be studied carefully, correlating their histologic pattern with biologic behavior to detect subtle changes in histology that may predict aggressive behavior.

The treatment of ameloblastic carcinoma is controversial, but the recommended surgical treatment usually requires jaw resection with 2- to 3-cm bony margins and consideration of contiguous neck dissection, both prophylactic and therapeutic.

Meticulous follow-up is essential because recurrence and metastasis in the lung and regional lymph nodes have been reported. Presurgical radiation therapy has been suggested to decrease tumour size, but chemotherapy is as yet unproven.

References

1. Lolachi CM, Madan SK, Jacobs JR. Ameloblastic carcinoma of the maxilla. *J Laryngol Otol.* 1995;109:1019-22
2. Dhir K, Sciubba J, Tufano RP. Ameloblastic carcinoma of the maxilla. *Oral Oncol.* 2003;39:736-41
3. Regezi JA, Kerr DA, Courtney RM. Odontogenic tumors: analysis of 706 cases. *J Oral Surg.* 1978; 36:771-8.
4. Elzay RP. Primary intraosseous carcinoma of the jaws. Review and update of odontogenic carcinomas. *Oral Surg Oral Med Oral Pathol.* 1982; 54:299-303.
5. Slootweg PJ, Müller H. Malignant ameloblastoma or ameloblastic carcinoma. *Oral Surg Oral Med Oral Pathol.* 1984; 57:168-76.
6. Corio LR, Goldblatt LI, Edwards PA, Hartman KS. Ameloblastic carcinoma: a clinicopathologic study and assessment of eight cases.

- Oral Surg Oral Med Oral Pathol. 1987; 64:570-6.
7. Lau SK, Tideman H, Wu PC. Ameloblastic carcinoma of the jaws. A report of two cases. *Oral Surg Oral Med Oral Pathol Oral Radiol Endod.* 1998; 85:78-81.
 8. Nagai N, Takeshita N, Nagatsuka H, Inoue M, Nishijima K, Nojima T, et al. Ameloblastic carcinoma: case report and review. *J Oral Pathol Med.* 1991; 20:460-3.
 9. Lee L, Maxymiw WG, Wood RE. Ameloblastic carcinoma of the maxilla metastatic to the mandible. Case report. *J Craniomaxillofac Surg.* 1990; 18:247-50.
 10. McClatchey KD, Sullivan MJ, Paugh DR. Peripheral ameloblastic carcinoma: a case report of a rare neoplasm. *J Otolaryngol.* 1989;18:109-11.
 11. Andersen E, Bang G. Ameloblastic carcinoma of the maxilla. A case report. *J Maxillofac Surg.* 1986; 14:338-40.
 12. Daramola JO, Abioye AA, Ajagbe HA, Aghadiuno PU. Maxillary malignant ameloblastoma with intraorbital extension: report of case. *J Oral Surg.* 1980; 38:203-6.
 13. Cizmecý O, Aslan A, Onel D, Demiryont M. Ameloblastic carcinoma ex ameloblastoma of the mandible: case report. *Otolaryngol Head Neck Surg.* 2004;130:633-4.
 14. Gandy SR, Keller EE, Unni KK. Ameloblastic carcinoma: report of two cases. *J Oral Maxillofac Surg.* 1992; 50:1097-102.
 15. Gardner AF. The odontogenic cyst as a potential carcinoma: A clinicopathologic appraisal. *J Am Dent Assoc.* 1969; 78:746-55.