

Journal section: Oral Medicine and Pathology
 Publication Types: Research

doi:10.4317/medoral.15.e671

Evaluation of the diagnostic value of a Modified Liquid-Based Cytology using OralCDx® Brush in early detection of oral potentially malignant lesions and oral cancer

Zahra Delavarian¹, Nooshin Mohtasham², Pegah Mosannen-Mozaffari³, Atessa Pakfetrat⁴, Mohammad-Taghi Shakeri⁵, Rasoul Ghafoorian-Maddah⁶

¹ Associated Professor of Oral Medicine, Dental Research Center of Mashhad Dental School, Mashhad University of Medical Sciences

² Associated Professor of Oral Pathology, Dental Research Center of Mashhad Dental School, Mashhad University of Medical Sciences

³ Assistant Professor of Oral Medicine, Dental Research Center of Mashhad Dental School, Mashhad University of Medical Sciences

⁴ Assistant Professor of Oral Medicine, Dental Research Center of Mashhad Dental School, Mashhad University of Medical Sciences

⁵ Associated Professor of Biostatistics, Department of Public Health and Community Medicine, Mashhad University of Medical Sciences

⁶ General pathologist

Correspondence:

Department of Oral Medicine
 Mashhad dental school
 Vakil abad BLY, Mashhad
 Khorasane Razavi Province, Iran
 Mosannenp@mums.ac.ir

Delavarian Z, Mohtasham N, Mosannen-Mozafari P, Pakfetrat A, Shakeri MT, Ghafoorian-Maddah R. Evaluation of the diagnostic value of a Modified Liquid-Based Cytology using OralCDx® Brush in early detection of oral potentially malignant lesions and oral cancer. Med Oral Patol Oral Cir Bucal. 2010 Sep 1;15 (5):e671-6.
<http://www.medicinaoral.com/medoralfree01/v15i5/medoralv15i5p671.pdf>

Received: 08/07/2009
 Accepted: 23/12/2009

Article Number: 3010 <http://www.medicinaoral.com/>
 © Medicina Oral S. L. C.I.F. B 96689336 - pISSN 1698-4447 - eISSN: 1698-6946
 eMail: medicina@medicinaoral.com
Indexed in:
 -SCI EXPANDED
 -JOURNAL CITATION REPORTS
 -Index Medicus / MEDLINE / PubMed
 -EMBASE, Excerpta Medica
 -SCOPUS
 -Indice Médico Español

Abstract

Objectives: To determine diagnostic value of modified Liquid Based Brush Biopsy technique.

Study design: 26 oral premalignant and malignant lesions in 25 patients (12 females; 54.23±19.77 years and 13 males; 53.77±15.43 years) underwent Modified (Liquid Based) Brush Biopsy and scalpel biopsy simultaneously from the same area.

Results: There were 16 positive and 10 negative brush biopsy results, with no inadequate readings. Histological findings were compatible with oral leukoplakia (n=5) with dysplasia, Oral lichen planus and lichenoid reaction (n=7) (with or without dysplasia) oral squamous cell carcinoma (n=11), verrucous carcinoma (n=1) and granular cell tumors (n=2). Sensitivity, specificity, positive predictive value, negative predictive value, positive diagnostic likelihood ratio (LR+) and negative diagnostic likelihood ratio (LR-) were 88.8%, 100%, 100%, 80%, infinity and 0.11 respectively (no false positive results).

Conclusion: It is the first attempt to do LBC (liquid based cytology) with a specialized oral brush. Our results show that modified technique is a useful tool for screening of oral premalignant and malignant lesions.

Key words: Precancerous conditions, brush biopsy, liquid-based cytology, diagnostic value, dysplasia, oral cancer.

Introduction

Oral squamous cell carcinoma (OSCC) is one of the most common cancers in some countries and very often arises from premalignant lesions such as leukoplakia, erythroplakia, and Oral Lichen Planus (OLP) (1). Detecting oral malignant and potentially malignant lesions in early stages dramatically affects survival rates. Unfortunately, 50% of patients have regional or distant metastases at the time of diagnosis, which reflects a significant diagnostic delay (2,3).

By far clinical examination and histopathological studies have been used for detection of precancerous and cancerous lesions (3). As with other fields of medicine, in oral cavity diagnostic approaches are going toward noninvasive, simple, inexpensive, painless and accessible methods such as cytology, brush biopsy, toluidine rinses, chemiluminiscent devices, and autofluorescence spectroscopy (3,4).

Brush biopsy using OralCDx® Brush (CDx laboratories US) is one of these new techniques emerging in the recent decade. Diagnostic value of exfoliative cytology and brush biopsy has been determined in many studies (5-9).

Since 1990, liquid-based cytology (LBC) has been designed to improve slide quality and quantity of conventional cytology (10). Instead of a unique smear, a suspension of cells is obtained and several slides could be prepared. Up to now, only few studies in oral cavity –based on LBC technique– have been published in English literature.

In Hayama study 2005, 44 different oral lesions were examined by both conventional and liquid based (Autocyte Inc) cytological examination using a cytobrush –not specific for oral mucosa. It was concluded that the two techniques led to the same diagnosis and the same papanicolao class assigned in all adequate cases. Three conventional smears were hypocellular, hence making the cytological diagnosis impossible. The LBC preparations showed a satisfactory higher improvement in slide quality (thinness, evenly cell distribution, absence of overlapping and bleeding...) (11).

In Navone study 2006, results of conventional exfoliative cytology and LBC (by using dermatologic curette) were compared with scalpel biopsy. Both sensitivity and specificity were better in LBC group than in conventional cytology. The false negative and positive results were 7/89 and 2/89 in conventional smear group and 4/384 and 3/384 in LBC group. Upon these results LBC gives better results and enhances sensitivity and specificity (12). It seems that OralCDx technique overestimates dysplastic lesions and has a low Positive Predictive Value (PPV) (13).

Although diagnostic value of brush biopsy or LBC technique have been published previously but there are some pitfalls:

First, in many brush biopsy studies not all of samples with different brush results underwent scalpel biopsy so the reported values for sensitivity, specificity, etc, could be questionable.

Second, in the case of performing both brush and biopsy, there are few, if ever, studies which both techniques are done simultaneously and exactly from the same area.

Third, all of LBC studies in oral cavity are performed using cervical or dermatological tools for sample collection and never a specialized oral tool (e.g. CDx brush) has been employed (11,12).

Because of non rigid nature of cervical brushes, inadequate results are expected. This leads to false negative results and significant diagnostic delay (14).

So, this study was planned to use LBC technique employing a specialized oral brush (OralCDx® Brush), simultaneously and exactly from the same area to determine the diagnostic value (sensitivity, specificity, positive and negative predictive values and positive and negative likelihood ratios) of modified LBC technique in detection of dysplasia /malignancy in oral potentially malignant and cancerous lesions and to evaluate diagnostic agreement between this technique and scalpel biopsy.

Materials and Methods

Since only a few laboratories evaluate the OralCDx® results by computer-assisted analysis, we examined microscopic slides visually. First, we designed a pilot study on 3 normal mucosa and 7 epithelial lesions to qualify slide properties, using standard protocol of OralCDx® kits. After manipulation of standard protocol neither the quality nor the quantity of slides were suitable for histopathologic diagnosis, so we applied an LBC technique and modified the conventional protocol in this way:

First, instead of spreading the brush onto a glass slide, the brush was placed in the supplied glass tube, containing formalin (10%), and sent to the cytopathology laboratory. There the brush and the formalin, containing cells dispersed from brush were placed in a vortex for 5 minutes in 4000 RPM. This centrifugal force helped to sediment the cells and take them off from the brush hairs. Then 100 λ (mm³) of this sediment was placed onto the cup of Cytospine (Shandon UK) centrifuge in 1000RPM (similar to power recommended in this vortex for vaginal samples). Two to 4 samples were obtained from each cellular sediment. The more the sediment was rich in cellular material or blood component, the more glass slides were prepared.

The study group consisted of 25 patients (Pts) with 26 lesions which had been visited from Oct 2005 to Jan 2007, at Oral Medicine Department of Mashhad Faculty of Dentistry and Otorhinolaryngology Departments of QAEM, IMAM REZA and OMID hospitals, Mashhad, Iran (Table 1).

Table 1. Demographic data in addition to clinical ,modified(Liquid-Based) brush biopsy and histopathological diagnosis.

pt No	Age _(Yrs.)	Sex*	Clin Dia. †	Brush Results	Histo Dia. ‡	(P.D.M.H) §
1	65	M	SCC¶	Pos	SCC	level 5
2	48	M	LEUK**	Pos	LEUK	level 3
3	71	M	SCC	Pos	SCC	level 5
4	67	F	SCC	Pos	SCC	level 5
5	74	M	LEUK	Pos	LEUK	level 1
6	40	M	LEUK	Neg	LEUK	level 2
7	79	F	LEUK	Neg	OLP††	level 1
8	70	F	SCC	Pos	SCC	level 5
9	49	F	SCC	Neg	GCT	Normal
10	74	F	SCC	Pos	SCC	level 5
11	73	F	Ver.car‡‡	Pos	Ver.car	level 5
12	55	F	OLP**	Pos	OLP	level 2
13	70	M	OLP	Neg	OLP	Normal
14	47	F	SCC	Pos	SCC	level 5
15	36	M	OLP	Neg	OLP	Normal
16	36	M	OLP	Neg	OLP	Normal
17	39	M	SCC	Pos	SCC	level 5
18	69	M	SCC	Pos	SCC	level 5
19	35	F	SCC	Pos	SCC	level 5
20	64	M	SCC	Pos	SCC	level 5
21	35	M	OLP	Neg	OLP	Normal
22	52	M	OLP	Neg	OLP	Normal
23	42	F	SCC	Neg	GCT	Normal
24	70	F	LEUK	Neg	LEUK	Normal
25 (Lesion1)	22	F	LEUK	Pos	LEUK	level 3
25 (Lesion2)	22	F	SCC	Pos	SCC	level 5

Abbreviations: *sex is defined as Male(M) and Female(F), †Clinical diagnosis,‡ histopathological diagnosis, § presence of dysplasia/malignancy in histopathology, ¶ squamous cell carcinoma, **leukoplakia, †† verrucous carcinoma, ‡‡ oral lichen planus or lichenoid reaction .Brush biopsy results are defined as Positive (Pos),Negative(Neg),and in adequate results(IAR).

The study protocol was approved by the committee on ethics of Mashhad University of Medical Sciences (MUMS) on the basis of the Helsinki Consent 2005. Patients were informed with regard to the research objectives, methods, possible benefits and potential risks and a written consent was obtained from all participants. Inclusion criterion was: lesions clinically diagnosed as oral potentially malignant (leukoplakia, OLP) or malignant lesions (OSCC and verrucous carcinoma) and requiring an incisional biopsy for definite diagnosis. Exclusion criteria were: A) History of any treatment for the lesion (drug, radiation, chemotherapy) and B) A systemic contraindication for scalpel biopsy.

The most impressive site of biopsy was determined upon one of these criteria:

- 1)The most probable site of dysplasia/malignancy (e.g. presence of firmness and indurations and roughness or red surface.
- Or 2) High risk areas for dysplasia/malignancy (e.g. Ventral tongue and floor of the mouth).
- Or 3) The most surgically accessible site.

Demographic data were recorded. After determination of the site of biopsy, under local anesthesia, needed for scalpel biopsy, the Oral CDx brush was placed in the selected area and turned 5 to 10 times until appearing pinpoint bleeding-upon to manufacturer’s recommen-

dition. The brush was sent to cytopathology laboratory immersing in supplied 10 %formalin glass tube. The scalpel biopsy was also done immediately in site of pin-point bleeding.

In cytopathology laboratory, the slides were prepared by Modified Liquid Based Techniques. By using cytopine vortex the cells were compacted in a 20mm² area Then they were fixed in 96° alcohol for 20 minutes and papanicolaou staining was done. They were examined by a pathologist informed about clinical diagnosis, but blind to the histopathological results; using Leica BME (Leica Buffalo state, US) microscopes in 100X and 400X magnifications.

The cytopathological findings were categorized as three groups:

- 1) Positive: dysplastic epithelial changes
- 2) Negative: absence of any evidence suggesting dysplasia
- 3) Inadequate sampling: means two entities:
 - A) Inadequate depth of sampling –absence of basal and parabasal cell layers in slide
 - B) Inadequate quantity of cells-hypocellularity

Photographs of diagnostic fields were taken by EX-WAVE HAD (Sony, Japan) camera and recorded using ASUS CAMCORDER software. The histopathologic preparations were observed by the same pathologist blind to cytopathological study and informed about clinical diagnosis.

The Pindborg criteria (15) for detecting dysplasia and malignancy were used and the histopathologic diagnosis was made. The presence of dysplasia/malignancy in histopathology(P.D.M.H) was classified as normal(no dysplasia/malignancy), mild, moderate and severe dysplasia (level 1 to 3), carcinoma In Situ (level 4) and carcinoma (level 5) (Table 1).

Quantitative variables were analyzed by T test as \pm SD and for qualitative variables χ^2 and Exact Fisher tests were done using SPSS11.5 software. Sensitivity, specificity, positive predictive value (PPV) and negative predictive value (NPV) were calculated for modified technique and clinical examination. Positive likelihood ratio (LR+) and negative likelihood ratio (LR-) were calculated for modified technique. Kappa value was calculated to determine diagnostic agreement between the modified technique and scalpel biopsy, the gold standard.

Results

Thirteen males and 21 females were contributed to this study. (Table 1). In one female patient (Table 1 -pt No 25) two sites with two different clinical diagnoses (one proved to be severely dysplastic and one OSCC in histopathologic assessment) were biopsied (Fig. 1). The mean age of patients was 54.00 ± 17.38 (12 females; 54.23 ± 19.77 and 13 males; 53.77 ± 15.43 years). T test revealed senile contingency in two groups. Six lesions

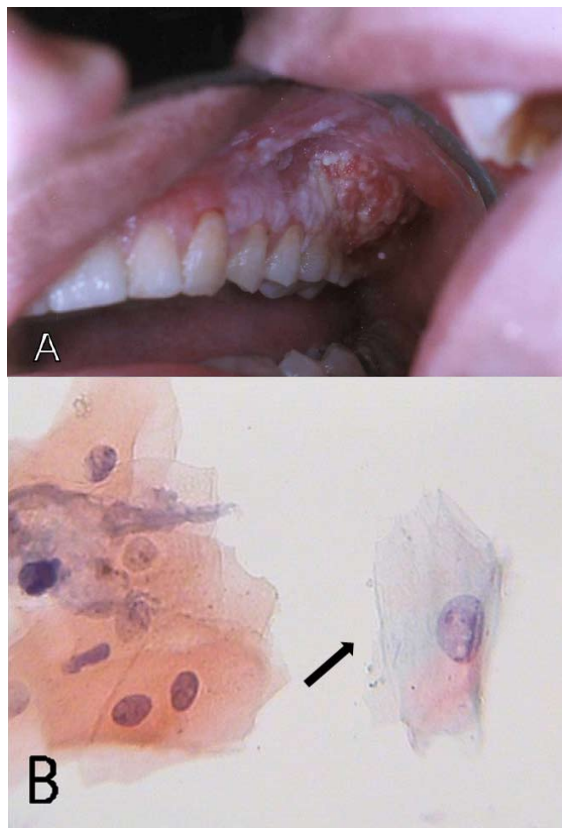


Fig. 1. Pt no.25.A) malignant changes (posterior portions) in a severely dysplastic leukoplakia(anterior portions) on maxillary gingiva.B)LBC prepared cytologic slides revealed dysplasia in leukoplakic area ,note to different nucleus size and high protein synthesis(↑ activity (100X magnification – Papanicolaou staining).

were clinically diagnosed as OLP, six as leukoplakia, 13 as OSCCs and one as verrucous carcinoma (Table 1).

The Modified LBC results showed 10 negative and 16 positive results, without any inadequate results, hence all the specimens included basal and parabasal layers and enough quantity.

Histopathologic results were as follow: (Table 1) 7 lesions diagnosed as OLP, 5 as leukoplakia, 11 as OSCC and one as verrucous carcinoma, two lesions (pt Nos 9 and 23), were diagnosed as Granular Cell Tumors (GCT) of tongue.

According to results; sensitivity, specificity, positive and negative predictive values of modified LBC technique were calculated respectively 88.8%, 100%, 100% and 80% (Table 2). Positive Diagnostic Likelihood Ratio (LR+) and Negative Diagnostic Likelihood Ratio (LR-) were infinity and 0.11 respectively (no false positive results).

Clinical diagnosis was in agreement in 88.4% (23/26) with histopathological findings. One lichenoid reaction clinically diagnosed as leukoplakia and two granular cell tumors clinically diagnosed as OSCCs.

Table 2. 2 x 2 contingency table for the modified (Liquid-based)brush biopsy compared to histopathologic study, the golden standard.

Brush biopsy results	Gold Standard		Total
	Normal	Disease (dysplasia / malignancy)	
	Positive	16	0
Negative	2	8	10
Total	18	8	26

In 92.3 % (24/26, $p < 0.001$) results of modified LBC were in agreement with presence of malignancy/dysplasia in histopathology. The two false negative results were outcomes of histopathologically focal dysplasia (One mild and one moderate dysplasia).

Kappa value (an index of diagnostic agreement) was calculated 0.806 for modified LBC and scalpel biopsy.

Discussion

In our study, sensitivity, specificity, PPV and NPV of modified LBC technique were calculated as follow: 88.8%, 100%, 100% and 80% (Table 2). All the samples contained cells of all epithelial layers (including basal and parabasal layers).

It is the first attempt to apply Liquid Based Cytology (LBC) using a specialized oral cytology instrument (OralCDx® Brush), hence other LBC studies in oral cavity have used cervical or dermatologic tools for sample collection (11,12).

Because of specialized designed rigid hairs of CDx brush, all the samples contained deep epithelial layers. This is an advantage, which can resolve the problem of false negative and inadequate results and help to improve sensitivity.

In our experience brush biopsy could reveal dysplastic changes in all OSCCs, and In four of six (86.5%) histopathologically dysplastic lesion, dysplasia was detected. Two focal dysplastic lesions had negative brush biopsy results. These two false negative results were observed in case no 6 and 7 (Table 1), both diagnosed clinically as oral leukoplakia (although histopathologic findings of case no 7 were compatible with OLP).

Although false negative ratio (11%=2/18) was slightly higher than other studies (3.5%, 1.9%, 5%) (9, 14,16,17), because of small sample size, especially in premalignant lesions, it is not possible to compare researches. In Svirsky research 2002, within 4 false negatives, only 1 “actually false negative” was reported. Other negative results seemed to originate from incompatible site and time of both biopsy techniques (7). In our study, performing brush biopsy simultaneously on the exact biopsy site could compensate this shortcoming.

Two clinically diagnosed malignancies (OSCCs)-proved to be granular cell tumors of tongue- had negative brush results. This suggests more specificity for brush compared to clinical diagnosis.

Sensitivity 88.8was almost similar to some results of oral exfoliative cytology researches (86.5%, 71.4%, 92.3%) (9,17,18) and in contrast to results of other study with extremely high sensitivity (100%) (19) 100% PPV was higher than previous studies (38.3% 7.4%and 7.9%) (7,13), it can be due to higher prevalence of dysplasia and malignancy in our sample group (20).

LR+ and LR- are two tools that combine information about the sensitivity and specificity of a test and are not commonly reported in oral medicine’s literature. LR+ >10 and LR- <0.1 makes a test suitable for clinical use .They were infinity and 0.11 respectively that empress positive results may be always true .it seems that this finding is because of great prevalence of disease in study group and larger sample size can near this result to more realistic value.LR- =0.11 shows “moderate decrease in the likelihood of the disease”.

There was a high diagnostic agreement between brush biopsy and histopathologic examination. In two dysplastic lesions the brush could not reveal atypical changes, so contingency coefficient was 92.3%.

Kappa value was calculated to show diagnostic agreement. Based on literature review Kappa value has not been calculated for brush biopsy yet. Kappa result (0.806) was greater than 0.7 and shows substantial agreement between brush biopsy and scalpel biopsy.

Based on our study, high sensitivity, specificity, LR+ and Kappa value, showed that modified LBC is a suitable test for clinical use. Our modification can eliminate some of disadvantages of the conventional, brush and liquid –based cytology, previously attempted in oral cavity.

References

1. Mehrotra R, Gupta A, Singh M, Ibrahim R. Application of cytology and molecular biology in diagnosing premalignant or malignant oral lesions. Mol Cancer. 2006;5:11.
2. Fedele S. Diagnostic aids in the screening of oral cancer. Head Neck Oncol. 2009;1:5.

3. Acha A, Ruesga MT, Rodríguez MJ, Martínez de Pancorbo MA, Aguirre JM. Applications of the oral scraped (exfoliative) cytology in oral cancer and precancer. *Med Oral Patol Oral Cir Bucal*. 2005;10:95-102.
4. Lingen MW, Kalmar JR, Karrison T, Speight PM. Critical evaluation of diagnostic aids for the detection of oral cancer. *Oral Oncol*. 2008;44:10-22.
5. Patton LL, Epstein JB, Kerr AR. Adjunctive techniques for oral cancer examination and lesion diagnosis: a systematic review of the literature. *J Am Dent Assoc*. 2008;139:896-905.
6. Trullenque-Eriksson A, Muñoz-Corcuera M, Campo-Trapero J, Cano-Sánchez J, Bascones-Martínez A. Analysis of new diagnostic methods in suspicious lesions of the oral mucosa. *Med Oral Patol Oral Cir Bucal*. 2009;14:E210-6.
7. Svirsky JA, Burns JC, Carpenter WM, Cohen DM, Bhattacharyya I, Fantasia JE, et al. Comparison of computer-assisted brush biopsy results with follow up scalpel biopsy and histology. *Gen Dent*. 2002;50:500-3.
8. Mehrotra R, Singh MK, Pandya S, Singh M. The use of an oral brush biopsy without computer-assisted analysis in the evaluation of oral lesions: a study of 94 patients. *Oral Surg Oral Med Oral Pathol Oral Radiol Endod*. 2008;106:246-53.
9. Scheifele C, Schmidt-Westhausen AM, Dietrich T, Reichart PA. The sensitivity and specificity of the OralCDx technique: evaluation of 103 cases. *Oral Oncol*. 2004;40:824-8.
10. Davey E, Barratt A, Irwig L, Chan SF, Macaskill P, Mannes P, et al. Effect of study design and quality on unsatisfactory rates, cytology classifications, and accuracy in liquid-based versus conventional cervical cytology: a systematic review. *Lancet*. 2006;367:122-32.
11. Hayama FH, Motta AC, Silva Ade P, Migliari DA. Liquid-based preparations versus conventional cytology: specimen adequacy and diagnostic agreement in oral lesions. *Med Oral Patol Oral Cir Bucal*. 2005;10:115-22.
12. Navone R, Burlo P, Pich A, Pentenero M, Broccoletti R, Marsico A, et al. The impact of liquid-based oral cytology on the diagnosis of oral squamous dysplasia and carcinoma. *Cytopathology*. 2007;18:356-60.
13. Bhoopathi V, Kabani S, Mascarenhas AK. Low positive predictive value of the oral brush biopsy in detecting dysplastic oral lesions. *Cancer*. 2009;115:1036-40.
14. Potter TJ, Summerlin DJ, Campbell JH. Oral malignancies associated with negative transepithelial brush biopsy. *J Oral Maxillofac Surg*. 2003;61:674-7.
15. Warnakulasuriya S, Reibel J, Bouquot J, Dabelsteen E. Oral epithelial dysplasia classification systems: predictive value, utility, weaknesses and scope for improvement. *J Oral Pathol Med*. 2008;37:127-33.
16. Christian DC. Computer-assisted analysis of oral brush biopsies at an oral cancer screening program. *J Am Dent Assoc*. 2002;133:357-62.
17. Navone R, Marsico A, Reale I, Pich A, Broccoletti R, Pentenero M, et al. Usefulness of oral exfoliative cytology for the diagnosis of oral squamous dysplasia and carcinoma. *Minerva Stomatol*. 2004;53:77-86.
18. Poate TW, Buchanan JA, Hodgson TA, Speight PM, Barrett AW, Moles DR, et al. An audit of the efficacy of the oral brush biopsy technique in a specialist Oral Medicine unit. *Oral Oncol*. 2004;40:829-34.
19. Sciubba JJ. Improving detection of precancerous and cancerous oral lesions. Computer-assisted analysis of the oral brush biopsy. U.S. Collaborative OralCDx Study Group. *J Am Dent Assoc*. 1999;130:1445-57.
20. Fist S. The oral brush biopsy: separating fact from fiction. *Oral Surg Oral Med Oral Pathol Oral Radiol Endod*. 2003;96:654-5.

Acknowledgement

The authors are most grateful to Prof. Dr Abbas Javadzadeh, who not only served as an excellent scientific consultant, but also encouraged and challenged us throughout our academic activity. We thank Dr R. Ghafoorian for his great ideas and literature review, Mr Berkani, and Dr Sharifi and Miss Delavar for preparing cytologic slides (Qaem hospital, cytopathology laboratory, Mashhad).

The authors also would like to extend their appreciation to the vice chancellor for research, MUMS (Mashhad University of Medical Sciences) for supporting this research.