

Journal section: Oral Surgery
 Publication Types: Research

doi:10.4317/medoral.15.e755

Distal probing depth and attachment level of lower second molars following surgical extraction of lower third molars: A literature review

Amparo Aloy-Prósper ¹, Berta García-Mira ², Carolina Larrazabal-Morón ³, Miguel Peñarrocha-Diago ⁴

¹ Student of Master of Oral Surgery and Implantology, Valencia University Medical and Dental School, Valencia, Spain

² Professor Assistant of Oral Surgery. Master of Oral Surgery and Implantology, Valencia University Medical and Dental School, Valencia, Spain

³ Master of Oral Surgery and Implantology, Valencia University Medical and Dental School, Valencia, Spain

⁴ Professor, Director of the Master of Oral Surgery and Implantology, Valencia University Medical and Dental School, Valencia, Spain

Correspondence:
 Clínicas Odontológicas
 C/ Gascó Oliag 1
 Valencia 46021, Spain
 berta.garcia@uv.es

Aloy-Prósper A, García-Mira B, Larrazabal-Morón C, Peñarrocha-Diago M. Distal probing depth and attachment level of lower second molars following surgical extraction of lower third molars: A literature review. Med Oral Patol Oral Cir Bucal. 2010 Sep 1;15 (5):e755-9.
<http://www.medicinaoral.com/medoralfree01/v15i5/medoralv15i5p755.pdf>

Received: 04/06/2009
 Accepted: 21/02/2010

Article Number: 2951 <http://www.medicinaoral.com/>
 © Medicina Oral S. L. C.I.F. B 96689336 - pISSN 1698-4447 - eISSN: 1698-6946
 eMail: medicina@medicinaoral.com
Indexed in:
 -SCI EXPANDED
 -JOURNAL CITATION REPORTS
 -Index Medicus / MEDLINE / PubMed
 -EMBASE, Excerpta Medica
 -SCOPUS
 -Indice Médico Español

Abstract

A review of the literature is made to evaluate factors that influence probing depth and attachment level on the distal aspect of the lower second molar (L2M) following extraction of a lower third molar (L3M).

The PubMed database was searched for studies published between 1997 and March 2009 using the following keywords: mandibular third molar, distal periodontal defect, distal probing depth, distal attachment level, flap design. Randomized prospective studies, with a minimum follow-up of three months for which the full text could be obtained, and that indicated the attachment level and/or probing depth on the distal surface of the L2M in both the preoperative and postoperative periods were included.

In the studies obtained, flap design had no influence on distal probing depth or distal attachment level of the L2M following extraction of an L3M. Curettage of the distal radicular surface of the L2M, together with oral hygiene control by the dentist, reduced probing depth values. Various authors recommend bone regeneration techniques in patients with a distal periodontal defect prior to extraction. The placing of membranes (resorbable or non-resorbable) is not justified; however, the use of demineralized bone powder or platelet-rich plasma gel reduces the distal probing depth and attachment level of the L2M.

Key words: Mandibular third molar, distal periodontal defect, distal probing depth, distal attachment level, flap design.

Introduction

Extraction of lower third molars (L3M) may produce a periodontal defect on the distal surface of the lower second molar (L2M) (1,9), characterized by an increased probing depth (distance in millimeters from the free gingival margin to the bottom of the gingival sulcus) and increased attachment level (distance in millimeters from the free gingival margin to cemento-enamel junction).

Advanced patient age (6,9), horizontal or mesial angulation of the L3M (2,6, 10-12), and the presence of plaque on the distal surface of the L2M (13,14) are related with a periodontal defect on the distal surface of L2M following surgery of L3M. However, in the studies found, the flap design had no relation with the presence of this defect (15-17). Dodson (6) recommends bone regeneration techniques when the L2M distal attachment level is greater than 3 mm. Various authors (11,12) propose these techniques when the probing depth is greater than 7 mm and attachment level is more than 6 mm.

The aim of the present study is to carry out a literature review to evaluate the factors that influence probing depth and attachment level on the distal surface of the L2M following extraction of the L3M.

Inclusion criteria and search strategy

Studies on distal probing depth and distal attachment level of L2M following extraction of L3M indexed in PubMed from 1997 to March 2009 were reviewed. Only randomized prospective studies with a minimum follow-up of three months, and with full text available, indicating the attachment level and/or probing depth on the distal surface of L2M in both the pre- and postoperative period were included.

The search was made on PubMed using the following keywords: third molar mandibular, distal periodontal defect, distal probing depth, distal attachment level, flap design. Articles published by the following journals were included: Journal of Oral and Maxillofacial Surgery, Oral Surgery Oral Medicine Oral Pathology Oral Radiology and Endodontology, Journal of Clinical Periodontology, International Journal of Oral and Maxillofacial Surgery, Minerva Stomatologica, Quintessence International, Acta Odontológica Latinoamericana, The International Journal of Periodontics & Restorative Dentistry, and The International Journal of Dental Hygiene.

Thirty-three articles were obtained, of which 25 were excluded; 4 for not being prospective studies, 2 for not being randomized, 7 for not having the full text available, and 12 for not presenting data on probing depth and/or attachment level in both the pre- and postoperative periods. Eight studies were included.

Results

Flap design

Suarez-Cunqueiro et al. (16) carried out bilateral surgical extraction of the L3M in 27 patients. They designed a bayonet flap for one side (Fig. 1a), and on the opposite side used the same flap, but respecting the keratinized gingival border of the L2M (Fig. 1b); they found no statistically significant differences in probing depth distal of L2M in function of flap design.

Authors such as Rosa et al. (15) and Kirtiloğlu et al. (17), found no statistically significant differences in attachment level and probing depth between the flap designed by Szmyd (Fig. 1c), the modified flap also described by Szmyd (Fig. 1d) and the bayonet flap following extraction of L3M (Table 1).

Dental hygiene

According to Leung et al. (13), curettage of the distal radicular surface of L2M when extracting the L3M, together with chlorhexidine mouthrinse at 0.12%, twice a day for two weeks, and oral hygiene control by the dentist every six weeks, reduced probing depth distal to L2M from 5.6 ± 2.2 mm to 3.2 ± 1.2 mm with respect to the control group, although the difference was not statistically significant. However, Pons-Vicente et al. (14) in a study with 43 patients, carried out scaling of the distal surface of the L2M by ultrasound or with curettes, finding a greater reduction in probing depth in the patients treated with ultrasound, but without statistical significance.

Bone regeneration techniques

Dodson (6) recommends bone regeneration techniques in patients with a distal periodontal defect defined as a more than 3 mm attachment level distal to L2M, prior to the extraction of L3M. Various authors (11,12) propose the use of these techniques when probing depth is more than 7 mm and attachment level above 6 mm. The bone regeneration techniques used in the different studies appear in (Table 2).

In one study, Dodson (10) in 24 patients undergoing bilateral extraction of L3M, compared placing demineralized bone powder or a resorbable membrane on one side, with the opposite side where no type of regeneration was made. The bone graft was compacted into the post-extraction alveolar socket and then sutured. The membrane was hydrated with saline solution and fitted around the alveolar bone extending 3 mm on both sides of the crest and then sutured; there were no statistically significant differences between the two techniques. However, when carrying out the same study design in patients with a prior periodontal defect distal of L2M, the same author (6) found a statistically significant reduction in attachment level from 7.6 ± 3.5 mm to 1.4 ± 0.5 mm after 26 weeks in the group with bone graft against the control group. However, there were no statistically significant differences between the control group and

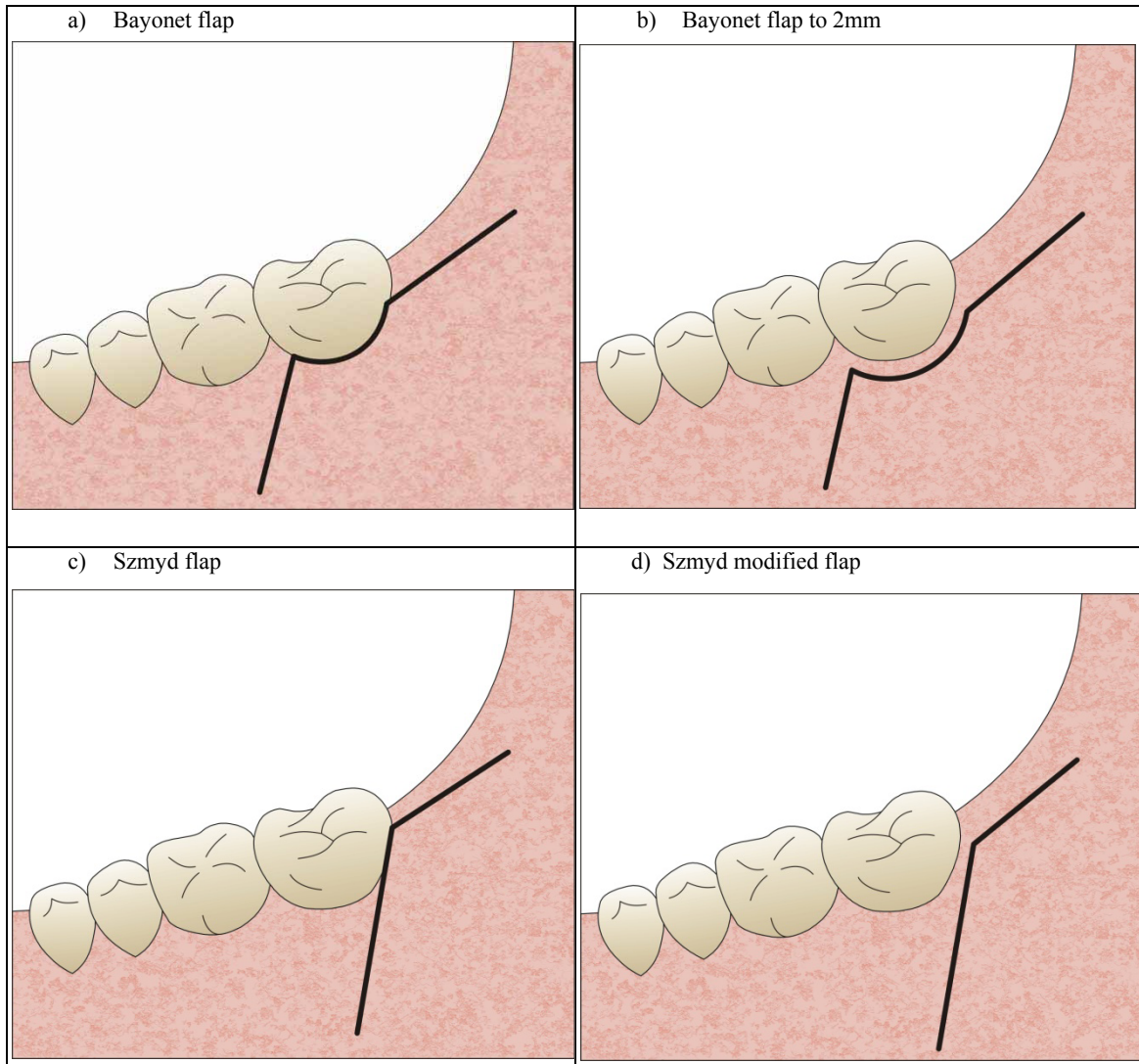


Fig. 1. Flap designs.

Table 1. Influence of flap design.

STUDY	N° patients	Age (years)	Variable	Flap design	Follow-up (months)	Influence of flap design on variable
Rosa et al. 2002 (15)	16	18-25	PD	Bayonet flap Szmyd flap	6	Not significant
			AL	Bayonet flap Szmyd flap	6	Not significant
Suarez-Cun-queiro et al. 2003 (16)	27	±22	PD	Bayonet flap to 2mm Bayonet flap	3	Not significant
Kirtiloğlu et al. 2007 (17)	18	16-32	PD	Bayonet flap Szmyd modified flap	12	Not significant

PD: Probing depth
AL: Attachment level

Table 2. Influence of bone regeneration techniques.

STUDY	N° patients	Age (years)	Variable	Regeneration technique	Follow-up (weeks)	Influence of regeneration technique on variable
Karapataki et al. 2000 (11)	19	36-50	PD	Resorbable membrane Non resorbable membrane	12	Not significant
			AL	Resorbable membrane Non resorbable membrane	12	Not significant
Dodson. 2005 (6)	24	26-48	AL	Resorbable membrane Control Demineralized bone powder Control	26	Significant
Sammartino et al. 2005 (12)	18	21-26	PD	Platelet-rich plasma Control	12	Significant
					18	Significant
			AL	Platelet-rich plasma Control	12	Significant
					18	Significant

PD: Probing depth
AL: Attachment level

group with the resorbable membrane. According to the author, patients over 26 years of age, with a prior periodontal defect and horizontal or mesial angulation of L3M may benefit from bone regeneration techniques. Similarly, Karapataki et al. (11) after placing resorbable or non-resorbable membranes in 19 patients found no statistically significant differences in the postoperative probing depth and attachment level. Sammartino et al. (12) in a study of 18 patients found a significant reduction in probing depth and attachment level in those cases treated with platelet-rich plasma gel against the control group. This gel is placed in the interior of the post-extraction alveolar socket and then sutured to obtain healing by first intention.

Conclusion

Flap design does not influence probing depth or attachment level on the distal aspect of the L2M following surgery of the L3M. Curettage of the radicular surface of L2M together with oral hygiene control reduces these clinical parameters. Bone regeneration techniques with bone graft are recommended in cases of prior periodontal defect distal to L2M.

References

- Oxford GE, Quintero G, Stuller CB, Gher ME. Treatment of 3rd molar-induced periodontal defects with guided tissue regeneration. *J Clin Periodontol.* 1997;24:464-9.
- Karapataki S, Hugoson A, Kugelberg CF. Healing following GTR treatment of bone defects distal to mandibular 2nd molars after surgical removal of impacted 3rd molars. *J Clin Periodontol.* 2000;27:325-32.
- Polat HB, Ozan F, Kara I, Ozdemir H, Ay S. Prevalence of commonly found pathoses associated with mandibular impacted third molars based on panoramic radiographs in Turkish population. *Oral Surg Oral Med Oral Pathol Oral Radiol Endod.* 2008;105:e41-7. Epub 2008 Apr 16.
- Kan KW, Liu JK, Lo EC, Corbet EF, Leung WK. Residual periodontal defects distal to the mandibular second molar 6-36 months after impacted third molar extraction. *J Clin Periodontol.* 2002;29:1004-11.
- Richardson DT, Dodson TB. Risk of periodontal defects after third molar surgery: An exercise in evidence-based clinical decision-making. *Oral Surg Oral Med Oral Pathol Oral Radiol Endod.* 2005;100:133-7.
- Dodson TB. Is there a role for reconstructive techniques to prevent periodontal defects after third molar surgery? *Oral Maxillofac Surg Clin North Am.* 2007;19:99-104, vii.
- Karaca I, Simşek S, Uğar D, Bozkaya S. Review of flap design influence on the health of the periodontium after mandibular third molar surgery. *Oral Surg Oral Med Oral Pathol Oral Radiol Endod.* 2007;104:18-23. Epub 2007 Apr 20.
- Chaves AJ, Nascimento LR, Costa ME, Franz-Montan M, Oliveira-Júnior PA, Groppo FC. Effects of surgical removal of mandibular third molar on the periodontium of the second molar. *Int J Dent Hyg.* 2008;6:123-8.

9. Peñarrocha Diago M, Galán Gil S, Peñarrocha Diago M. Vestibular bone window for the extraction of impacted lower third molars: four case reports. *Med Oral Patol Oral Cir Bucal*. 2008;13:E508-10.
10. Dodson TB. Management of mandibular third molar extraction sites to prevent periodontal defects. *J Oral Maxillofac Surg*. 2004;62:1213-24.
11. Karapataki S, Hugoson A, Falk H, Laurell L, Kugelberg CF. Healing following GTR treatment of intrabony defects distal to mandibular 2nd molars using resorbable and non-resorbable barriers. *J Clin Periodontol*. 2000;27:333-40.
12. Sammartino G, Tia M, Marenzi G, di Lauro AE, D'Agostino E, Claudio PP. Use of Autologous platelet-rich plasma (PRP) in periodontal defect treatment after extraction of impacted mandibular third molars. *J Oral Maxillofac Surg*. 2005;63:766-70.
13. Leung WK, Corbet EF, Kan KW, Lo EC, Liu JK. A regimen of systematic periodontal care after removal of impacted mandibular third molars manages periodontal pockets associated with the mandibular second molars. *J Clin Periodontol*. 2005;32:725-31.
14. Pons-Vicente O, Valmaseda-Castellón E, Berini-Aytés L, Gay-Escoda C. Effect on pocket depth and attachment level of manual versus ultrasonic scaling of lower second molars following lower third molar extraction: a randomized controlled trial. *Oral Surg Oral Med Oral Pathol Oral Radiol Endod*. 2009 Mar;107:e11-9.
15. Rosa AL, Carneiro MG, Lavrador MA, Novaes AB Jr. Influence of flap design on periodontal healing of second molars after extraction of impacted mandibular third molars. *Oral Surg Oral Med Oral Pathol Oral Radiol Endod*. 2002;93:404-7.
16. Suarez-Cunqueiro MM, Gutwald R, Reichman J, Otero-Cepeda XL, Schmelzeisen R. Marginal flap versus paramarginal flap in impacted third molar surgery: a prospective study. *Oral Surg Oral Med Oral Pathol Oral Radiol Endod*. 2003;95:403-8.
17. Kirtiloğlu T, Bulut E, Sümer M, Cengiz I. Comparison of 2 flap designs in the periodontal healing of second molars after fully impacted mandibular third molar extractions. *J Oral Maxillofac Surg*. 2007;65:2206-10.