

Journal section: Oral Surgery
 Publication Types: Research

doi:10.4317/medoral.15.e499

Oroantral communications. A retrospective analysis

Josué Hernando ¹, Lorena Gallego ¹, Luis Junquera ², Pedro Villarreal ²

¹ Resident. Department of Oral and Maxillofacial Surgery. Central University Hospital, Oviedo, Spain

² Staff Surgeon. Department of Oral and Maxillofacial Surgery. Central University Hospital, Oviedo, Spain

Correspondence:

School of Dentistry
 University of Oviedo
 Catedrático José Serrano s/n
 33009 Oviedo. Spain
 Junquera@uniovi.es

Hernando J, Gallego L, Junquera L, Villarreal P. Oroantral communications. A retrospective analysis. Med Oral Patol Oral Cir Bucal. 2010 May 1;15 (3):e499-503.

<http://www.medicinaoral.com/medoralfree01/v15i3/medoralv15i3p499.pdf>

Received: 18/04/2009
 Accepted: 20/09/2009

Article Number: 2855 <http://www.medicinaoral.com/>
 © Medicina Oral S. L. C.I.F. B 96689336 - pISSN 1698-4447 - eISSN: 1698-6946
 eMail: medicina@medicinaoral.com
Indexed in:
 -SCI EXPANDED
 -JOURNAL CITATION REPORTS
 -Index Medicus / MEDLINE / PubMed
 -EMBASE, Excerpta Medica
 -SCOPUS
 -Indice Médico Español

Abstract

Objective. To analyze characteristics, clinical evolution and surgical techniques of oroantral communication (OAC).

Study Design. We included all patients operated at the University Central Hospital (Oviedo, Spain) between 1996 and 2007. The variables assessed were age, sex, medical history, OAC size, sinus disease, surgical technique, duration of hospitalization and post-surgical evolution.

Results. We analyzed 12 patients (7 men and 5 women) with an average age of 47.5 years. The most frequent cause of oroantral communication was the extraction of the first upper molar. The average size of fistula was 0.9 cm. Buccal flap repair was used in 7 patients, palatal rotation-advancement flap in 4 patients and buccal fat pad in only one patient. Suture dehiscence was observed in one patient treated with a palatal flap, but no additional surgery was required. Three OAC recurred; all of them following a buccal flap procedure. All recurrences spontaneously closed between one and four months following the procedure.

Conclusion. OACs are rare complications and treatment should be individualized to avoid further complications.

Key words: Oroantral communication, oro-sinus communication, surgical technique.

Introduction

Oroantral communications (OAC) are rare complications of oral surgery. The extraction of maxillary posterior teeth is the most common cause of OAC (80%), because of the anatomic close relationship between the root apices of the premolar and molar teeth and the sinus floor. Maxillary cysts (10-15%), benign or malignant tumors (5-10%) and trauma (2-5%) can be other causes of OAC (1-3). Defects less than 3 mm tend to close spontaneously, whereas those larger than this size require

surgical treatment (3,4). Sinus disease is the most important factor for chronicity (5).

Buccal flap, described by Rehrmann (6), palatal rotation-advancement flap (7) and use of buccal fat pad (8) could be successful techniques to close OAC, although the choice of the adequate technique is still discussed (3).

The aim of the present study is to analyze characteristics, clinical evolution and surgical techniques of 12 patients with OAC treated in our hospital.

Patients and Method

The data corresponding to OAC between 1996-2007 in the Oral and Maxillofacial Surgery Unit of the University Central Hospital (Oviedo), a tertiary health care hospital for 1.110.000 inhabitants were documented. Twelve patients surgically treated under general anaesthesia for OACs were selected for this study. The data recorded for each patient included age, sex, medical history, OAC size, sinus disease, surgical technique, time of hospitalization and postsurgical evolution. Follow-up was performed at fifteen days, one month and four months after treatment.

Acute sinus disease was treated with amoxicillin/clavulanate 1g/125mg x 3/d for 10-14 days, nasal decongestants and NSAID. Chronic sinus disease underwent endoscopic sinus surgery (ESS) or Cadwell-Luc procedure.

Results

Among the 12 patients of 15 with OACs that followed established protocol, 7 were male and 5 were female. The age range of the patients was 32-80 years (mean 47.5). The most frequent cause of OAC was extraction of upper first molar (6/12), with no differences between maxillary sides. Extraction of upper second molar caused OAC in two patients (2/12), both of them in right side. Surgical extraction of impacted left third molar, simple extraction of first left premolar and maxillary cyst excision caused remaining cases (3/12). Cyst dimension was 2x2.5 cm and was a periapical lesion of left second premolar. No etiologic factors were found in one case (1/12).

Nine patients referred liquid released by the nostrils. Three of them had a purulent yellow-to-green discharge from the fistula.

The size of the OACs ranged from 0.4 to 1.5 cm, and was larger than 3 mm in all patients (Fig. 1). Sinus disease was observed in 6 patients. Acute sinus disease was treated with antibiotics and symptomatic relief. Chronic sinus disease (5/6) underwent Cadwell-Luc procedure (3/5) and ESS (2/5).

Surgical techniques used to communication closure were buccal flap (7/12), palatal rotation-advancement flap (4/12) and buccal fat pad. Rehrmann's buccal advancement flap with periosteal incisions to increase flap coverage was performed in 7 patients. Posteriorly based palatal rotation-advancement flap were used in 4 patients (Fig. 2). Epithelialization of the palatal bone donor site was completed after 4 weeks. The flap was stitched in place with simple interrupted sutures (Ethicon 4/0, Johnson & Johnson (Co)). We conducted invagination of fistulous tract to create two layers between oral and sinus mucosa.

Buccal fat pad was used to close large defect at maxillary tuberosity (1.5cm), after extraction of upper left third molar (Fig. 3). It was accessible through a horizon-

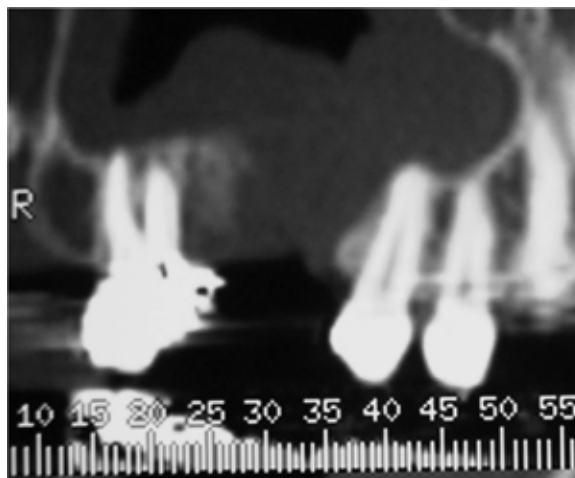


Fig. 1. Computed tomography image revealing an OAC of 8 mm size with chronic sinusitis (case 2).

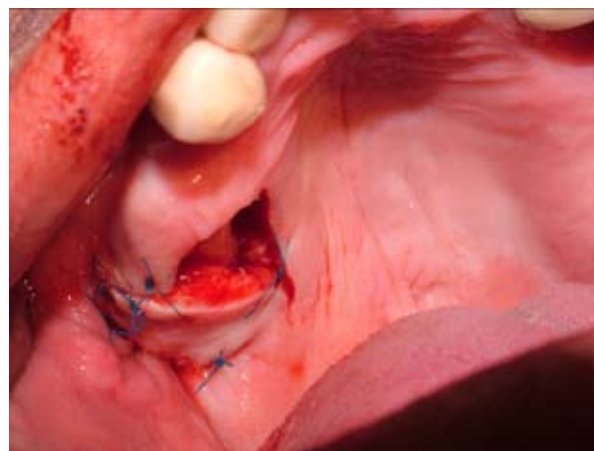

Fig. 2. Posteriorly based palatal rotation-advancement flap (case 4).

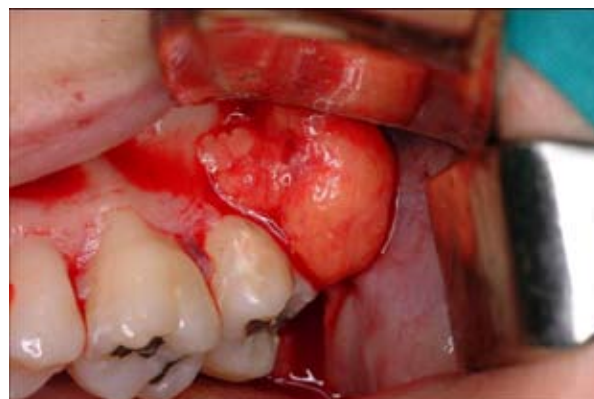

Fig. 3. Buccal fat pad was used to close a large defect (15 mm) in the tuberosity area (case 10).

Table 1. Data of 12 patients including surgical technique and results.

	Sex	Age	Etiology	Fistula size (cm)	Sinus disease	Surgical technique	Time of Hospitalization (days)	Follow-up
1	F	53	Extraction 17#	0.8	Chronic	Buccal+ESS	7	NR
2	F	45	Extraction 16#	0.8	Chronic	RAP+ESS	4	NR
3	M	32	Extraction 26#	0.4	Chronic	Buccal+ESS	3	NR
4	M	80	None	0.7	Chronic	RAP+C-L	6	Dehiscence No surgery required
5	M	57	Extraction 26#	1.1		Buccal	3	Recurrence
6	M	49	Extraction 24#	1		Buccal	3	Recurrence
7	M	35	Extraction 16#	0.9		RAP	3	NR
8	M	57	Maxillary cyst	1.2		Buccal	2	Recurrence
9	M	35	Extraction 17#	0.6	Acute	Buccal	3	NR
10	F	49	Extraction 28#	1.5	Acute	BFP+C-L	3	NR
11	F	37	Extraction 26#	0.5		Buccal	3	NR
12	F	41	Extraction 16#	0.6		RAP	3	NR

ESS: Endoscopic sinus surgery; RAP: Rotation-advancement palatal; C-L: Cadwell-Luc procedure; BFP: Buccal fat pad; NR: No recurrences

tal incision posterior to the zygomatic buttress and can be tunnelled under the mucosa to cover the defect. Flap was sutured without tension with silk suture.

All of these techniques were preceded by removal of fistulous tissue and soft diet was also advisable until tissue healing had taken place. Average time hospitalization was 3.75 days (range: 2-7). Only one dehiscence was observed in patient who underwent palatal flap and no surgery was necessary for closing.

Three OAC were unsuccessfully treated because of suture dehiscence and recurred before fifteen days after surgery. All of them underwent buccal flap procedure. No one had concomitant sinus disease. Average fistula size was 1.1 cm (range: 1-1.2). It was larger than average fistula size of no recurred OAF (0.74; range: 0.4-1.5) and there were no symptoms were reported. Recurrences were diagnosed by persistence of communication between sinus and oral cavity. Two recurrences had spontaneously closed after one month follow-up. One recurrence healed after four months of conservative treatment (Table 1).

Discussion

OAC is a rare complication of oral surgery. Punwutikorn et al. (9) reported 87 OACs overall 27.984 teeth extractions (0.31%). However, Hirata et al. (11) observed rates of 5%. Four upper last maxillary teeth are the main cause of OAC but the tooth most often related varies depending on sample consulted (1-4, 11). Upper first molar was the most important cause in our sample. The difference between maxillary sides was not statistically significant (9).

The maxillary sinus reaches its greatest size during the third decade of life consequently, the incidence of OAC should be higher after that age (4,9). Average age of patients in our sample was 47.5. Fistula size less than 3 mm can spontaneously close (3). The most common cause of failure is insufficient control of maxillary sinusitis. For this reason, foreign bodies, infected and degenerated polypoid mucosa and infected bone should be immediately removed. Functional ESS and Cadwell-Luc procedure are the most important surgical techniques used. ESS is a reliable method associated with less morbidity and lower incidence of complications than Cadwell-Luc technique (12).

Many techniques have been described to close oroantral fistulas. Local flaps are the preferred technique by surgeons, without specifying type. In our opinion, location and fistula size are important factors for technical choice.

Rerhmann technique was the most used in our sample and was related with all of the surgical failures. Buccal flaps are preferable for closure of small (less than 3 mm) and immediate OAC. Coverage of flap improves by horizontal periosteal incisions (6). The flap may also result in a very shallow vestibular sulcus, which can interfere with prosthodontic rehabilitation and maintenance of oral hygiene. Although lauded for their ease of performance and good blood supply, buccal flaps require careful manipulation (4, 11-13).

Palatal rotation-advancement flap was successfully used in 4 patients. Although one dehiscence was observed in old male patient, no second surgical procedure was necessary. All palatal flaps are based on the greater

palatine artery, and its integrity has been considered an important success factor. In anteriorly based palatal flaps, terminal part of the greater palatine artery is its nasopalatine branch, which ascends up through the incisive foramen into the nose where it anastomoses with the septal branches of the sphenopalatine artery. This establishes the basis for retrograde flow through the nasopalatine artery when the greater palatine neurovascular bundle is transacted (12). An appropriate length/width ratio is important for the success rate of random flaps. No flap necrosis is found when the ratio is below 2.15 and significant edge necrosis and repair failure is always noted in cases with a ratio above 2.49 (14). Donor site of palatal flap is completely healed 2 months post-operatively and it is not necessary to use grafts (14). Blood supply of palatal flap is better than buccal flap and it is preferred in large and recurrent oroantral fistulas (2).

Buccal fat pad was used in only one patient. This flap and palatal flap have been reported with good results (8, 14-16). Buccal fat pad is a mass of adipose tissue that extends posteriorly for 2 cm through the mucosa and fibres of buccinator muscle. It consists of a main body and four extensions, the buccal, the pterygoid, and the superficial and the deep temporal extensions. We use buccal extension to cover palatal defects. It lies above the parotid duct to the anterior border of the masseter muscle and extends deeply to lie on the posterior maxilla and forward along the buccal vestibule. The blood supply is from the buccal and deep temporal branches of the maxillary artery, the superficial temporal artery (transverse facial artery) and a small branch of the facial artery. This flap proved to be consistently successful in closing oroantral fistulae and preserving the normal anatomical architecture of the oral mucosa, as there was no loss of vestibular depth, as in the case of using buccal flaps. No grafts are necessary and epithelization is completed at one month post-operatively. Because of ease of access and the rich blood supply, the use of buccal fat pad is considered a reliable method for closure OAC, although palatal flap have been considered the best technique by some authors (3). The buccal fat pad is a feasible option for the repair of large defects in the tuberosity area and defects after tumoral excision (3, 14-16).

Other surgical techniques used are lingual flaps (17), temporal muscle flap (18) and bone grafts (19). Used of aluminum plate as a protective barrier in facilitating resolution of OAC. Steiner et al. (21) summarized the advantages of using this surgical procedure for closure of an OAC: simplicity of surgery, minimal postsurgical scarring revision procedures unnecessary, lack of postsurgical obliteration of the mucobuccal fold, elimination (in contrast to several buccal flap procedures), elimination of palatal defects, elimination of palatal pedicle procedure and elimination of the need for a preventive

stent. This surgical technique is also cheaper than its predecessor, golden plates.

Although many authors relate success rates nearly 100%, OAC is a rare and difficult to close disease (21,22). We must inform patients of possibility failure and need for re-operation.

Conclusions

OACs requiring surgical treatment are rare complications of oral surgery. The treatment should be individualized and carefully planned to avoid failures. An informed consent describing recurrence possibilities is essential previous surgery. In our study, all recurrences underwent buccal flap procedure, but all recurrences spontaneously closed between one and four months after.

References

- Güven O. A clinical study on oroantral fistulae. *J Craniomaxillofac Surg.* 1998;26:267-71.
- Yilmaz T, Suslu AE, Gursel B. Treatment of oroantral fistula: experience with 27 cases. *Am J Otolaryngol.* 2003;24:221-3.
- Abuabara A, Cortez AL, Passeri LA, de Moraes M, Moreira RW. Evaluation of different treatments for oroantral/oronasal communications: experience of 112 cases. *Int J Oral Maxillofac Surg.* 2006;35:155-8.
- Anavi Y, Gal G, Silfen R, Calderon S. Palatal rotation-advancement flap for delayed repair of oroantral fistula: a retrospective evaluation of 63 cases. *Oral Surg Oral Med Oral Pathol Oral Radiol Endod.* 2003;96:527-34.
- Lin PT, Bukachevsky R, Blake M. Management of odontogenic sinusitis with persistent oro-antral fistula. *Ear Nose Throat J.* 1991;70:488-90.
- Rehrmann A. A method of closure of oroantral perforation. *Dtsch Zahnärztl Z.* 1936;39:1136-9.
- Anderson MF. Surgical closure of oroantral fistula: report of a series. *J Oral Surg.* 1969;27:862-3.
- Môczair L. A new surgical method of closure of oroantral fistula of odontogenic origin. *Stomatol (Roma).* 1930;28:1087-8.
- Egyedi P. Utilization of the buccal fat pad for closure of oro-antral and/or oro-nasal communications. *J Maxillofac Surg.* 1977;5:241-4.
- Punwutikorn J, Waikakul A, Pairuchvej V. Clinically significant oroantral communications--a study of incidence and site. *Int J Oral Maxillofac Surg.* 1994;23:19-21.
- Hirata Y, Kino K, Nagaoka S, Miyamoto R, Yoshimasu H, Amagasa T. [A clinical investigation of oro-maxillary sinus-perforation due to tooth extraction]. *Kokubyo Gakkai Zasshi.* 2001;68:249-53.
- Lee JJ, Kok SH, Chang HH, Yang PJ, Hahn LJ, Kuo YS. Repair of oroantral communications in the third molar region by random palatal flap. *Int J Oral Maxillofac Surg.* 2002;31:677-80.
- Costa F, Emanuelli E, Robiony M, Zerman N, Polini F, Politi M. Endoscopic surgical treatment of chronic maxillary sinusitis of dental origin. *J Oral Maxillofac Surg.* 2007;65:223-8.
- Salins PC, Kishore SK. Anteriorly based palatal flap for closure of large oroantral fistula. *Oral Surg Oral Med Oral Pathol Oral Radiol Endod.* 1996;82:253-6.
- El-Hakim IE, El-Fakharany AM. The use of the pedicled buccal fat pad (BFP) and palatal rotating flaps in closure of oroantral communication and palatal defects. *J Laryngol Otol.* 1999;113:834-8.
- Martín-Granizo R, Naval L, Costas A, Goizueta C, Rodríguez F, Monje F, et al. Use of buccal fat pad to repair intraoral defects: review of 30 cases. *Br J Oral Maxillofac Surg.* 1997;35:81-4.
- Baumann A, Ewers R. Application of the buccal fat pad in oral reconstruction. *J Oral Maxillofac Surg.* 2000;58:389-92.

18. Al-Qattan MM. A modified technique of using the tongue tip for closure of large anterior palatal fistula. *Ann Plast Surg.* 2001;47:458-60.
19. Van der Wal KG, Mulder JW. The temporal muscle flap for closure of large palatal defects in CLP patients. *Int J Oral Maxillofac Surg.* 1992;21:3-5.
20. Whitney JH, Hammer WB, Elliott MD, Tucker DF. The use of cancellous bone for closure of oroantral and oronasal defects. *J Oral Surg.* 1980;38:679-81.
21. Steiner M, Gould AR, Madion DC, Abraham MS, Loeser JG. Metal plates and foils for closure of oroantral fistulae. *J Oral Maxillofac Surg.* 2008;66:1551-5.
22. Del Rey-Santamaría M, Valmaseda Castellón E, Berini Aytés L, Gay Escoda C. Incidence of oral sinus communications in 389 upper thirmolar extraction. *Med Oral Patol Oral Cir Bucal.* 2006;11:E334-8.