

Ancient schwannoma arising from mental nerve. A case report and review

Krishnaraj Subhashraj¹, Subramanian Balanand², Subhashraj Pajaniammalle³

(1) Senior Resident. Department of Oral and Maxillofacial Surgery, Jawaharlal Institute of Postgraduate Medical Education and Research (JIPMER), Pondicherry, India

(2) Dental Surgeon. Department of Oral and Maxillofacial Surgery, Jawaharlal Institute of Postgraduate Medical Education and Research (JIPMER), Pondicherry, India

(3) Dental Surgeon. Surya Dental Care, Pondicherry, India

Correspondence:

Dr. K. Subhashraj

10, 8th cross,

Brindavan,

Pondicherry 605 013

India.

rajsubhash@rediffmail.com

Received: 31/03/2008

Accepted: 16/10/2008

Subhashraj K, Balanand S, Pajaniammalle S. Ancient schwannoma arising from mental nerve. A case report and review. Med Oral Patol Oral Cir Bucal. 2009 Jan 1;14 (1):E12-4.

© Medicina Oral S. L. C.I.F. B 96689336 - ISSN 1698-6946

http://www.medicinaoral.com/medoralfree01/v14i1/medoralv14i1p12.pdf

Indexed in:

- Science Citation Index Expanded
- Journal Citation Reports
- Index Medicus, MEDLINE, PubMed
- Excerpta Medica, Embase, SCOPUS.
- Indice Médico Español

Abstract

Schwannoma is an intraoral rare, benign neoplasm derived from the nerve sheath of peripheral nerves. "Ancient schwannoma" shows histopathological features, such as degenerative changes and atypical nuclei, and may easily be confused with malignant neoplasms. Ancient schwannoma of the head and neck region is relatively uncommon and very few cases had been reported in the oral cavity. We present a case of ancient schwannoma arising from the mental nerve in a 19 year old male which was of eight months duration. Examination revealed a 30 x 25 mm firm, strawberry-like mass in the periapical region of the left lower first premolar, extending anteriorly to the canine and posteriorly to the first molar, obliterating the buccal vestibule, with an intact overlying mucosa. Ultrasonography showed that the tumor was closely associated with the mental nerve on the left side, suggestive of a peripheral neural sheath tumor. Complete excision of the lesion was done under local anesthesia, preserving the mental nerve. The histological picture was strongly suggestive of ancient schwannoma (Antoni A type). There was no evidence of recurrence 18 months after excision. The clinicopathological aspects of this special case are discussed, and the literature regarding this entity is reviewed.

Key words: Ancient schwannoma, oral cavity, mental nerve.

Introduction

Schwannoma is usually a solitary soft tissue or intra bony lesion which is slow growing, encapsulated and is often associated with the associated nerve attached peripherally. Intraoral schwannoma can arise both in soft tissue or bone. Those in soft tissue appear as a smooth submucosal swelling, thus resembling other lesions like mucocele, fibro epithelial polyp, fibroma, lipoma and benign salivary gland tumors (1).

Ackerman and Taylor found that the schwannoma presented with clear areas of hypocellular tissues and attributed the changes to the long standing degenerative changes (2). They

coined the term "ancient" schwannoma for such type of benign neurogenic tumor. However, only few cases of ancient schwannoma occurring in the oral cavity have been reported in the English literature.

Case Report

A 19-year-old male patient was referred to our department by a private practitioner for evaluation and treatment of an asymptomatic enlarging mass of eight months duration in the left cheek. The patient's medical and family history was non contributory.

Extraoral examination revealed a 30 x 25 mm firm, strawbe-

ry-like mass in his left mandibular body region. Intraorally, the swelling was seen in the periapical region of the left lower first premolar, extending anteriorly to the canine and posteriorly to the first molar, obliterating the buccal vestibule (Fig. 1). The overlying mucosa was intact and was normal in color. The swelling was firm in consistency, freely mobile and was not tender. There was neither a carious tooth nor any sharp cusp margins. No neurological abnormality was noted. All the teeth responded positively to pulp testing. Orthopantomograph failed to disclose any abnormalities.

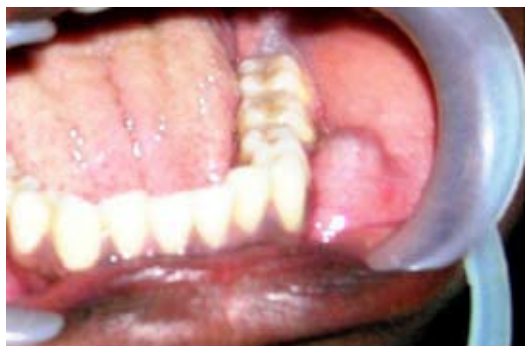

Fig. 1. Intraoral view showing the tumor in left mental foramen region with intact oral mucosa.

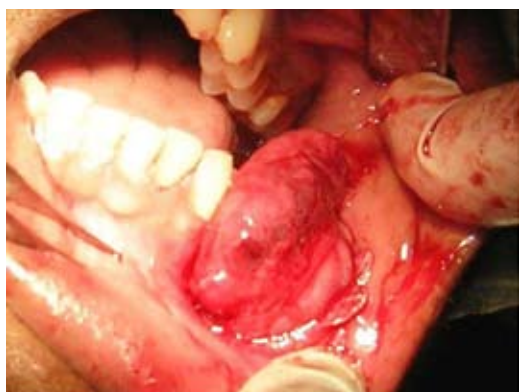

Fig. 2. Intra-operative photograph showing an encapsulated mass attached to the mental nerve.

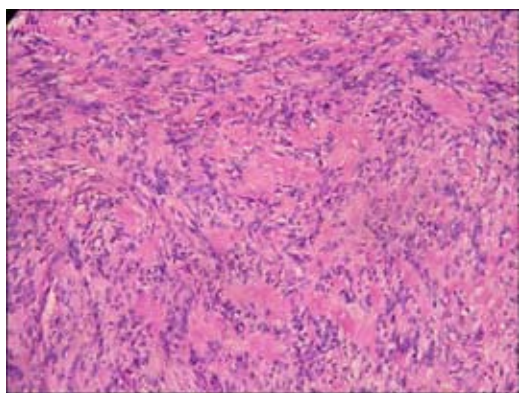


Fig. 3. Hematoxylin and eosin staining of the specimen showing tumor cells composed of proliferating groups of Schwann cell nuclei in Antoni A tissue forming Verocay bodies. Degenerative changes and hyalinization are also seen.

Ultrasonography revealed a hypoechoic mass measuring 31 x 24 x 12 mm that was seen adjacent to the left mandible. There was a clear border between the surrounding soft tissue and the bone. A funicular structure adjacent to the mass suggested a connection between the mental nerve and the lesion. Aspiration was attempted; but the lesion was found to be solid.

The patient underwent surgical excision of the mass under local anesthesia. Using a high labial incision in left mandibular region, the tumor was exposed (Fig. 2). The mass was found to be encapsulated and attached to the axonal portion of the mental nerve at the origin from the mental foramen. The lesion was separated from the adjacent tissues by careful blunt dissection. Complete removal was accomplished by transecting the attachment to the axon, leaving the nerve trunk intact. The surface of the bone was smooth, with no evidence of compressive resorption.

There was transient neurapraxia for about four weeks, after which there was complete recovery of sensation. The patient was followed up for 18 months without any evidence of recurrence.

- Pathology -Gross features:

The excised specimen was 30 x 20 x 15 mm portion of soft tissue, with a well-formed capsule. It was oval, nodular and firm in consistency showing red and yellow areas internally.

- Histological finding:

The tumor showed proliferation of spindle-shaped cells without atypia, which were arranged in a nuclear palisaded appearance (Fig. 3). Reticulin fibers were found abundantly. Degenerative changes and hyalinization were also seen. With all these features, a diagnosis of ancient schwannoma (Antoni type A) was made.

Discussion

Schwannoma (Neurilemmoma) is an infrequent, benign, encapsulated tumor which arises from the nerve sheath cells. Approximately 25% of the reported cases originate from the head and neck region (3). Ancient schwannoma arises rarely in head and neck region and only few cases have been reported in the oral cavity. In our case the tumor was closely associated with the mental nerve.

Oral schwannomas are found to exhibit two types (1). The common type is the submucosal module, which is encapsulated, well-defined, firm in consistency, thus resembling a cyst. The second type is the non-encapsulated, where the tumor is found below the basal layer of mucous membrane.

Reviewing the literature, only seven cases of ancient schwannoma had been reported (Table 1) (4-10). The most common site of occurrence in the oral cavity is the anterior portion of tongue. Reports show that the palate, buccal mucosa and floor of the mouth were also involved. Literature shows that there were two cases reported in the maxillary vestibule region, two cases in floor of the mouth and three cases involving the tongue and floor of the mouth. Among the published series, six cases of ancient schwannoma were seen in females. The

Table 1. Comparison of reported cases of ancient schwannoma of oral cavity and the present case.

Authors	Year	Age	Sex	Location	Size (mm)	Duration
Eversole & Howell ⁵	1971	58	F	Floor of mouth and ventral tongue	25	Not known
Marks et al ⁶	1976	65	F	Floor of mouth (right)	35	Not known
McCoy et al ⁷	1983	36	F	Maxillary posterior vestibule (left)	20	Not known
Dayan et al ⁴	1989	52	F	Maxillary vestibule (left)	9	Not known
Nakayama et al ⁹	1996	40	F	Floor of mouth and ventral tongue	55	2 months
Ledesma et al ¹⁰	1999	21	F	Floor of mouth and ventral tongue	30	5 months
Chen et al ⁸	2006	34	M	Floor of mouth (left)	30	18 years
Present study	2008	18	M	Mandibular posterior vestibule (left)	31	8 months

mean age range was found to be 44 years (between 21 and 65 years). The common coincidences for this tumor among the cases seen in the literature were the location at floor of the mouth, mean age of 44 years and female sex (4-11).

Recurrence and malignant transformation were not reported in any of the reported intraoral ancient schwannoma (4-7). The histological picture is dominated by an encapsulated lesion arising from a nerve end composed of an intimate mixture of spindle cells forming highly cellular Antoni A and less cellular, myxoid Antoni B areas. Verocay bodies, which are cellular eosinophilic zones, are frequently seen.

In summary, this could be the first reported case of ancient schwannoma arising from the mental nerve found in a 19 years old male patient which was of 8 months duration.

References

1. Toriumi DM, Atiyah RA, Murad T, Sisson GA Sr. Extracranial neurogenic tumors of the head and neck. *Otolaryngol Clin North Am.* 1986 Aug;19(3):609-17.
2. Ackerman LV, Taylor FH. Neurogenous tumors within the thorax; a clinicopathological evaluation of forty-eight cases. *Cancer.* 1951 Jul;4(4):669-91.
3. Bayindir T, Kalcioğlu MT, Kizilay A, Karadag N, Akarçay M. Ancient schwannoma of the parotid gland: a case report and review of the literature. *J Craniomaxillofac Surg.* 2006 Jan;34(1):38-42.
4. Dayan D, Buchner A, Hirschberg A. Ancient neurilemmoma (Schwannoma) of the oral cavity. *J Craniomaxillofac Surg.* 1989 Aug;17(6):280-2.
5. Eversole LR, Howell RM. Ancient neurilemmoma of the oral cavity. *Oral Surg Oral Med Oral Pathol.* 1971 Sep;32(3):440-3.
6. Marks RK, Carr RF, Kreller AJ 3rd. Ancient neurilemmoma of the floor of the mouth: report of a case. *J Oral Surg.* 1976 Aug;34(8):731-5.
7. McCoy JM, Mincer HH, Turner JE. Intraoral ancient neurilemmoma (ancient schwannoma). Report of a case with histologic and electron microscopic studies. *Oral Surg Oral Med Oral Pathol.* 1983 Aug;56(2):174-84.
8. Chen CY, Wang WC, Chen CH, Chen YK, Lin LM. Ancient schwannoma of the floor of the mouth – A case report and review. *Oral Oncol (EXTRA).* 2006 Sep; 42(8), 281-5.
9. Nakayama H, Gobara R, Shimamoto F, Kajihara H. Ancient schwannoma of the oral floor and ventricular portion of the tongue: a case report and review of the literature. *Jpn J Clin Oncol.* 1996 Jun;26(3):185-8.
10. Ledesma C, Portilla J, Hernandez F, Garcés M, Hernandez JC. Paraglandular ancient schwannoma. *Med Oral.* 1999 Mar;4(2):398-402.
11. De Vicente Rodríguez JC, Junquera Gutiérrez LM, Fresno Forcelledo MF, López Arranz JS. Neck schwannomas. *Med Oral.* 2003 Jan-Feb;8(1):71-6.