

Journal section: Oral Surgery
 Publication Types: Case Reports

Central giant cell lesion of mandible managed by intralesional triamcinolone injections. A report of two cases and literature review

Sujata Mohanty ¹, Aakarsh Jhamb ²

¹ Assoc Prof & head. Deptt of Oral & Maxillofacial Surgery

² Senior Resident. Deptt of Oral & Maxillofacial Surgery
 Maulana Azad Institute of Dental Sciences. New Delhi

Correspondence:
 Dr. Aakarsh Jhamb
 SFS 111, Rajouri Apts.
 Rajouri Garden
 New Delhi 110064
 India
 draakarsh@yahoo.co.in

Mohanty S, Jhamb A. Central giant cell lesion of mandible managed by intralesional triamcinolone injections. A report of two cases and literature review. Med Oral Patol Oral Cir Bucal. 2009 Feb 1;14 (2):E98-102. <http://www.medicinaoral.com/medoralfree01/v14i2/medoralv14i2p98.pdf>

Article Number: 5123658807 <http://www.medicinaoral.com/>
 © Medicina Oral S. L. C.I.F. B 96689336 - pISSN 1698-4447 - eISSN: 1698-6946
 eMail: medicina@medicinaoral.com

Indexed in:
 -SCI EXPANDED
 -JOURNAL CITATION REPORTS
 -Index Medicus / MEDLINE / PubMed
 -EMBASE, Excerpta Medica
 -SCOPUS
 -Indice Médico Español

Received: 18/04/2008
 Accepted: 16/10/2008

Abstract

Central giant cell lesion (CGCL) is a benign lesion which has unpredictable biologic behaviour and is amenable to a plethora of treatment alternatives. We describe our experience in managing this lesion by intralesional triamcinolone.

The mainstay of treatment of CGCL in our centre until now has been surgical curettage or resection. We chose two patients for this pilot endeavour at our hands. Case I is a 10 year old girl having CGCL of left side mandible. Case II is a 20 yr old man with CGCL affecting the left side posterior mandible. Both patients responded well to intralesional administration of triamcinolone acetonide (Kenacort-10®) with no obvious recurrences to date. Successful application of this conservative drug therapy for managing CGCL can not only save the patient from a mutilating procedure but also has significant financial implications. The amount of triamcinolone injected ranged from 85mg to 180mg by 5-6 injections at weekly intervals.

Key words: Central giant cell lesion, intralesional triamcinolone, nonsurgical management, mandibular pathology.

Introduction

Successful nonsurgical management of a pathology which clamors for surgical intervention at first impression is a "cause celebre" for all concerned. Central giant cell lesion (CGCL) is a benign lesion which has variable and unpredictable biologic behaviour and is amenable to a plethora of treatment alternatives, both surgical as well as conservative (1, 2). Although the surgical alternative eliminates the pathology almost instantaneously one must look upon the other perspective of its consequent morbidity. In conservative management various agents have been used with variable response like intralesional

steroids (3-11), systemic calcitonin (12-16) (intralesional, subcutaneous) and intralesional interferon- α (17, 18). We present our experience in the management of CGCL by conservative means. The mainstay of treatment of CGCL in our centre to date has been surgical curettage or resection. Based on the increasing number of case reports in the literature promoting the use of conservative therapy, we decided to employ it in our cases. Two patients were subjected to this pilot endeavor and intralesional steroids were the preferred modality. We used triamcinolone acetonide 10mg/ml and lignocaine 2% with adrenaline 1:200,000 (50:50) at the dose of 1ml of the solution for

every 1cm of radiolucency, as determined on an orthopantomogram (OPG).

Case Reports

Case 1

A 10-year-old girl was referred to our centre in August 2006 with the chief complaint of progressively increasing swelling of left side of lower jaw. The swelling had been present for 6 months and had recently started increasing in size with pain in the affected region. On examination there was a clear asymmetry of anterior mandible and chin region on the left side. There was no paresthesia over the lower lip. No positive history of trauma could be elicited from the patient. Intraorally the swelling had obliterated the lower labial vestibule from midline to the left 1st premolar. On palpation it was firm and tender. The teeth numbers 31, 32 were rotated. Orthopantomograph (OPG) showed a well circumscribed radiolucency from teeth number 42 to 35 (Fig. 1). The borders were corticated and multilocular with 3 areas of increased radiolucency suggestive of bicortical perforation. The lesion measured 3 x 2.5 cm in maximum dimensions on the OPG. Aspiration of the lesion yielded frank blood. Incisional biopsy was performed and the diagnosis was CGCL. Normal Parathormone assay ruled out hyperparathyroidism. Considering the age of the patient, intralesional steroid was the chosen modality. Treatment was started with 4ml mixture of kenacort – 10® (2ml) + lignocaine 2% with adrenaline 1:200,000 (2 ml). After the 2nd injection the lesion started shrinking in size and became painless. Subsequently the amount of solution injected was progressively reduced. By the last injection at 5 weeks, it was difficult to penetrate the labial cortex and extreme pressure was required to administer even 1ml of the mixture. The total dose of triamcinolone administered was 85mg over five weeks in increments of 4 injections of 20mg each followed by the last injection of approximately 5mg. OPG taken 1 week after the last injection showed increasing radiopacity in the lesion. By the next month opacity was evident in the centre of the lesion with minimal radiolucency at the periphery. OPG taken 3 months after the last injection showed blurring of the lesion margins with new bone formation. At 6 months the bony architecture was near normal and only minimal radiolucency was present around the root apices of the involved teeth. Eighteen months after the last injection there was no sign indicative of any previous lesion in symmetrical, normal growing mandible with normal teeth alignment (Fig. 2).

Case 2

A 20-year-old male reported to our centre in December 2006 with the chief complaint of swelling on the left side of face at the angle ramus region. The swelling was noted about 4 months previously and was slowly increasing in

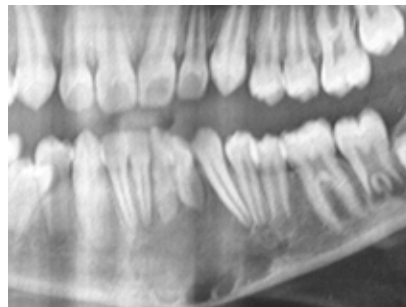


Fig 1a. OPG showing radiolucent lesion extending from midline to teeth number 35 with displacement of teeth (case 1).

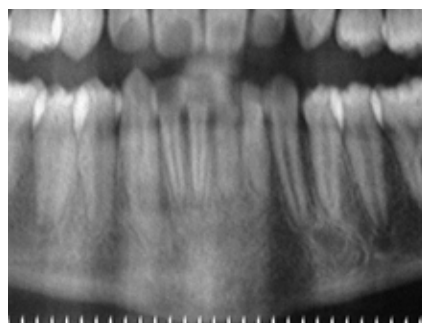


Fig 1b. Post injection OPG (18 months) showing normal bony trabecular pattern and well aligned teeth at the previous lesion site (case 1).

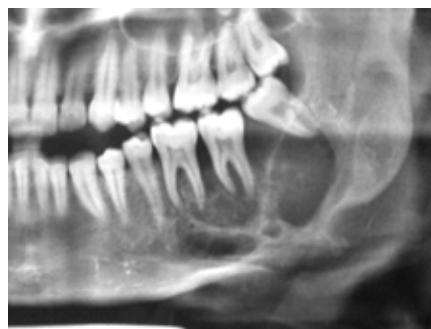

Fig 2a. OPG showing radiolucency in relation to teeth number 35 to distal of teeth number 38 and destruction of alveolus and inferior border of mandible (case 2).

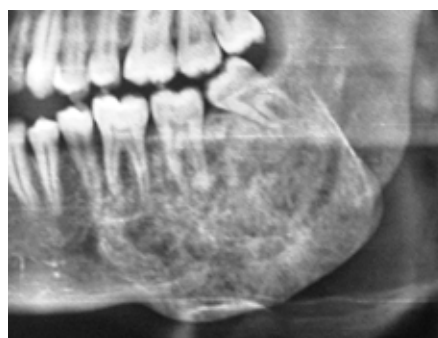

Fig 2b. Post injection OPG (13 months) showing complete radioopacity at the lesion site (case 2).

size. No history of trauma or clinical features pertaining to hyperparathyroidism was noted. The swelling was located on the left body and ramus region of mandible with expansion of the involved inferior and posterior border. The swelling was hard all over except at its superior limits in the vicinity of the alveolus. There was no paresthesia in the region and mouth opening was normal. OPG showed a mixed lesion extending from distal of 35 to 38. The alveolus around 37 was resorbed. There were septae present inside the lesion dividing it into 3 compartments (Fig. 3). The inferior border of mandible was expanded and destroyed and the lesion measured 5 x 4 cm on the OPG. On aspiration the lesion yielded frank blood. Incisional biopsy performed under local anaesthesia showed histopathological picture consistent with CGCL. Intralesional triamcinolone acetonide (10mg/ml) was injected in similar manner using the same protocol. Injection was started with 6 ml mixture and total six such injections were given at weekly intervals. OPG taken after six weeks showed increasing radio opacity within the lesion and so further injections were stopped. Radiographs taken at 3 monthly intervals displayed progressively increasing trabeculations. Ten months after the last injection this patient complained of tenderness at one point which was observed to be a radiolucent area (1x 2 cm) on OPG. It was decided to administer the mixture to the specific site as it was easily localizable and accessible. 2ml of the same mixture was injected thrice at weekly intervals. Three months later (total 13 months after initiation of therapy) the lesion was completely radio opaque and the patient was entirely symptom free (Fig. 4). The total dose of triamcinolone administered was 180mg during the initial session of 6 weeks followed by 30mg in second session over 3 weeks. The residual bulge at the inferior border can be surgically recontoured although the patient is unwilling at present.

Discussion

Central giant cell lesion usually presents as a painless, slow growing swelling of the jaw. Displacement of teeth occurs frequently and can lead to malocclusion (19). Radiological findings are diverse ranging from small unilocular lesions to large multilocular lesions with well defined or ill defined borders (20). Also seen are displacement of teeth and tooth germs, root resorption and cortical perforation (19). Presence of a wispy opacification within the lesion is the most significant radiographic sign associated with CGCL (21). Choung et al. (22) differentiated between aggressive and non aggressive lesions on the basis of signs and symptoms and histological features. Aggressive lesions are characterized by one or more of the following features: large size (> 5 cm), pain, paresthesia, root resorption, rapid growth, cortical perforation and a high recurrence rate after surgical curettage. The non aggressive form is characterized by a slow, almost asymp-

tomatic growth that does not perforate the cortical bone or induce root resorption and has low recurrence rate. Both the patients reported by us can be categorized as non aggressive forms. CGCL is composed of two distinct populations of cells viz. multinucleated giant cells and spindle shaped stromal cells. The latter are thought to be proliferating tumor cells based on available evidence (23, 24). These are osteoblast like cells with similar functions. They induce osteoclast formation from mononuclear blood cells via RANK- RANKL interaction. RANKL (receptor activator of nuclear factor kb ligand) present on stromal cells influences the differentiation of giant cells from RANK expressing mononuclear cells (25). Both steroids as well as calcitonin affect the giant cells rather than the prime neoplastic cells i.e. the stromal cells. Dexamethasone inhibits lacunar resorption by mature osteoclasts isolated from giant cell tumor of the bone by probably inhibiting the extracellular production of bone resorption mediating lysosomal proteases and by inducing apoptosis of osteoclastic cells (26-29). Recently, glucocorticoid receptors and calcitonin receptors have been identified on both the mononuclear spindle shaped cells as well as the multinucleated giant cells (2,30 – 33). These receptors may govern the choice of nonsurgical therapy i.e. steroids or calcitonin or both. Surgery is always left as a salvage option in nonresponsive or recurrent lesions.

On reviewing the literature we have found a total of 15 cases reported which were treated by intralesional corticosteroid with variable response (Table I). Majority of cases were given 6 injections but the range was 4 – 20 injections. Out of the total 15 cases only 3 required surgical interventions for residual radiolucency. Majority of authors observe a protocol of giving 6 injections and following up the patients with periodic radiographic examination and intervening only if symptomatic radiolucency is observed. Most of the authors have used triamcinolone acetonide as 50% mixture with local anaesthesia with adrenaline. However, no reason for this choice has been mentioned by any author. Triamcinolone is a 9 α derivative of prednisolone with highly selective glucocorticoid activity without significant mineralocorticoid action. It is short acting with plasma half life of 200min and biological half life of 18 – 36 hours. Although its absorption from the site of deposition is minimal resulting in negligible systemic side effects if at all. Even then prior to this therapy, the occurrence of systemic contraindication to steroid administration like diabetes, peptic ulcer, known allergy to steroids and more so the presence of local infection should be ruled out (3,5,8,10). The astute operator will become aware of a responsive lesion with each passing week by looking for the following (3):

1. Increasing difficulty in penetration of needle into the lesion.

Table I. Reported cases managed by intralesional steroid injection.

Year	Author	No. of cases	Site	Size	No. of injections	Result
1994	Terry & Jacoway ⁽³⁾	4	Right Mandible	–	6	Complete resolution 3years
			Left Mandible	–	6	Complete resolution 16 months
			Right Anterior Mandible	–	6	Complete resolution 26 months
			Left Posterior mandible	–	6	Incomplete resolution
1994	Kermer et al. ⁽⁴⁾	1	Right Mandible body	3cm	6	Complete resolution 3years
1998	Rajeevan and Soumithran ⁽⁵⁾	1	Midline Mandible	–	6	Resolution
2000	Khafif et al. ⁽⁶⁾	1				Complete resolution 24 months
2001	Kurtz et al. ⁽⁷⁾	1	Midline Mandible	5X3 cm	6 + 6	Recurrence at 1 year followed by Complete resolution 1year
2001	Adornato and Kenneth ⁽⁸⁾	1	Left Mandible	3 X 3cm	6	Partial resolution 7 months
2002	Carlos and Sedano ⁽⁹⁾	4	Right Maxillary tuberosity	4 cm	20	Complete resolution 7 years
			Mandibular body	4 cm	17	Complete resolution 6years
			Midline hard palate	5 cm	4	Residual lesion 15 months
			Left Body of Mandible	–	4	Complete resolution 2years
2005	Sezer et al. ⁽¹⁰⁾	1	Left Body of Mandible	3.5 X 2 cm	6	Complete resolution 3years
2005	Abdo et al. ⁽¹¹⁾	1	Left Parasymphysis	–	3	Complete resolution 18 months

2. Back pressure felt while injecting, resulting in lesser amount of solution injected in the later stages.

3. Decreased swelling and pain.

4. The radiographs will show enhancing radioopacity within the lesion.

We opted for steroids as the modality for our patients because of the following advantages:

1. Ease of administration and less invasive (7)

2. Relatively short duration of treatment (6 weeks average compared to 3 - 27 months for calcitonin and interferon- α)

3. Relatively higher success rate as compared to calcitonin /interferon- α

4. Cheaper

5. Easily available

6. Minimal systemic side effects

7. No crippling effects on developing dentition as seen in our cases

8. The option to treat surgically or by other alternative conservative treatments in future if necessary (3).

Disadvantages of steroids:

1. Unpredictable response when compared to surgical option as the first choice

2. Failure to target the prime neoplastic cells i.e. spindle shaped stromal cells.

3. Healing occurs by fibrocollagenous tissue formation which later ossifies. This fibrous tissue may misguide the clinician as probable recurrence/ residual lesion (3, 9).

The unpredictable response can be minimized by receptor typing prior to submitting a patient to a particular conservative modality. Despite the failure to target the neoplastic cell clinical response has time and again demonstrated the effectiveness of these therapy options.

Thus successful management of these two patients has illustrated the efficacy of intralesional steroid therapy for the CGCL of the mandible.

References

- Waldron CA. Bone pathology. In: Neville BW, Damm DD, Allen CA, Buoquot JE, editors. *Oral and maxillofacial pathology*. Philadelphia: Saunders; 1995. p. 453-5.
- Vered M, Shohat I, Buchner A, Dayan D, Taicher S. Calcitonin nasal spray for treatment of central giant cell granuloma: clinical, radiological, and histological findings and immunohistochemical expression of calcitonin and glucocorticoid receptors. *Oral Surg Oral Med Oral Pathol Oral Radiol Endod*. 2007;104:226-39.
- Terry BC, Jacoway JR. Management of central giant cell lesions: an alternative to surgical therapy. *Oral Maxillofac Surg Clin N Am* 1994;6:579-601.
- Kermer C, Millesi W, Watzke IM. Local injection of corticosteroids for central giant cell granuloma. A case report. *Int J Oral Maxillofac Surg*. 1994;23:366-8.
- Rajeevan NS, Soumithran CS. Intralesional corticosteroid injection for central giant cell granuloma. A case report. *Int J Oral Maxillofac Surg*. 1998;27:303-4.
- Khafif A, Krempf G, Medina JE. Treatment of giant cell granuloma of the maxilla with intralesional injection of steroids. *Head Neck*. 2000;22:822-5.
- Kurtz M, Mesa M, Alberto P. Treatment of a central giant cell lesion of the mandible with intralesional glucocorticosteroids. *Oral Surg Oral Med Oral Pathol Oral Radiol Endod*. 2001;91:636-7.
- Adornato MC, Patcoff KA. Intralesional corticosteroid injection for treatment of central giant-cell granuloma. *J Am Dent Assoc*. 2001;132:186-90.
- Carlos R, Sedano HO. Intralesional corticosteroids as an alternative treatment for central giant cell granuloma. *Oral Surg Oral Med Oral Pathol Oral Radiol Endod*. 2002;93:161-6.
- Sezer B, Koyuncu B, Gomel M, Günbay T. Intralesional corticosteroid injection for central giant cell granuloma: a case report and review of the literature. *Turk J Pediatr*. 2005;47:75-81.
- Abdo EN, Alves LC, Rodrigues AS, Mesquita RA, Gomez RS. Treatment of a central giant cell granuloma with intralesional corticosteroid. *Br J Oral Maxillofac Surg*. 2005;43:74-6.
- Harris M. Central giant cell granulomas of the jaws regress with calcitonin therapy. *Br J Oral Maxillofac Surg*. 1993;31:89-94.
- De Lange J, Rosenberg AJ, Van den Akker HP, Koole R, Wirts JJ, Van den Berg H. Treatment of central giant cell granuloma of the jaw with calcitonin. *Int J Oral Maxillofac Surg*. 1999;28:372-6.
- Pogrel MA, Regezi JA, Harris ST, Goldring SR. Calcitonin treatment for central giant cell granulomas of the mandible: report of two cases. *J Oral Maxillofac Surg*. 1999;57:848-53.
- Pogrel MA. Calcitonin therapy for central giant cell granuloma. *J Oral Maxillofac Surg*. 2003;61:649-53.
- De Lange J, Van den Akker HP, Veldhuijzen Van Zanten GO, Engelschote HA, Van den Berg H, Klip H. Calcitonin therapy in central giant cell granuloma of the jaw: a randomized double-blind placebo-controlled study. *Int J Oral Maxillofac Surg*. 2006;35:791-5.
- Kaban LB, Troulis MJ, Ebb D, August M, Hornicek FJ, Dodson TB. Antiangiogenic therapy with interferon alpha for giant cell lesions of the jaws. *J Oral Maxillofac Surg*. 2002;60:1103-11.
- Kaban LB, Dodson T, Wilkinson M, Ebb D, August M. Antiangiogenic therapy for the management of aggressive giant cell lesions of the jaws. *J Oral Maxillofac Surg* 2006;64:41-2.
- De Lange J, Van den Akker HP, Van den Berg H. Central giant cell granuloma of the jaw: a review of the literature with emphasis on therapy options. *Oral Surg Oral Med Oral Pathol Oral Radiol Endod*. 2007;104:603-15.
- Cohen MA, Hertzanu Y. Radiologic features, including those seen with computed tomography, of central giant cell granuloma of the jaws. *Oral Surg Oral Med Oral Pathol*. 1988;65:255-61.
- Horner K. Central giant cell granuloma of the jaws: a clinicoradiological study. *Clin Radiol*. 1989;40:622-6.
- Chuong R, Kaban LB, Kozakewich H, Perez-Atayde A. Central giant cell lesions of the jaws: a clinicopathologic study. *J Oral Maxillofac Surg*. 1986;44:708-13.
- Liu B, Yu SF, Li TJ. Multinucleated giant cells in various forms of giant cell containing lesions of the jaws express features of osteoclasts. *J Oral Pathol Med*. 2003;32:367-75.
- Itonaga I, Hussein I, Kudo O, Sabokbar A, Watt-Smith S, Ferguson D, et al. Cellular mechanisms of osteoclast formation and lacunar resorption in giant cell granuloma of the jaw. *J Oral Pathol Med*. 2003;32:224-31.
- Miyamoto N, Higuchi Y, Tajima M, Ito M, Tsurudome M, Nishio M, et al. Spindle-shaped cells derived from giant-cell tumor of bone support differentiation of blood monocytes to osteoclast-like cells. *J Orthop Res*. 2000;18:647-54.
- Hirayama T, Sabokbar A, Athanasou NA. Effect of corticosteroids on human osteoclast formation and activity. *J Endocrinol*. 2002;175:155-63.
- Kremer M, Judd J, Rifkin B, Auszmann J, Oursler MJ. Estrogen modulation of osteoclast lysosomal enzyme secretion. *J Cell Biochem*. 1995;57:271-9.
- Dempster DW, Moonga BS, Stein LS, Horbert WR, Antakly T. Glucocorticoids inhibit bone resorption by isolated rat osteoclasts by enhancing apoptosis. *J Endocrinol*. 1997;154:397-406.
- Kameda T, Mano H, Yuasa T, Mori Y, Miyazawa K, Shiokawa M, et al. Estrogen inhibits bone resorption by directly inducing apoptosis of the bone-resorbing osteoclasts. *J Exp Med*. 1997;186:489-95.
- Vered M, Buchner A, Dayan D. Immunohistochemical expression of glucocorticoid and calcitonin receptors as a tool for selecting therapeutic approach in central giant cell granuloma of the jawbones. *Int J Oral Maxillofac Surg*. 2006;35:756-60.
- Abu EO, Horner A, Kusec V, Triffitt JT, Compston JE. The localization of the functional glucocorticoid receptor alpha in human bone. *J Clin Endocrinol Metab*. 2000;85:883-9.
- Anderson JM. Multinucleated giant cells. *Curr Opin Hematol*. 2000;7:40-7.
- Tobón-Arroyave SI, Franco-González LM, Isaza-Guzmán DM, Floréz-Moreno GA, Bravo-Vásquez T, Castañeda-Peláez DA, et al. Immunohistochemical expression of RANK, GRalpha and CTR in central giant cell granuloma of the jaws. *Oral Oncol*. 2005;41:480-8.