

Journal section: Oral Medicine and Pathology

doi:10.4317/medoral.14.e563

Publication Types: Research

Comparative analysis of cell proliferation ratio in oral lichen planus, epithelial dysplasia and oral squamous cell carcinoma

Fernando-Augusto-Cervantes-Garcia de Sousa ¹, Thais-Cachuté Paradella ¹, Yasmin-Rodarte Carvalho ², Luiz-Eduardo-Blumer Rosa ²

¹ DDS, MSc, PhD, Department of Bioscience and Oral Diagnosis, São José dos Campos Dental School, São Paulo State University, São José dos Campos, SP, Brazil

² DDS, MSc, PhD, Professor, Department of Bioscience and Oral Diagnosis, São José dos Campos Dental School, São Paulo State University, São José dos Campos, SP, Brazil

Correspondence:

Rua Irmã Maria Demétria Kfuri, 196 - 12.242-500
São José dos Campos SP Brazil
facgs@uol.com.br

Sousa FACG, Paradella TC, Carvalho YR, Rosa LEB. Comparative analysis of cell proliferation ratio in oral lichen planus, epithelial dysplasia and oral squamous cell carcinoma. Med Oral Patol Oral Cir Bucal. 2009 Nov 1;14 (11):e563-7.
<http://www.medicinaoral.com/medoralfree01/v14i11/medoralv14i11p563.pdf>

Received: 20/12/2008

Accepted: 18/04/2009

Article Number: 2627 <http://www.medicinaoral.com/>
© Medicina Oral S. L. C.I.F. B 96689336 - pISSN 1698-4447 - eISSN: 1698-6946
eMail: medicina@medicinaoral.com
Indexed in:
-SCI EXPANDED
-JOURNAL CITATION REPORTS
-Index Medicus / MEDLINE / PubMed
-EMBASE, Excerpta Medica
-SCOPUS
-Indice Médico Español

Abstract

Background: Although oral lichen planus has been classified by the World Health Organization (WHO) as a potentially malignant disorder, such classification is still the target of much controversy. **Aim:** To evaluate the cell proliferation rate in oral lichen planus, comparing it to the rate observed in epithelial dysplasia and oral squamous cell carcinoma, aiming at indications which might indicate the potential for malignant transformation. **Material and Methods:** Twenty-four cases of each lesion were submitted to the streptoavidin-biotin and AgNOR technique to evaluate the immunohistochemical expression of PCNA and the mean NORs/nucleus, respectively. **Results:** Positivity for PCNA was observed in 58.33% of oral lichen planus cases, 83.33% of epithelial dysplasia cases and 91.67% of oral squamous cell carcinoma cases. Chi-squared test showed that the number of positive cases for PCNA was significantly lower in oral lichen planus than in oral squamous cell carcinoma ($p < 0.05$). No significant statistical difference between oral lichen planus and epithelial dysplasia ($p > 0.05$) and between the epithelial dysplasia and oral squamous cell carcinoma ($p > 0.05$) was observed. The mean NORs/nucleus in oral lichen planus, epithelial dysplasia and oral squamous cell carcinoma were 1.74 ± 0.32 , 2.42 ± 0.62 e 2.41 ± 0.61 , respectively. Variance analysis (ANOVA) revealed significant statistical difference between oral lichen planus and the other studied lesions ($p < 0.05$). **Conclusion:** Oral lichen planus cell proliferation rate was less than in oral epithelial dysplasia and oral squamous cell carcinoma which might explain the lower malignant transformation rate.

Key words: Oral lichen planus, epithelial dysplasia, oral squamous cell carcinoma, immunohistochemistry, Agnor.

Introduction

The evaluation of the cell proliferation rate brings important information regarding diagnosis and prognosis of several types of cancer. In addition, the enhancement of the proliferation capacity may be one of the first indicators of malignant transformation, since it constitutes a key event for the development of cancer. Among the several techniques used for such evaluation, the immunohistochemistry analysis of proteins expressed during the cell cycle, such as PCNA, and the quantitative analysis of NORs, through the histochemistry of AgNORs, deserves notability due to their easiness in execution, low cost and high trustworthiness.

Describe initially by Myiachi et al. (1), from serum of patients with systemic lupus erythematosus, PCNA (proliferating cell nuclear antigen) is a nuclear acid protein of 36 KDa, which works as an auxiliary protein of delta polymerase, associated to the DNA duplication and repair (2). The concentration of PCNA is variable during the steps of the cell cycle, being higher in late G1 phase, with peaks in G1/S phase, being practically absent in G2 and M phases (3).

The results obtained through the evaluation of the cell proliferation rate using PCNA are comparable to the traditional methods and even superior to methods such as flow cytometry and bromodoxiuridine incorporation. Several studies describe the application of monoclonal antibodies against PCNA, since this is a fine indicator of the biological behavior of some premalignant and malignant lesions (4).

The AgNOR techniques marks the proteins associated to the nucleolar organizer regions (NORs), which were first described by Heintz (1931) and McClintock (1934) (5). NORs are loops of DNA that transcribe for ribosomal RNA. They are located on the short arm of chromosomes 13, 14, 15, 21, and 22. Associated with these regions are certain acidic and argyrophilic, non-histonic proteins called NOR-associated proteins. NORs can be demonstrated in tissue sections by staining their associated proteins with colloidal silver and these silver-stained reaction products represent the argyrophilic nucleolar organizer regions (AgNORs)(6).

According to Derenzini and Trerè (7), the higher the number of NORs, the lower is the duration of the cell cycle and the higher is the velocity of cell proliferation. Such relationship makes the quantitative analysis of NORs an excellent indicator of the proliferation activity of the cells and a valuable diagnostic tool, since it enables the differentiation of benign from malignant cells and even predicts the prognosis of different types of cancer (8).

Therefore, the evaluation of the cell proliferation rate, through the immunohistochemical expression of PCNA and the quantitative analysis of NORs may bring useful information regarding the malignant potential of oral lichen planus. This pathology, although being consid-

ered by the World Health Organization (WHO) as a potentially malignant disorder (9) is still target of much controversy, due to the lack of clear clinical and histopathological criteria for its correct diagnosis (10-12).

According to González-Moles et al. (12), most studies on cell proliferation in oral lichen planus have reported a marked increase in the proliferation rate of basal epithelial cells and some authors have proposed that this might be an important event in the development of cancer in oral lichen planus.

The purpose of the present study is to evaluate the cell proliferation rate in oral lichen planus through the analysis of the expression of PCNA and quantitative analysis of NORs, comparing it with the rate observed in epithelial dysplasia and oral squamous cell carcinoma, aiming at indications which might comprove or not the malignant potential transformation of this disease or at least, help identify the cases which present the higher malignant transformation risk.

Material and Methods

Twenty-four cases of oral lichen planus, 24 cases of epithelial dysplasia (4 mild, 12 moderate, 8 severe) and 24 cases of oral squamous cell carcinoma obtained from the files of the Department of Bioscience and Oral Diagnosis of the São José dos Campos Dental School, São Paulo State University, Brazil were used in the study. Age and gender of patient were not considered because these data are not related to the increase of the risk of malignant transformation of oral lichen planus.

The cases of oral lichen planus were selected according to Eisenberg's criteria (11). Two 3µm histological sections were cut from the paraffin-embedded blocks. One section was stained according to streptoavidin-biotin technique and the other was stained according to Ag-NOR technique.

Immunohistochemical reaction against PCNA (PC10 clone; dilution, 1:300) was performed in 3µm histological sections. The sections were dewaxed in xylene, rehydrated in graded alcohol, and rinsed in water. To inhibit endogenous peroxidase activity, the sections were treated by immersion in two changes of 6% H₂O₂ in absolute methanol (5 min each change) and rinsing in water. For antigen retrieval, the sections were immersed in 10 mM sodium citrate buffer (pH 6.0) and boiled for 15 min in a microwave oven (700 W). After washing with Tris buffer (pH 7.4), the slides were incubated at 4°C for eighteen hours with monoclonal antibodies. After incubation, immunodetection was performed with the LSAB Visualization System (DakoCytomation, Glostrup, Denmark) using 3,3'-diaminobenzidine chromogen as substrate, according to the manufacturer's instructions. Slides were counterstained with Mayer's hematoxylin, dehydrated, and mounted in Permount® (Fisher Scientific, Fair Lawn, USA).

Paraffin-embedded epithelial hyperplasia biopsied cases served as positive controls. For a negative control, the primary antibodies were replaced with the antibody diluent solution.

Regarding PCNA expression, the cases were classified according to the number of positively stained cells per 1.000 counted cells in all epithelium layers (basal, intermediate and superficial layers) as: positive (more than 5% of cells were stained) and negative (less than 5% of cell stained).

The AgNOR technique was adapted from that described by Ploton et al. (13). After dewaxed in xylene, rehydrated in graded alcohol, and rinsed in water, the 3µm histological sections were immersion in acetic acid and 95% alcohol solution (3:1) for 5 min, rinsed three times in absolute alcohol and rinsed six times in water. The sections were reacted with freshly prepared silver colloidal solution (containing one part by volume of 2% gelatin in 1% formic acid and two parts by volume of 50% aqueous silver nitrate solution) in closed recipient for 30 min at 45°C, ensuring a dark environment throughout the reaction time. The silver colloidal solution was washed with water at 45°C. Slides were then dehydrated, and mounted in Permount® (Fisher Scientific, Fair Lawn, USA). The mean number of NORs was obtained by two calibrated examiner through the counting of the number of NORs at least 100 cells, using the 100x oil immersion objective of the light microscope.

The immunohistochemical expression of PCNA was analysis by Chi-squared test, while the mean number of NORs per cell in each lesion was analyzed statistically by analysis of variance (ANOVA) and by Tukey’s Test. Values of $p \leq 0.05$ were considered as statistically significant.

Results

The positivity for PCNA was observed in 58.33% of the oral lichen planus cases, 83.33% of the epithelial dysplasia cases and 91.67% of the oral squamous cell carcinoma. In cases with elevated percentage of positive cells for PCNA (more than 50% of cell stained), the involvement of the all epithelium layers (basal, intermediate and superficial layers) can be observed, independently of the studied lesions (Fig. 1).

Chi-squared test showed that the number of positive cases for PCNA was significantly lower in oral lichen planus than in oral squamous cell carcinoma ($p < 0.05$). No significant statistical difference between oral lichen planus and epithelial dysplasia ($p > 0.05$) and between the epithelial dysplasia and oral squamous cell carcinoma ($p > 0.05$) was observed. The grade of epithelial dysplasia did not influence in the results.

The mean of NORs/nucleus in oral lichen planus, in epithelial dysplasia and oral squamous cell carcinoma were 1.74 ± 0.32 , 2.42 ± 0.62 e 2.41 ± 0.61 . The analysis of variance (ANOVA) revealed significant statistical dif-

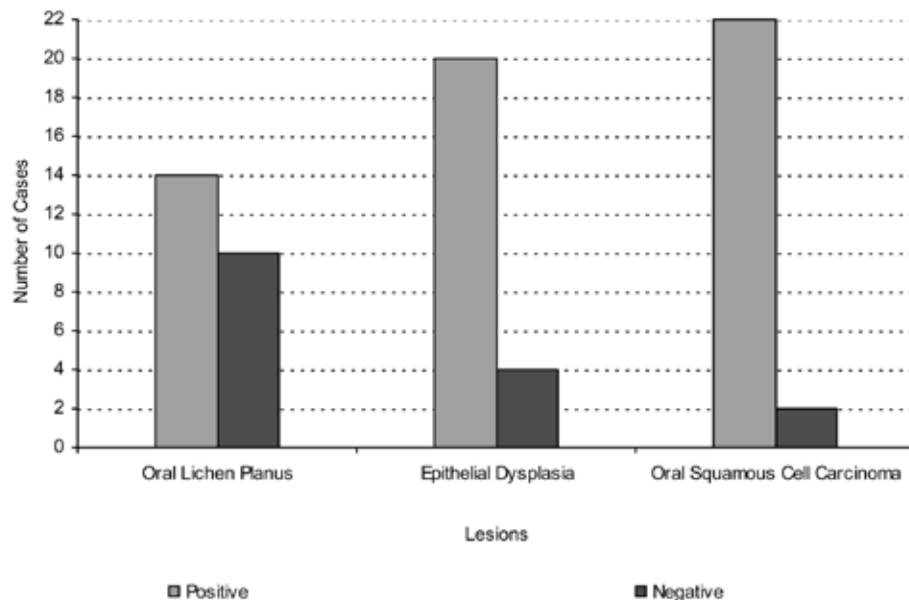


Fig. 1. Comparison of number of positive and negative cases for PCNA in three studied lesions.

ference between oral lichen planus and the other studied lesions ($p < 0.05$). However, there was no significant statistical difference between epithelial dysplasia and oral squamous cell carcinoma ($p > 0.05$).

In oral lichen planus and in epithelial dysplasia, the NORs presented themselves with round and regular contours. However, in oral lichen planus, they exhibit less size variation and greater volume than in epithelial dysplasia. On the other hand, in oral squamous cell carcinoma NORs presented themselves with irregular shape and great size variation.

Discussion

The results obtained from the present study showed that the number of positive case for PCNA in oral lichen planus is lower than in epithelial dysplasia, although had no significant statistical difference between these two lesions, and oral squamous cell carcinoma. This fact suggests that, in general, the cell proliferation rate in oral lichen planus is lower than the other studied lesions. Therefore, oral lichen planus has a lower possibility to accumulate genetic mutations than the epithelial dysplasia and oral squamous cell carcinoma and, consequently, a lower possibility to suffer malignant transformation. This is because the higher the cell proliferation rate, the higher the risk of cells suffering mutations during mitosis, which could result in malignant phenotype. In context, the cases of oral lichen planus with elevated percentage of positive cells for PCNA (more than 50% of cell stained) can have a higher malignant transformation risk. In addition, in these cases, the presence of the positive cell for PCNA in superficial layer of epithelium suggests possible alterations in cell differentiation mechanisms, step essential to the malignant transformation of epithelium.

According to Lee et al. (14), the expression of PCNA in oral lichen planus is similar to hyperkeratosis, but superior to normal mucosa and inferior to epithelial dysplasia and oral squamous cell carcinoma, being in accordance to the results obtained in these studies. However, for Da Silva Fonseca and Do Carmo (15), the higher cell proliferation rate in oral lichen planus than in hyperkeratosis and normal mucosa makes it more susceptible to the action of carcinogens. González-Moles et al. (16) also believe that although oral lichen planus does not present a higher susceptibility to apoptosis in comparison to normal mucosa, interruptions of the cell cycle and enhancement of cell proliferation rate may create a favorable substrate to malignant transformation.

Such findings might explain why the World Health Organization (WHO) although considers the oral lichen planus as a potentially malignant disease, states that its malignant transformation potential is lower than in leukoplakia (with epithelial dysplasia) and erythroplakia (9). However, this position is still target of much con-

trovery, since several authors believe that many of the cases of oral lichen planus with malignant transformation described in the literature are in fact consequences of flaws in the diagnosis of the disease, since, in some cases, subtle dysplastic alterations may have been overlooked in the initial histopathological exam (10-12).

In this case, not only the quantitative but also the qualitative analysis of NORs has shown to be effective in distinguishing oral lichen planus from the other studied lesions. In fact, the mean NORs/nucleus was considerably lower in oral lichen planus than in epithelial dysplasia and in squamous cell carcinoma. In addition, NORs morphology in oral lichen planus and in epithelial dysplasia was significantly different than in oral squamous cell carcinoma, which means that there were significant morphological differences in the potentially malignant diseases regarding oral squamous cell carcinoma, a eminent malignant disease.

According to Xie et al. (17), the quantitative analysis of NORs may help distinguish a normal epithelium from epithelial dysplasia and oral squamous cell carcinoma. In fact, for Ray et al. (18), the quantitative analysis of NORs is a useful tool for the definitive diagnosis of epithelial dysplasia. However, according to Elangovan et al. (2008) (6), the quantitative analysis of NORs is proportional to the cell proliferation rate and not necessarily indicates the malignant transformation potential of a specific lesion, but the morphologic characteristic of NORs may be an important tool in the attempt of differentiating hyperplastic, pre-malignant and malignant lesions.

In summary, the results observed in the present study corroborate Cano Montoya et al. (19). For them, the AgNOR technique may be used as a complement in routine histopathological study, especially in lesions with potential of malignant transformation such as oral lichen planus and epithelial dysplasia, since numerical and morphological variations of NORs may indicate important cellular alterations, minimizing possible diagnostic mistakes. In addition, AgNOR technique is easy and quite economical in comparison to the immunohistochemistry and molecular biology techniques.

Although the obtained results may not confirm the malignant transformation potential of oral lichen planus, the fact that its cell proliferation rate is inferior than epithelial dysplasia's and oral squamous cell carcinoma's might explain why its malignant transformation potential is lower than epithelial dysplasia's. In addition, the quantitative and qualitative analysis of NORs has shown to be useful in distinguishing potentially malignant disorder from oral squamous cell carcinoma per se, assisting the evaluation of oral lichen planus cases that present higher risk of malignant transformation.

References

1. Miyachi K, Fritzler MJ, Tan EM. Autoantibody to a nuclear antigen in proliferating cells. *J Immunol.* 1978;121:2228-34.
2. McCormick D, Hall PA. The complexities of proliferating cell nuclear antigen. *Histopathology.* 1992;21:591-4.
3. Hall PA, Levison DA, Woods AL, Yu CC, Kellock DB, Watkins JA, et al. Proliferating cell nuclear antigen (PCNA) immunolocalization in paraffin sections: an index of cell proliferation with evidence of deregulated expression in some neoplasms. *J Pathol.* 1990;162:285-94.
4. Tsuji T, Mimura Y, Wen S, Li X, Kanekawa A, Sasaki K, et al. The significance of PCNA and p53 protein in some oral tumors. *Int J Oral Maxillofac Surg.* 1995;24:221-5.
5. Derenzini M. The AgNORs. *Micron.* 2000;31:117-20.
6. Elangovan T, Mani NJ, Malathi N. Argyrophilic nucleolar organizer regions in inflammatory, premalignant, and malignant oral lesions: a quantitative and qualitative assessment. *Indian J Dent Res.* 2008;19:141-6.
7. Derenzini M, Trerè D. AgNOR proteins as a parameter of the rapidity of cell proliferation. *Zentralbl Pathol.* 1994;140:7-10.
8. Trerè D, Farabegoli F, Cancellieri A, Ceccarelli C, Eusebi V, Derenzini M. AgNOR area in interphase nuclei of human tumours correlates with the proliferative activity evaluated by bromodeoxyuridine labelling and Ki-67 immunostaining. *J Pathol.* 1991;165:53-9.
9. Van der Waal I. Potentially malignant disorders of the oral and oropharyngeal mucosa; terminology, classification and present concepts of management. *Oral Oncol.* 2009;45:317-23.
10. Van der Meij EH, Schepman KP, Smeele LE, Van der Wal JE, Bezemer PD, Van der Waal I. A review of the recent literature regarding malignant transformation of oral lichen planus. *Oral Surg Oral Med Oral Pathol Oral Radiol Endod.* 1999;88:307-10.
11. Eisenberg E. Oral lichen planus: a benign lesion. *J Oral Maxillofac Surg.* 2000;58:1278-85.
12. Gonzalez-Moles MA, Scully C, Gil-Montoya JA. Oral lichen planus: controversies surrounding malignant transformation. *Oral Dis.* 2008;14:229-43.
13. Ploton D, Menager M, Jeannesson P, Himber G, Pigeon F, Adnet JJ. Improvement in the staining and in the visualization of the argyrophilic proteins of the nucleolar organizer region at the optical level. *Histochem J.* 1986;18:5-14.
14. Lee JJ, Kuo MY, Cheng SJ, Chiang CP, Jeng JH, Chang HH, et al. Higher expressions of p53 and proliferating cell nuclear antigen (PCNA) in atrophic oral lichen planus and patients with areca quid chewing. *Oral Surg Oral Med Oral Pathol Oral Radiol Endod.* 2005;99:471-8.
15. Da Silva Fonseca LM, Do Carmo MA. Identification of the AgNORs, PCNA and ck16 proteins in oral lichen planus lesions. *Oral Dis.* 2001;7:344-8.
16. González-Moles MA, Bascones-Ilundain C, Gil Montoya JA, Ruiz-Avila I, Delgado-Rodríguez M, Bascones-Martínez A. Cell cycle regulating mechanisms in oral lichen planus: molecular bases in epithelium predisposed to malignant transformation. *Arch Oral Biol.* 2006;51:1093-103.
17. Xie X, Clausen OP, Sudbø J, Boysen M. Diagnostic and prognostic value of nucleolar organizer regions in normal epithelium, dysplasia, and squamous cell carcinoma of the oral cavity. *Cancer.* 1997;79:2200-8.
18. Ray JG, Chattopadhyay A, Caplan DJ. Usefulness of AgNOR counts in diagnosing epithelial dysplasia. *J Oral Pathol Med.* 2003;32:71-6.
19. Cano Montoya LC, Alvarez Gómez GJ, Valencia Londoño WA, Ramírez España JA, Prada Navas CA. Analysis of the tissue marker AgNOR in leukoplakia and oral squamous cell carcinoma. *Med Oral.* 2002;7:17-21, 22-5.