

## Reverse smokers's and changes in oral mucosa. Department of Sucre, Colombia

**Gloria J. Alvarez Gómez<sup>1</sup>, Efraín Alvarez Martínez<sup>1</sup>, Raúl Jiménez Gómez<sup>1</sup>, Yolanda Mosquera Silva<sup>1</sup>, Angela María Gaviria Núñez<sup>2</sup>, Adriana Garcés Agudelo<sup>3</sup>, Alexander Alonso Duque<sup>3</sup>, Alexander Zabala Castaño<sup>3</sup>, Elizabeth Echeverri González<sup>4</sup>, Melissa Isaac Millán<sup>4</sup>, Diana Ramírez Ossa<sup>4</sup>**

(1) Professors. Faculty of Dentistry, University of Antioquia, Hospital Universitario San Vicente de Paúl. Oral and Maxillofacial Surgery Service

(2) Professor Mayor College of Antioquia. Group of Infection and Cancer. University of Antioquia

(3) Residents Oral and Maxillofacial Surgery. University of Antioquia

(4) Students of Dentistry. Faculty of Dentistry, University of Antioquia. Medellín, Colombia

### Correspondence:

Dr. Gloria J. Alvarez Gómez

Calle 64 # 52 – 59

Faculty of Dentistry,

University of Antioquia,

Medellín, Colombia

E-mail: gloria@alvarez.nu

Received: 28-01-2007

Accepted: 21-08-2007

Alvarez-Gómez GJ, Alvarez-Martínez E, Jiménez-Gómez R, Mosquera-Silva Y, Gaviria-Núñez AM, Garcés-Agudelo A, Alonso-Duque A, Zabala-Castaño A, Echeverri-González E, Isaac-Millán M, Ramírez-Ossa D. Reverse smokers's and changes in oral mucosa. Department of Sucre, Colombia. Med Oral Patol Oral Cir Bucal. 2008 Jan1;13(1):E1-8.

© Medicina Oral S. L. C.I.F. B 96689336 - ISSN 1698-6946

<http://www.medicinaoral.com/medoralfree01/v13i1/medoralv13i1p1.pdf>

### Indexed in:

-Index Medicus / MEDLINE / PubMed

-EMBASE, Escerpta Medica

-SCOPUS

-Indice Médico Español

-IBECS

### Abstract

**Objectives:** This work is intended to establish the prevalence of reverse smokers at the villages of Hato Nuevo, San Francisco and Cayo de Palma, Department of Sucre, Colombia, characterizing their socio-culture conditions, clinical and histological changes in the oral mucosa. **Design of study:** A descriptive study was done through a home to home inquiry to select the people with inclusion criteria for a posterior clinical test and a biopsy of the affected oral mucosa. **Results and conclusions:** Reverse smokers's prevalence was from the 15%, mainly women ( $p < 0.001$ ) with an age average of 59.3 years. The lesions were classified clinically in mild, moderate and severe changes. Tongue moderate lesions presented the higher frequency (80%), followed by severe lesions on palate (74%). Oral cancer prevalence was 10.8% in the San Francisco village and 18.2% in Cayo de Palma village, no new cases were reported in Hato Nuevo village. This was the highest prevalence reported in comparison with other studies with similar population. The clinical and histological findings agree with the reported in literature, no relation was found between the degree of clinical severity and the dysplasia itself. Cases of oral submucous fibrosis-like lesions were found, which had never been reported in Latin America. Further studies are required in order to decrease the morbidity for this habit and to identify other related risk factors.

**Key words:** Oral cancer, oral premalignant lesions, reverse smoker, tobacco.

### Introduction

The habit of reverse smoking is a specific and peculiar custom in groups with low economical resources, besides it presents itself at warm or tropical zones, with higher frequency in women especially after the third decade of life. (1-4)

This habit's characteristic is putting the fired extreme of the cigarette, the heat lies inside the mouth, while the ciga-

rette is being hold by the teeth and lips, the seal provided by the lips allows to the slow inhaling of the cigarette. Air is supplied to the zone of combustion through the non heated extreme of the cigarette, at the same time the smoke is being expelled from the mouth and ashes are thrown out or swallowed.(2) The lips keep the cigarette wet, that increases its time of consumption from 2 to 18 minutes. The highest intern temperature of the cigarette can reach

760°C, and the intraoral air can be heated to 120°C. This temperature and the products of combustion increase the frequency of lesions inside the mouth compared with conventional smokers. (5)

The clinical aspect of the oral mucosa in patients with the habit of reverse smoke varies when compared with conventional smokers. The most commonly affected areas are tongue and palate. (6) Previously, these changes were called Nicotinic Stomatitis (1), and although there's not a consensus about the proper terminology yet, the term "changes of the palate related to reverse smoking" or "palatal keratosis associated with reverse smoking" (7) is most accepted actually since now is well known that nicotine is not the only etiologic factor, but many of the components of tobacco and/or cigarette.

Ramulu y col. (1), reported oral cancer in 2.4 % of the patients that presented nicotinic stomatitis due to reverse smoking, which implies that heat might be considered a cancer-producing agent.

In Colombia there are some very well defined regions with an usual presence of this habit that seems to be transmitted through generations. Quintero (8) reported in a study in pathology laboratories in Sincelejo-Sucre, 122 cases of oral cancer from where 63 % was seen in reverse smokers. In Montería-Córdoba, 207 cases and 41.5 % was also present in reverse smokers, showing that in these regions, the habit were endemic.

In Medellín-Antioquia, Colombia, in the Oral and Maxillofacial Surgery Service of Hospital Universitario San Vicente de Paul, several cases of oral squamous cell carcinoma were found in patients with reverse smoking habits, from Hato Nuevo village of the Department of Sucre, who reported the presence of this habit in several populations of the region with similar sociocultural characteristics. Because of this, the authors decide to establish the prevalence of reverse smokers at these villages of the Department of Sucre-Colombia, looking forward to characterize their socioculture conditions as well as their clinical and histological changes in the oral mucosa.

## Materials and Methods

A descriptive study with quantitative focus during the first semester of 2004 was performed. An informative campaign was made initially during three months through field advisors and community leaders of Hato Nuevo, San Francisco and Cayo de Palma villages, in order to sensibili-ze the population about the investigation. At a latter stage the researchers group visited the villages for a week, with the purpose of accomplish the epidemiologic gathering, to identify and select people with the habit of reverse smoking according to the criteria of inclusion (regular reverse smokers of any type of tobacco, during a period longer than 6 months, with a minimum doses of one cigarette per day, and those who used to smoke like that but stopped). This process was done with a home to home survey, with

socio demographic variables, concerning attitudes and behaviours related with the use of tobacco.

In order to fulfil the sampling, with the informed consents previously signed and following the recommendations of Scientific and Technology Development Direction of Health Minister and with the consent of Comitte of Ethics of Investigation Center of The Faculty of Dentistry, complete oral clinical exams were made and under local anaesthesia, biopsies were taken using disposable punch of 4 to 6 mm of diameter of the lesions with mild, moderate and severe changes in palate and tongue. Each sample was stored in test tubes containing buffered formol at 10%, properly labelled and with a histopathological application in order to orientate the pathologist. All biopsies were processed at Inmunodetection and Bioanalysis's Laboratory of Faculty of Dentistry of the University of Antioquia. They were stained with hematoxylin and eosin, read and examined for the pathologist co-researcher, based on internationally accepted parameters specifically for the dysplasia according to Pindborg and col. in 1997 (7) and for oral submucous fibrosis according to Pindborg and col. in 1966. (9) Due to the grades of dysplasia are highly subjective interexaminer, this article doesn't report mild and moderate dysplasia, but only its presence or absence and carcinomas.

Based on the reports of worldwide literature, calibration were made between the examiners (3 specialists in Oral Medicine and Oral Surgery with high clinical experience) using colour pictures or reverse smokers lesions in order to establish diagnostic criteria based on terms and degrees of severity:

Mild changes associated to the reverse smoker habit: Focally or diffusely involved mucosa by leukoedema (buccal mucosa), melanosis and/or whitish macules that can not be characterized as any other definable lesions.

Moderate changes associated to the reverse smoker habit: Focally or diffusely involved mucosa by macules, white plaques and/or papules, that can be joined or separated and that can not be characterized as any other definable lesions (palate). In tongue, white areas or plaques that can be separated by fissures. Also it can present changes described like mild.

Severe changes associated to the reverse smoker habit: Focally or diffusely involved mucosa by red macules and in palate by umbilicated papules that can not be characterized as any other definable lesions. It can present, as well, the changes described like mild and moderate.

Probably malignant changes: Exophitic and/or ulcerated lesion in oral mucosa of rapid evolution that clinically is compatible with oral carcinoma.

### *Clinical lesions*

Leukoedema: Surface of opalescent appearance, white-greyish, diffuse and irregular that does not give off when is scraped and disappears when the mucosa is distended. (10).

Whitish Macule: Flat lesion of white colour, that reflex the

original mucosa colour, of smooth surface, irregular edge, defined, that does not removes when scraped and does not disappear when the mucosa is distended. When it appears with melanosis can be observed of white-greyish colour. White plaque: Elevated lesion of 1 cm or more, palpable, of intense white colour, smooth or rough surface, irregular edge, defined, that does not removes when scraped and it can not be characterized as any other definable lesion. It can be associated to the tobacco yellow pigmentation.

White Papule: Elevated rounded lesion, well defined, with intense white colour, smaller than 1 cm and with smooth surface (11).

Umbilicated Papule: White or reddish papule, located in hard and/or soft palate, with invaginated red central point.

Melanosis: Macule or area of dark brown colour or brown or brown-grayish, located in the oral mucosa, defined and with irregular edges.

Red macule: Red flat lesion that shows variable red colour, smooth surface, irregular edges, located or diffused and can not be characterized as any other definable lesion.

The biopsies were also analyzed by two international pathologists (R Carlos, Guatemala y A Mosqueda, México) in order to confront the results obtained by the co-researcher pathologist (control of slants of measurement). To analyze and process the obtained data, samples were input in a SPSS program data base. First, an uni-varied analysis was performed looking for the assessment of the distribution of variables, then a bi-varied analysis was made in order to establish relationships between variables. This was made through the chi-squared test of independence, with a statistical significance of 0.05.

**Results**

The whole populations of three villages were 1914 inhabitants. From them, 501 (26%) were smokers and the prevalence of reverse smokers in that population were 73 (15%) (Table No. 1) From the whole population of reverse smokers, 46 persons agree to be subject to a clinic exam and 31 to take one biopsy at least.

Table No. 2 shows some of socio-cultural and demographic data of the studied population. From the 46 persons clinically studied, 42 (91.3%) were female, with an average age of 59.3 years old (range 29 -85), 41 persons (89.1%) of the sample smokes tobacco, all of them combined their ways of smoking (conventional and reverse), the average number of tobaccos a day was 2.29 (range 1 – 7), and the average time that they have smoked was 30.83 years (range 1 – 65). In 20 (43.5%) cases both parents of the respondent were also in the habit of reverse smoking and the main motivations to acquire the habit were as follows: pleasure 21 (45.6%), not to smoke in the conventional way 8 (17.4%) and habit 7 (15.2%). According to the information that they had about the consequences of reverse smoking, 28 (60.9%) individuals believed that the habit caused no damage, 21 (45.6%) believed that it could cause cancer and 5 (11%) thought it might be the cause of multiple effects to the body (bitter mouth, soar throat, lung damage, general damage and death).

Among 31 persons who agreed to be subject to clinical exam and biopsy, only 1 (3.2%) did not present any clinical lesion and did not require a biopsy. 48 biopsies were taken, 26 (54.2%) from the palate, 15 (31.3%) from the dorsum of the tongue and 7 (14.6%) from the other sites: labial mucosa, floor of the mouth, alveolar ridge and buccal mucosa.

Gender and age distribution among those who agreed to be examined through biopsies was 2 males (6.6%) and 28 (93.4%) female; showing the high statistic difference between genders (p<0.001). Ages of female individuals were from 29 to 74 years old and males were 60 and 63 years old.

A group of 25 (83.3%) of the 30 individuals presented the habit of reverse smoking, also showed some clinical changes in tongue as: Moderate changes 20 (80%), mild changes 4 (16%) and severe clinical changes 1 (4%). (Figure 1) 27 (90%) of the population showed some palatal lesions, with predominance of the severe clinical changes (74%), followed by moderate and mild changes. (Figure 2)

The study shows the relationship between the type of tobacco (tobacco or cigarette) and the severity of some lesions. 80% of the moderate and severe (p< 0.001) were

**Table 1.** Prevalence of smokers related to way of smoking. Sucre, Colombia. 2004

	SAN FRANCISCO	HATO NUEVO	CAYO DE PALMA	TOTAL
Smokers	223 (33%)	174 (21%)	104 (24%)	501 (26%)
Reverse smokers	44 (20%)	15 (9%)	14 (13%)	73 (15%)
Tobacco chewing	0	1	0	1
Habitants	671	810	433	1914

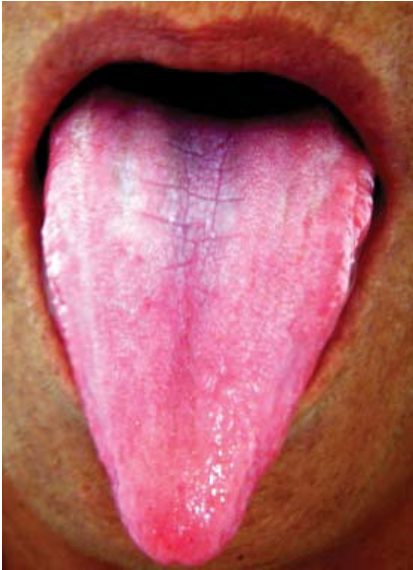**Table 2.** Knowledge and practices of reverse smokers about the habit. Sucre. Colombia, 2004.

1.	VARIABLE	NÚMBER	%
Sex	Female	42	91.3
	Male	4	8.7
Social Security	None	26	56.5
	ARS/EPS*	17	37
	NS/NR**	3	6.5
Type of cigarette used	Tobacco (calilla)	41	89.1
	Cigarette with filter	3	6.5
	NS/NR	2	4.3
Consequences in general health	Yes	18	39.1
	No	28	60.9
Consequences in oral health	Yes	29	63
	No	16	34.8
	NS/NR	1	2.2
Combined habit	Mainly reverse	8	17.4
	Mainly normal	27	58.7
	Same proportion	8	17.4
	NS/NR	3	6.5
Changes in mouth related to reverse smoking	Yes	11	23.9
	No	32	69.6
	NS/NR	3	6.5
Liquor consumption	Yes	3	6.5
	No	41	89.1
	NS/NR	2	4.4

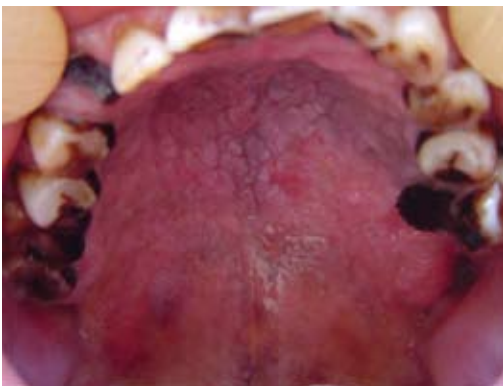\*ARS/ EPS: Types of Public Health Service in Colombia; \*\*NS/NR: Did not answer

**Table 3.** Frequently histopatological features in palatal and lingual lesions in reverse smokers. Sucre. Colombia, 2004.

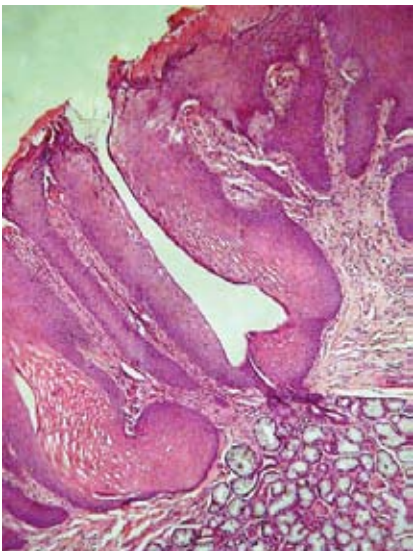
FEATURE	No.	%
Hyperkeratosis (hyperorto/hyperparakeratosis)	35	73%
Hyperparakeratosis in "christmas tree"	21	43,8%
Inflammatory cells in keratin layer	10	21%
Koilocytes	33	68,8%
Brown pigmentation in basal layer	23	48%
Oral submucous fibrosis-like lesions	13	27,1%
<b>NO DISPLASIA</b>	2	4,1%
<b>DISPLASIA AND CARCINOMAS</b>		
<b>Epithelial dysplasia</b>	40	83,3%
Palatal dysplasia (26 biopsies)	22	84,6%
Lingual dorsum dysplasia (15 biopsies)	14	93,3%
Displasia, other sites (7 biopsies)	4	57,1%
Severe dysplasia/Carcinoma in situ	1	2,1%
Microinvasive squamous cell carcinoma	3	6,3%
Invasive squamous cell carcinoma	2	4,2%
<b>Carcinomas</b>	6	12,5%



**Fig. 1.** Moderate changes in tongue associated to the reverse smoking habit.



**Fig. 2.** Severe changes in palate associated to the reverse smoking habit.



**Fig. 3.** Histological changes showing metaplasia in an excretory duct of minor salivary gland (10x).

associated with consumption of tobacco. There wasn't a statistic difference regarding years of smoking, frequency of smoking, age and lesions.

In the histological analysis of the biopsies, the changes more frequently observed (Table No. 3) (Figure 3) in the epithelium of the palatal and lingual mucosa were: in the superficial layer, hyperkeratosis (hyperorthokeratosis-hyperparakeratosis) in 35 (73%) and a particular type of hyperkeratosis (12) with some "christmas tree shapes" or "chevron-like" in 21 cases (43.8%). Also were observed inflammatory cells in keratin layer and some microabscesses in the superficial layer of keratin in 10 biopsies (21%), indicated infection by *Candida Albicans*; although we didn't special stains as PAS to demonstrate their presence. In 33 biopsies (68.8%) we found koilocytes (13) related with human papilloma-virus (HPV). The basal layer showed brown pigmentation in 23 cases (48%); it is accepted (14) that with the routine stain (HE) is possible to affirm that this pigment is melanin.

In 13 (27.1%) biopsies (4 from the palate and 9 from dorsum of the tongue), it was founded a thick band of connective tissue few cellular, over the muscle of the tongue or in the connective tissue over salivary glands on the palate and localized sometimes periductally. Those findings were defined as suggestive of oral submucous fibrosis, which were analyzed and confirmed by two international pathologists; (R. Carlos y A. Mosqueda). From these 13 cases, 12 (92.3%) had associated epithelial dysplasia.

The epithelial dysplasia was common in the mucosa of the lingual dorsum, 14 cases (93.3%). In the analyzed cases, we found 6 squamous cell carcinomas for a frequency of 12.5%: 1 carcinoma in situ of the mucosa of the upper lip, 3 microinvasive squamous cell carcinoma (2 in palate and 1 in dorsum of the tongue) and 2 basaloid squamous cell carcinomas on right side of the inferior alveolar ridge in two brothers.

### Discussion

The report of this habit and the effects on the oral mucous membrane are dated about three decades ago and is very hard to find isolated cases right now, most of them are found as report of cases.

Gavarasana y Susarla, in 1989 (15) in India, found out that the smoking reverse habit was 6.23 time more frequent in females than in males by the sixth decade of life.

There are very important differences between the types of tobacco consumed by the people on this study and other populations; the type of tobacco used in these villages (called "calilla" when is used by females) is about 10 to 15 cm long, and is home made with tobacco leaf dried out under the sun then rolled up over a thin stick and attached together with yucca starch (*manihot utilissima*) which is different from the one used in other parts of the world where the tobacco is mix with other products that might be potentially carcinogens by themselves as areca nut in India. (16)

The main study about oral precancer and cancer associated with the habit of reverse smoker was the one reported in India. (17,18) finding out in the district of Srikakulam in Andhra Pradesh 43.8% of reverse smokers. The prevalence of reverse smokers in our study was 15% in all three villages and the highest percentage was found in San Francisco (20%), less than the reported in India but higher than that one found in Colombia in The Third National Study of Morbidity in 1999, which was about 3.1%. (19) This study also reported that 1% of the population are tobacco smokers. The major percentage is found in the Atlantic Coast, in small towns where the people who used the reverse smoking were around 45 years old, like this study.

From the opinions of the people who have the reverse smoking habit and the motive of their start on this habit it's very noticeable the importance of the cultural role on the transmission of the habit, learned from the parents and transmitted from generation to generation. This study found that most of the people were not "pure" reverse smokers; most of them were conventional smokers who combined both types of smoking. This is different of the study in India where only 3% of population combined habits like conventional smoke and chewing tobacco.

It's very important to stand out that the information that have the patients with respect to the effects that in the general health produces the smoking is scarce; this might be the reason why when they were asked about noticing changes in their mouths related with reverse smoking, the most common answer was no. This could be related to other factors as the early age of off-start, that makes the changes appear in a chronic and progressive manner, thus the population might see them as natural, besides the very limited access to health services from these villages, and the few information about oral health care. Because of this, our study is very important for the analysis of the familiar history, information of the patients about the habit, and their consequences since then until now.

To study clinical changes, the term leukoplakia wasn't used as a clinical finding because as it is noted on its definition according to the Uppsala report (11) and WHO in 1997 (7) if there is a identified risk factor in the patients with this type of lesion, must be categorized according to the related risk factor, then a definition as white plaque associated to the smoking reverse habit is more acceptable, since the presence of the habit will affect the outcome of the lesion. Baric et al. (20) found that the leukoplakia in reverse smokers presented 19 times more risk of becoming carcinoma. However, more studies are needed to know the clinical, histological and molecular behaviours of these lesions.

There is no a consensus in the terminology used to describe these lesions in reverse smokers. Thus all of the investigators of this study propose a description of the terms and severity degrees (to discussion) that determine the compromise of the mucosa in these patients.

Clinically, the frequency found or oral lesions was very high (97.8%). Pindborg, Gupta y Mehta in 1984, (21) found out that 48% of the population showed some palatal changes associated with the habit, they focused their studies in this anatomical area; in this study we found that 90% the population presented palatal lesions. They also found that the more affected mucosa in the mouth were those of the palate and the tongue. In the population of our study the severe lesions were the most common on palate, while on tongue, the moderate lesions presented the highest frequency; although the way to describe the lesions are very different between the authors and without the use of the term leukoplakia, the reports found about these clinical lesions presented in patients with this habit and their possible outcome agreed with the findings in our study.

At the same way that Ramulu et al. (1) reported, we noticed that the grade of severity is directly related with the changes of the minor salivary glands and differing from Mehta et al. report (22), we found that the minor salivary glands in the soft palate suffer some changes in reverse smokers that use total prosthesis, which plays a protective role of hard palate mucosa and umbilicated papules and red points could be present in soft palate.

We contributed with the specific study of the tongue mucosa in patients because being one of the most affected sites; most of the studies focus their concern on describing the most frequent palatal findings. Lingual changes apparently start with a paleness of the lingual mucosa that advances towards whitish lesion, depapilation, then white plaque and finally red macula and ulcer or burned zone. Nevertheless, these data must be deeply investigated to determine their exact evolution. We haven't defined yet parameters that indicate the severity degree in the lingual mucosa.

We consider that before histological analysis is made, the manifestation of several lesions is which determines the level of commitment and severity in a patient with reverse smoking habit. Opposite to what literature has reported, we found in this study that severity does not have any relation to the habit's duration, tobacco number for day, or age; it seems that another type of even more influential risk factors are present in this population like the genetic predisposition, diet or chemical agents of the tobacco components. Maybe the number of tobaccos smoked daily is not correlated because the tobacco size in this population is different to the conventional size of cigarettes and different tobacco habit modalities in other studies. (23) In this study, was also found that tobacco smokers present higher frequency of lesions than cigarette smokers and this shows high statistic difference; thus a biochemical analysis is needed in order to determine the specific components of this type of tobacco and the used adhesive substance looking forward to figure out which ones of them might be carcinogenic agents.

Related to histological features, these are similar to the report of the literature (2), although a special type of parakeratosis is not mentioned in reverse smokers, like the military sign type or "christmas tree type".(12) We found the constant presence of inflammatory cells in the keratine layer, suggesting the presence of fungi species from the candida variety and also koilocytes, suggesting viral changes due to human papilloma-virus (HPV); for that reasons it should be to study the contribution of fungus and viruses to the development of these lesions. According to the reports of the literature, non-homogeneous leukoplakia nodular type it's related to Candida infection (24) and is possible that these fungi contribute to epithelial dysplasia. (25,26)

Brown pigmentation of basal layer could be explained as a smoker's melanosis (14) but also could be a racial pigmentation in persons that live in tropical areas. It would be important to analyze areas of depigmentation inside the previously pigmented lesions in reverse smokers, because this feature is indicative of transformation of dysplasia to anaplasia. (27)

In lesions similar to oral submucous fibrosis, the fibrosis founded in this study was founded submucous and not yuxtaepithelial (9) as seen in the oral submucous fibrosis associated to the consumption of areca catechu with chewing tobacco, (28) in India and related to dysplasia and anaplasia. In this study it is describe by the first time in America a similar lesion, who showed dysplasia in 92% of the cases and related to reverse smoking habit. Due to the socio-epidemiological and cultural characteristics described in the population study object, it would be helpful to make latter analyses that could verify and associate the presence of oral submucous fibrosis to the reverse smoking habit and other related factors.

## Conclusion

A conclusion from this study, is that reverse smoking habit continues to be of endemic behaviour, usually in a population with limited economic resources, with little knowledge of the tobacco as a risk factor to acquire different types of diseases (like oral cancer). The difficulties to access appropriate health services. The prevalence of oral cancer in two of the studied groups is a matter of worry, although we could not establish a relation of causality between reverse smoking habit and the oral cancer with this study. It is relevant the finding of oral submucous fibrosis-like lesions for the first time in America and on reverse smokers as far as we know, which shows the need for further studies, quick intervention for treatment of the patients and health campaigns to the general population and disease prevention. Finally we propose a definition of terms and severity degrees of lesions found in the oral mucosa (mainly palatal and lingual) of people with reverse smoking habit. This study would be the basis for further investigations. Reverse tobacco smoker habit is

a risk factor in populations of Latin America and the whole world.

## References

1. Ramulu C, Raju MV, Venkatarathnam G, Reddy CR. Nicotine stomatitis and its relation to carcinoma of the hard palate in reverse smokers of chuttas. *J Dent Res.* 1973 Jul-Aug;52(4):711-8.
2. Pindborg JJ, Mehta FS, Gupta PC, Daftary DK, Smith CJ. Reverse smoking in Andhra Pradesh, India: a study of palatal lesions among 10,169 villagers. *Br J Cancer.* 1971 Mar;25(1):10-20.
3. Quigley LF Jr, Shklar G, Cobb CM. Reverse cigarette smoking in Caribbeans: clinical, histologic, and cytologic observations. *J Am Dent Assoc.* 1966 Apr;72(4):867-73.
4. Mercado-Ortiz G, Wilson D, Jiang DJ. Reverse smoking and palatal mucosal changes in Filipino women. *Epidemiological features.* *Aust Dent J.* 1996 Oct;41(5):300-3.
5. Quigley LF Jr, Cobb CM, Hunt EE Jr. Measurement of oral and burning zone temperatures during conventional and reverse cigarette smoging. *Arch Oral Biol.* 1965 Jan-Feb;10:35-44.
6. Ortiz GM, Pierce AM, Wilson DF. Palatal changes associated with reverse smoking in Filipino women. *Oral Dis.* 1996 Sep;2(3):232-7.
7. Pindborg JJ, Reichart P, Smith CJ, Van der Waal I. Definitions and explanatory notes. *Precancer (Clinical classification).* In: *World Health Organization: histological typing of cancer and precancer of oral mucosa.* Berlin: Springer - Verlag; 1997. p. 31 - 4.
8. Quintero J. Registro de carcinoma escamocelular en los departamentos de Córdoba y Sucre. *Rev Odont Univ Cartagena.* 1985; II Edición, Ps. 15 - 17.
9. Pindborg JJ, Sirsat SM. Oral submucous fibrosis. *Oral Surg Oral Med Oral Pathol.* 1966 Dec;22(6):764-79.
10. Van Wyk CW. An investigation into the association between leukoedema and smoking. *J Oral Pathol.* 1985 Jul;14(6):491-9.
11. Axéll T, Pindborg JJ, Smith CJ, Van der Waal I. Oral white lesions with special reference to precancerous and tobacco-related lesions: conclusions of an international symposium held in Uppsala, Sweden, May 18-21 1994. *International Collaborative Group on Oral White Lesions.* *J Oral Pathol Med.* 1996 Feb;25(2):49-54.
12. Pindborg JJ, Reibel J, Roed-Peterson B, Mehta FS. Tobacco-induced changes in oral leukoplakic epithelium. *Cancer.* 1980 May 1;45(9):2330-6.
13. Henley JD, Summerlin DJ, Tomich CE. Condyloma acuminatum and condyloma-like lesions of the oral cavity: a study of 11 cases with an intraductal component. *Histopathology.* 2004 Mar;44(3):216-21.
14. Hedin CA, Larsson A. The ultrastructure of the gingival epithelium in smokers' melanosis. *J Periodontal Res.* 1984 Mar;19(2):177-90.
15. Gavarasana S, Susarla MD. Palatal mucosal changes among reverse smokers in an Indian village. *Jpn J Cancer Res.* 1989 Mar;80(3):209-11.
16. Chang YC, Hu CC, Tseng TH, Tai KW, Lii CK, Chou MY. Synergistic effects of nicotine on arecoline-induced cytotoxicity in human buccal mucosal fibroblasts. *J Oral Pathol Med.* 2001 Sep;30(8):458-64.
17. Gupta PC, Mehta FS, Daftary DK, Pindborg JJ, Bhonsle RB, Jalnawalla PN, et al. Incidence rates of oral cancer and natural history of oral precancerous lesions in a 10-year follow-up study of Indian villagers. *Community Dent Oral Epidemiol.* 1980;8(6):283-333.
18. Mehta FS, Jalnawalla PN, Daftary DK, Gupta PC, Pindborg JJ. Reverse smoking in Andhra Pradesh, India: variability of clinical and histologic appearances of palatal changes. *Int J Oral Surg.* 1977 Apr;6(2):75-83.
19. República de Colombia. Ministerio de Salud. Tabaquismo. En: República de Colombia. Ministerio de Salud. III Estudio Nacional de Salud Bucal - ENSAB III- II Estudio Nacional de factores de riesgo de enfermedades crónicas - ENFREC II - Tomo II. Colombia: 1999. p. 32 - 3.
20. Baric JM, Alman JE, Feldman RS, Chauncey HH. Influence of cigarette, pipe, and cigar smoking, removable partial dentures, and age on oral leukoplakia. *Oral Surg Oral Med Oral Pathol.* 1982 Oct;54(4):424-9.
21. Gupta PC, Mehta FS, Pindborg JJ. Mortality among reverse

chutta smokers in south India. Br Med J (Clin Res Ed). 1984 Oct 6;289(6449):865-6.

22. Mehta FS, Sahiar BE, Daftary DK, Gupta PC, Pindborg JJ. A correlative histocytological study of carcinoma and epithelial atypia of the palate among Indian reverse smokers. Br J Cancer. 1972 Jun;26(3):230-3.

23. Martinez-Conde R, Aguirre JM, Burgos JJ, Rivera JM. Clinicopathological factors in early squamous cell carcinoma of the tongue and floor of the mouth, in Biscay (the Basque Country, Spain). Med Oral. 2001 Mar-Apr;6(2):87-94.

24. Gupta PC, Bhonsle RB, Murti PR, Daftary DK, Mehta FS, Pindborg JJ. An epidemiologic assessment of cancer risk in oral precancerous lesions in India with special reference to nodular leukoplakia. Cancer. 1989 Jun 1;63(11):2247-52.

25. Field EA, Field JK, Martin MV. Does Candida have a role in oral epithelial neoplasia. J Med Vet Mycol. 1989;27(5):277-94.

26. Krogh P, Hald B, Holmstrup P. Possible mycological etiology of oral mucosal cancer: catalytic potential of infecting Candida albicans and other yeasts in production of N-nitrosobenzylmethylamine. Carcinogenesis. 1987 Oct;8(10):1543-8.

27. Hedin C, Pindborg JJ, Daftary DK, Mehta FS. Melanin depigmentation of the palatal mucosa in reverse smokers: a preliminary study. J Oral Pathol Med. 1992 Nov;21(10):440-4.

28. Murti PR, Bhonsle RB, Gupta PC, Daftary DK, Pindborg JJ, Mehta FS. Etiology of oral submucous fibrosis with special reference to the role of areca nut chewing. J Oral Pathol Med. 1995 Apr;24(4):145-52.

*Acknowledgements:* To the habitants of Hato Nuevo, San Francisco and Cayo de Palma, Sucre, Colombia; to the field advisors for their help and attention in the accomplishment of this study and to the CODI by the project financing.