

Bisphosphonate-related osteonecrosis of the jaw in patients with multiple myeloma

Pedro Infante Cossío ¹, Antonio Cabezas Macián ², José Luis Pérez Ceballos ³, Julián Palomino Nicas ⁴, José Luis Gutiérrez Pérez ⁵

(1) Profesor Asociado de Cirugía Bucal, Facultad de Odontología, Facultativo Especialista del Servicio de Cirugía Oral y Maxilofacial, Hospital Universitario Virgen del Rocío, Universidad de Sevilla

(2) Odontólogo, Alumno del Master de Cirugía Bucal, Facultad de Odontología, Universidad de Sevilla

(3) Residente del Servicio de Cirugía Oral y Maxilofacial, Hospital Universitario Virgen del Rocío

(4) Facultativo Especialista de la Unidad de Enfermedades Infecciosas, Hospital Universitario Virgen del Rocío

(5) Profesor Titular Vinculado de Cirugía Bucal, Facultad de Odontología, Jefe de Servicio de Cirugía Oral y Maxilofacial, Hospital Universitario Virgen del Rocío, Universidad de Sevilla. Sevilla

Correspondence:

Dr Pedro Infante-Cossio

Servicio de Cirugía Oral y Maxilofacial

Hospital Universitario Virgen del Rocío

Av. Manuel Siurot

41013 Sevilla, Spain.

E-mail: pinfante@us.es

Received: 5-05-2007

Accepted: 9-10-2007

Indexed in:

-Index Medicus / MEDLINE / PubMed
-EMBASE, Excerpta Medica
-SCOPUS
-Indice Médico Español
-IBECS

Infante-Cossío P, Cabezas-Macián A, Pérez-Ceballos JL, Palomino-Nicas J, Gutiérrez-Pérez JL. Bisphosphonate-related osteonecrosis of the jaw in patients with multiple myeloma. Med Oral Patol Oral Cir Bucal. 2008 Jan1;13(1):E52-7.

© Medicina Oral S. L. C.I.F. B 96689336 - ISSN 1698-6946

<http://www.medicinaoral.com/medoralfree01/v13i1/medoralv13i1p52.pdf>

Abstract

Purpose: To review the main clinical-radiographic, therapeutic, and preventive aspects of osteonecrosis related to intravenous bisphosphonate therapy in patients with multiple myeloma.

Materials and methods: Between 2005 and 2006, we studied four patients with previous diagnosis of multiple myeloma treated with intravenous zoledronic acid, presenting nonhealing extraction sockets and intraoral exposed bone. We assessed the location of lesions, the relation with previous history of dento-alveolar surgery procedures, the clinical features, the treatments carried out, and the outcomes achieved.

Results: All the patients were treated with chlorhexidine mouthwashes and oral amoxicillin-clavulanic acid for long periods of time. Two patients did not respond to the conservative management and needed surgical bone debridement.

Conclusions: Dental extractions seem to contribute the development of osteonecrosis of the jaw in patients with multiple myeloma treated with intravenous bisphosphonate therapy. Whereas the pathologic mechanisms are not known, these patients should undergo frequent check-ups before, during, and after bisphosphonate therapy. The management must be symptomatic and palliative, including systemic antibiotics, control of pain, and chlorhexidine mouthwashes during long periods of time.

Key words: Bisphosphonates, osteonecrosis, jaws, multiple myeloma, cancer, oral complications.

Introduction

Bisphosphonates are drugs that inhibit bone resorption, indicated in the management of diverse diseases like multiple myeloma (MM), bone metastasis caused by breast and prostate cancer, and the Paget's disease, as well as to prevent the osteoporosis in the menopause. In patients with MM, bisphosphonate therapy has improved the quality of

life significantly because they are able to alleviate the pain and to reduce the development of skeletal complications. Since Marx (1) and Ruggiero et al. (2) in 2003 published the first patient series in which they associated the use of bisphosphonates with the appearance of exposed bone of the jaws in the oral cavity and the development of osteonecrosis, it had been published an increasing number

of articles of bisphosphonate-related to osteonecrosis (BRON) (3-5). Recently, the American Association of Oral and Maxillofacial Surgeons (6) has established 3 characteristics that must be present to consider a BRON: (i) current or previous treatment with a bisphosphonate; (ii) exposed, necrotic bone in the maxillofacial region that has persisted for more than 8 weeks; and (iii) no history of radiation therapy of the jaws. Most of clinical cases reported have been related to the use of intravenous bisphosphonate (pamidronate or zoledronic acid), although it had been published some cases associated to oral bisphosphonate administration (7). The main risk factor for this complication is the previous history of dento-alveolar surgery, but it may appear spontaneous cases without previous trauma (3). The risk of developing a BRON in patients with MM seems to be time-dependent, and turns out to be significant after 36 months (8). Its incidence has not been completely established yet, although it has been reported an incidence of BRON in patients with MM of 6.9% (9), 9.9% (10), and 10.93% (11). In a series of 25 patients with BRON, Clarke et al. (12) found that an 80% of patients had a MM.

The aim of this work has been to present our clinical and therapeutic experience on four patient diagnosed of BRON with previous history of MM attended during the last 2 years, focussing special consideration to clinical-radiographic, therapeutic, and preventive features of this complication, describing a clinical case that developed a severe and progressive jaw osteonecrosis after previous dental extractions.

Material and methods

Between January 2005 and December 2006, 4 patients with nonhealing extraction sockets and exposed bone in the oral cavity have been attended in the Oral and Maxillofacial Surgery Department of the Virgen del Rocio University Hospital of Seville, Spain. All the patients had been previously diagnosed of MM and treated with intravenous zoledronic acid. We studied the location of lesions, relation with previous history of dento-alveolar surgery procedures, symptoms and clinical features, treatments carried out, and outcomes achieved. All the patients underwent a panoramic x-ray and a CT scan. A bone gammagraphy was made in 1 patient. Biopsies were taken from bone areas in 3 patients. All the patients were initially treated with chlorhexidine mouthwashes and oral amoxicillin-clavulanic acid during long periods of time. 2 patients did not respond to the conservative treatment and needed surgical treatment (Table 1).

Results

The patients consisted of 1 man and 3 women, with ages between 56 and 82 years (average age of 69.5 years). All the patients consulted by local pain. All the patients had exposed bone in the oral cavity and signs of local infec-

tion. One patient developed a cutaneous fistula that was treated with cefadroxil according to antibiogram, and analgesia with fentanyl and morphine. All the patients had previously received intravenous zoledronic acid. At diagnosis, 2 patients went on with bisphosphonate therapy. Only 1 patient continued the treatment with bisphosphonate after BRON was diagnosed. Previous history of one or several dental extractions by dentists was detected in all the patients. Panoramic x-rays and TCs showed areas of bone necrosis that alternated radiopaque images with radiolucent areas, irregularities in the cortical bone, and affectation of the soft tissue. Histological studies informed of bone necrosis, inflammatory granulation tissue and abscessification. In the microbiological culture there were abundant bacterial colonies of saprophyte oral microbiota. In 1 patient klebsiella pneumoniae was isolated. In 3 patients the mandible was involved and in 1 patient the maxilla. One patient developed a para-mandibular abscess with extraoral cutaneous fistula (Table 1).

Clinical case

A 56 years-old male was sent by a dentist in June 2005 to evaluate "an infection of the mandible after a dental extractions, that after 3 months had not responded to treatment with antibiotics and previous bone debridement". In his medical antecedents he emphasized that he had been diagnosed of a MM in 2001, and had been treated with chemotherapy, and submitted to a marrow bone autotransplant. He had a previous history of vertebrate fractures, and zoledronic acid intravenous administration in doses of 4 mg during 3 years. First and second right lowers molars had been extracted by a dentist in February 2005. In the intraoral exploration 2 nonhealing extraction sockets were found, and the alveolar bone around was partially exposed (Figure 1A). The second premolar had mobility and acute pain to the percussion. In the panoramic x-ray the post-extraction socket tracks were seen, and a root of the first left molar remained in place (Figure 1B). Under local anaesthesia it was carried out the extraction of the root and the second premolar, and the debridement of a minimum necrotic bone; a biopsy was taken, and a microbiological culture was made. The histological study was informed as an "abscessificant osteomyelitis with central bone osteonecrosis". The immuno-histochemistry study did not demonstrate concordant findings with myeloma (slight chain and CD-79 kappa and lambda negative). In the microbiological culture there were abundant bacterial colonies without presence of *Aspergillus*. From these results, the BRON diagnosis was set down, and a oral hygiene conservative management with 0.12% chlorhexidine mouthwashes was established, antibiotic treatment 875/125 mg amoxicillin-clavulanic acid 3 times a day by oral administration during 4 weeks and nonsteroid anti-inflammatories. In the following 3 months, the patient evolved towards a clinical and radiographic improvement,

Table 1. Characteristics of the 4 patients with MM, previous history of intravenous zoledronic acid treatment, and jaw osteonecrosis.

Age (years) / Sex	Location	Risk factor	Signs	Exploration	Radiological studies	Discontinuation of bisphosphonates	Treatment	Outcome/healing
82/F	Maxilla	Teeth extractions	Local pain	Exposed bone Local infection	OPG CT	Yes	Chlorhexidine Oral antibiotics	Partial resolution
56/M	Mandible	Teeth extractions	Local pain Cutaneous fistula	Exposed bone Local infection	OPG CT Gamma-graphy	Yes	Chlorhexidine Oral and IV antibiotics Surgical debridement	Remaining exposed bone
59/F	Mandible	Tooth extraction	Local pain	Exposed bone Local infection	OPG CT	No	Chlorhexidine Oral antibiotics	Partial resolution
81/F	Mandible	Teeth extractions	Local pain	Exposed bone Local infection	OPG CT	Yes	Chlorhexidine Oral and IV antibiotics Surgical debridement	Small exposed area of bone

and the pain diminish almost completely although the soft tissue around the sockets had not healed. After consulting with the haematologist, the treatment with intravenous zoledronic acid was discontinued.

In December 2005, the patient presented concerned with an intense local pain, although the clinical and radiographic exploration continued being anodyne. Treatment with nonsteroids anti-inflammatories, amoxicillin-clavulanic acid was restored again by oral administration. In spite of treatment, osteonecrosis continued progressing, and in February 2006 presented an exposed bone of 2x1 cm surrounded by an edge of reddened mucosa (Figure 2A). In the right sub-mandibular region appeared a soft tissue swelling with a purulent cutaneous fistula (Figure 2B), from where a microbiological culture was taken, isolating *klebiella pneumoniae*, *streptococcus sanguis* and *staphylococcus epidermidis*. In the panoramic x-ray bone necrosis had increased considerably showing a radiopaque image in the body of the mandible with radiolucent areas (Figure 2C). In the CT scan multiple radiolucent areas were observed along with areas of sclerosis in the body mandible of approximately 4 cm, with irregularities in cortical and the affectation of the soft tissues, subcutaneous fat edema,

and thickening of the cutaneous plane (Figure 2D). The patient initiated treatment with oral cefadroxil 1 g twice a day according to the antibiogram, and for the control of the pain it was administrated fentanyl 75 mg in transdermis patches every 72h, and morphine sulphate 10 mg in tablets was indicated for pain rescue. During 2 months the patient continued the treatment with cefaxodril 1 g twice a day, pregabalin 150 mg twice a day, and 600 mg ibuprofen three times a day. In spite of clinical improvement, in May 2006 a great bone area of sequestrum was delimited (Figure 3A). The bone gammagraphy detected an increase of the tracer in the right body of the mandible (Figure 3B). Under general anaesthesia bone sequestrums were debrided until apparently healthy bone. The outcome, although slow and torpid, has evolved to a significant improvement, and at this moment, 18 months after the initial diagnosis, our patient is asymptomatic and has no evidence of infection. In the panoramic x-ray, the image has been standardized, although intraoral soft tissue has not healed totally. The patient is followed in scheduled check-ups, and with rinsing of chlorhexidine mouthwashes.

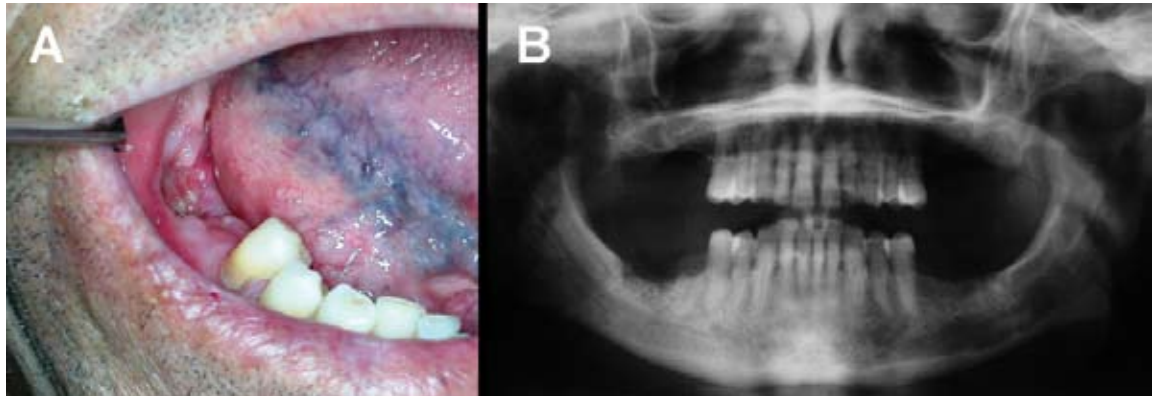


Fig. 1. A y B. (A): Intraoral view of nonhealing sockets and mucosa around the 1° and 2° right lower molars, when the patient was sent 6 months after dental extractions, and (B): panoramic x-ray showing initial images of osteonecrosis.

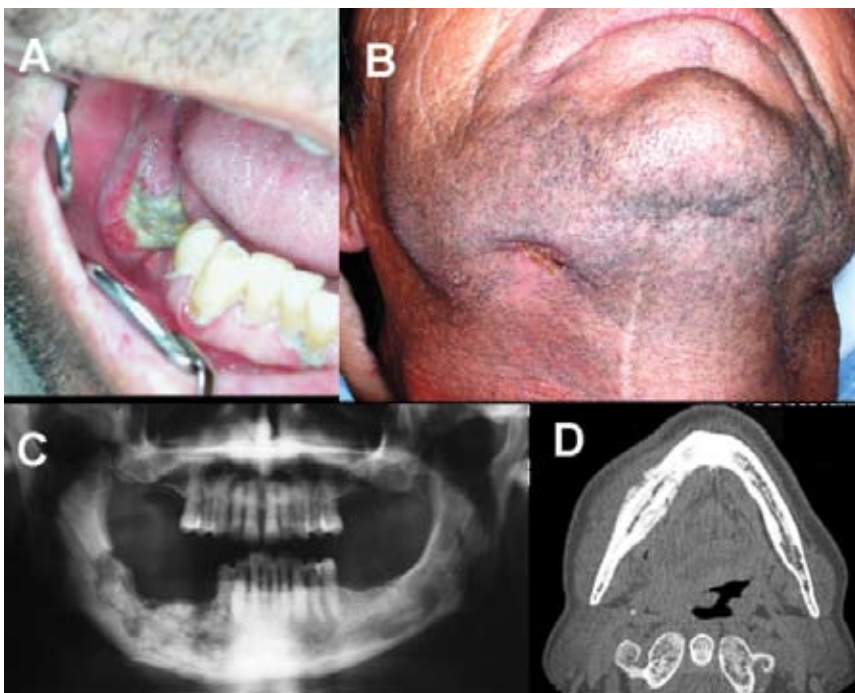


Fig. 2. A-D. (A): Three months later appeared necrotic bone and mucosal inflammation and (B): soft tissue swelling and extraoral purulent fistula to the right sub-mandibular region. (C): The panoramic x-ray showed a great area of osteolysis with sequestrums and bone necrosis. (D): In the CT scan a sclerosis area was observed in the mandible along with irregularities in cortical bone and affection of soft tissues.

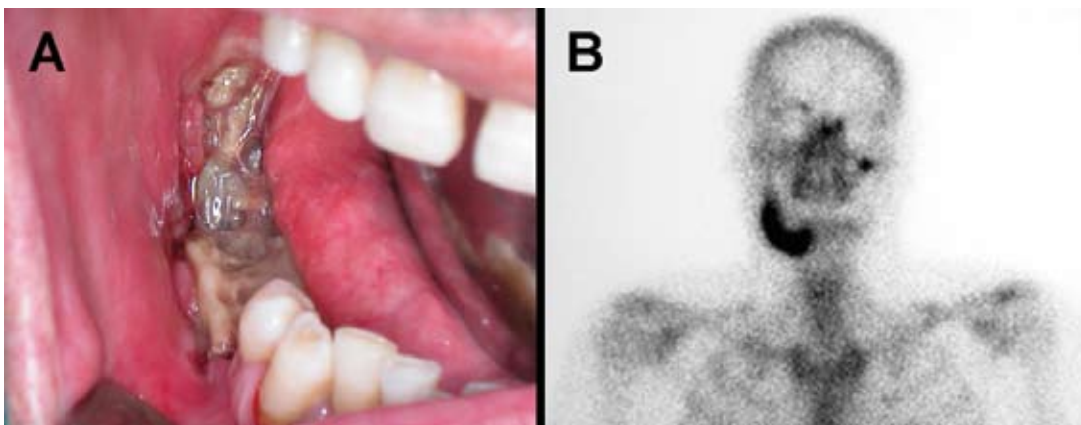


Fig. 3. A y B. (A): Sequestrum of bone 6 months after the start of conservative management. (B): Bone gammagraphy was compatible with bone infection.

Discussion

BRON is an exclusive affection of jaws related to smaller bone traumas with a deficient healing, and to a vascularity compromised by the bisphosphonate, within the usual microbiological flora of the oral cavity (3,13). Some authors think that it takes place as a result of the direct influence of the bisphosphonate that inhibit osteoclast cells that provoke bone resorption, and by the induction of the precursory osteoblast cells of the bone apposition. Also they restrain the bone calcium liberation induced by stimulating factors released by the tumor cells (14).

MM is a member of a neoplasm group with plasmatic cells that share two basic characteristics: the elevated production of monoclonal antibodies and the loss of bone by osteolysis. Intravenous administrations of zoledronic acid and pamidronate have demonstrated that significantly reduce the skeletal complications in patients with MM (6). Nevertheless these patients have more risk to develop a BRON that patients with breast cancer which take bisphosphonate. The age seems to be a risk factor in patients with MM, because by every age decade the risk is increased in 9% (15). The average age of the patients of this series was almost 70 years old, two of them over 80 years old.

The appearance of a BRON supposes an important deterioration in the quality of life of a patient. It is located in the body of the mandible with more frequency, and it is characterized by the finding of exposed bone in the oral cavity, non-vital and that does not heal in 8-12 weeks (6). The symptoms usually are almost imperceptible or slight at the start, but with time they will be severe and causing extensive bone sequestrums, suppuration, and mucosa or cutaneous fistula, with continuous and intense pain. Ruggiero et al. (16) have proposed a classification in three clinical stages. Stage 1 is characterized by asymptomatic exposed necrotic bone. Stage 2 is characterized by necrotic bone exposed associated to pain, soft tissue inflammatory swelling or secondary infection. Stage 3 presents exposed necrotic bone associated to pain, soft tissue inflammatory swelling or secondary infection difficult to manage with oral or intravenous antibiotic administration, and the pathological presence of cutaneous fistula, bone fractures or great volume areas of necrosis that may require surgical treatment. The case described in this work presented these three evolutionary stages in the 18 months of follow-up. For the diagnosis of BRON a radiological study of bone is required along with soft tissues. In early stages, radiological studies may not show significant changes. In stages 2 and 3, radiographies reveal images of osteolysis that normally extend beyond the area apparently affected, since the radiological images are only visible when a great part of mineralized bone is lost. These images determine the differential diagnosis with osteomyelitis, primary myeloma or bone metastasis disease. In most of severe cases are necessary studies of CT scan (17) or bone gammagraphy

to establish the extension and affectation of adjacent anatomical structures.

The best therapeutic strategy is the prevention of BRON setting up a program of oral and dental cares before, during and after bisphosphonate therapy that may reduce the complications. The beginning of the bisphosphonate therapy must be delayed until improving the oral hygiene, and the extraction of the badly teeth must be carried out one month before the start. Once initiated the administration of the bisphosphonate, invasive dental treatments like the dental extractions must be limited, and the use of 0.12% chlorhexidine mouthwashes is advised. Calvo-Villas et al. (11) question to prolong the treatment with zoledronic acid in patients with asymptomatic MM after 2 years to avoid the BRNO risk. Nevertheless, discontinuing bisphosphonate therapy has not demonstrated a reduction in the BRON risk, since this drug has a long mean life and persists later in the human bone up to 10 years (16). Nevertheless, if patient general conditions allow it, a long term discontinuation of the bisphosphonate therapy can be beneficial in stabilizing the progression of the osteonecrosis, reducing the risk of new areas of necrotic bone, and diminishing the symptoms (6), which must done only after consulting with the oncologist or haematologist. We carried out it in 3 patients of our series.

The management of patients with an established diagnosis of BRON poses a therapeutic challenge. In stage 1, when BRNO is limited, a conservative nonsurgical treatment can be sufficient. It is recommended to intensify oral hygienic measures, to avoid the irritating factors, and to establish a long-term treatment with systemic antibiotics of wide spectrum and conventional nonsteroid anti-inflammatories. When a purulent fistula is detected (stage 2), cultures and antibiogram should be carried out, although cultures are usually compatible with saprophyta flora (17). The microbiological cultures are useful to select the best antibiotic to treat an infection, although antibiotics rarely obtain adequate concentrations due to their difficult access to bone because of the avascular bone necrosis (3).

In severe and progressive BRON in stage 3, a conservative treatment may be unsuccessful, as it happened in the clinical case presented in this work. Surgery is indicated when the conservative treatment have not worked out, or in lesions that show a progressive and symptomatic clinical course. When a surgical treatment is carried out (debridement, bone sequestrectomy, bone resection), we have to consider that bone vascularization is compromised, and any surgical intervention although limited, can increase more exposed or necrotic bone areas, and besides can be a way of penetration of new micro-organisms. When removing mobile segments of bony sequestrums is needed, the smaller amount of uninvolved bone should be removed, and the less soft tissues should be manipulated (18). Other therapeutic alternatives like hyperbaric oxygen, recommended in the management of the osteoradionecrosis,

are not considered of utility in the ONRB (19). In many cases it is not achieved a completely control of exposed bone in spite of treatment, and the treatment should last during months or years, and that is why it is necessary to count on the collaboration of the patient

In summary, patients with MM that take intravenous bisphosphonate must be put under frequent scheduled check-ups to detect complications, during and after the treatment. Although does not exist a definitive management for the ONRB, it must be symptomatic and palliative, including systemic antibiotics, control of the pain, and chlorhexidine mouthwashes during long periods of time. The aim of the management consists of preventing and decreasing the development or progression of bone necrosis, the control of the infection, and in alleviating the painful symptomatology.

References

1. Marx RE. Pamidronate (Aredia) and zoledronate (Zometa) induced avascular necrosis of the jaws: a growing epidemic. *J Oral Maxillofac Surg.* 2003 Sep;61(9):1115-7.
2. Ruggiero SL, Mehrotra B, Rosenberg TJ, Engroff SL. Osteonecrosis of the jaws associated with the use of bisphosphonates: a review of 63 cases. *J Oral Maxillofac Surg.* 2004 May;62(5):527-34.
3. Marx RE, Sawatari Y, Fortin M, Broumand V. Bisphosphonate-induced exposed bone (osteonecrosis/osteopetrosis) of the jaws: risk factors, recognition, prevention, and treatment. *J Oral Maxillofac Surg.* 2005 Nov;63(11):1567-75.
4. Bagan JV, Jimenez Y, Murillo J, Hernandez S, Poveda R, Sanchis JM, et al. Jaw osteonecrosis associated with bisphosphonates: multiple exposed areas and its relationship to teeth extractions. Study of 20 cases. *Oral Oncol.* 2006 Mar;42(3):327-9.
5. Dimitrakopoulos I, Magopoulos C, Karakasis D. Bisphosphonate-induced avascular osteonecrosis of the jaws: a clinical report of 11 cases. *Int J Oral Maxillofac Surg.* 2006 Jul;35(7):588-93.
6. Advisory Task Force on Bisphosphonate-Related Osteonecrosis of the Jaws, American Association of Oral and Maxillofacial Surgeons. American Association of Oral and Maxillofacial Surgeons position paper on bisphosphonate-related osteonecrosis of the jaws. *J Oral Maxillofac Surg.* 2007 Mar;65(3):369-76.
7. Migliorati CA. Bisphosphonate-associated oral osteonecrosis. *Oral Surg Oral Med Oral Pathol Oral Radiol Endod.* 2005 Feb;99(2):135.
8. Ponte Fernández N, Estefanía Fresco R, Aguirre Urizar JM. Bisphosphonates and oral pathology I. General and preventive aspects. *Med Oral Patol Oral Cir Bucal.* 2006 Aug 1;11(5):E396-400.
9. Durie BG, Katz M, Crowley J. Osteonecrosis of the jaw and bisphosphonates. *N Engl J Med.* 2005 Jul 7;353(1):99-102.
10. Bamias A, Kastritis E, Bamia C, Mouloupoulos LA, Melakopoulos I, Bozas G, et al. Osteonecrosis of the jaw in cancer after treatment with bisphosphonates: incidence and risk factors. *J Clin Oncol.* 2005 Dec 1;23(34):8580-7.
11. Calvo-Villas JM, Tapia Torres M, Govantes Rodríguez J, Carreter de Granda E, Sicilia Guillén F. Osteonecrosis of the jaw in patients with multiple myeloma during and after treatment with zoledronic acid. *Med Clin (Barc).* 2006 Oct 21;127(15):576-9.
12. Clarke BM, Boyette J, Vural E, Suen JY, Anaissie EJ, Stack BC Jr. Bisphosphonates and jaw osteonecrosis: the UAMS experience. *Otolaryngol Head Neck Surg.* 2007 Mar;136(3):396-400.
13. Jiménez Y, Bagan JV. Bisphosphonates, as a new cause of drug-induced jaw osteonecrosis: an update. *Med Oral Patol Oral Cir Bucal* 2005;10:Suppl2:E88-91.
14. Schwartz HC. Bisphosphonate-associated osteonecrosis of the jaws. *J Oral Maxillofac Surg.* 2005 Oct;63(10):1555-6.
15. Badros A, Weikel D, Salama A, Goloubeva O, Schneider A, Rapoport A, et al. Osteonecrosis of the jaw in multiple myeloma patients: clinical features and risk factors. *J Clin Oncol.* 2006 Feb 20;24(6):945-52.
16. Ruggiero SL, Fantasia J, Carlson E. Bisphosphonate-related osteonecrosis of the jaw: background and guidelines for diagnosis, staging and management. *Oral Surg Oral Med Oral Pathol Oral Radiol Endod.* 2006 Oct;102(4):433-41.
17. Leite AF, Figueiredo PT, Melo NS, Acevedo AC, Cavalcanti MG, Paula LM, et al. Bisphosphonate-associated osteonecrosis of the jaws. Report of a case and literature review. *Oral Surg Oral Med Oral Pathol Oral Radiol Endod.* 2006 Jul;102(1):14-21.
18. Mortensen M, Lawson W, Montazem A. Osteonecrosis of the jaw associated with bisphosphonate use: Presentation of seven cases and literature review. *Laryngoscope.* 2007 Jan;117(1):30-4.
19. Pastor-Zuazaga D, Garatea-Crelgo J, Martino-Gorbea R, Etayo-Pérez A, Sebastián-López C. Osteonecrosis of the jaws and bisphosphonates. Report of three cases. *Med Oral Patol Oral Cir Bucal.* 2006 Jan 1;11(1):E76-9.