

Endosseous dental implant fractures an analysis of 21 cases

Jordi Gargallo Albiol ¹, Marta Satorres Nieto ², José Luis Puyuelo Capablo ³, María Angeles Sánchez Garcés ⁴, Joan Pi Urgell ⁵, Cosme Gay Escoda ⁶

(1) Doctor of Odontology. Professor of the Master of Oral Surgery and Implantology. School of Dentistry of the University of Barcelona

(2) Dentist. Associate Professor of Oral Surgery. Professor of the Master of Oral Surgery and Implantology. School of Dentistry of the University of Barcelona

(3) Physician and dentist. Private practice in Barcelona

(4) Physician and dentist. Associate Professor of Oral Surgery. Professor of the Master of Oral Surgery and Implantology. School of Dentistry of the University of Barcelona

(5) Physician and dentist. Director of the Bränemark Center, Barcelona

(6) Chairman of Oral and Maxillofacial Surgery. Director of the Master of Oral Surgery and Implantology. School of Dentistry of the University of Barcelona. Oral and Maxillofacial Surgeon of the Teknon Medical Center, Barcelona (Spain)

Correspondence:

Prof. Cosme Gay-Escoda

Centro Médico Teknon

Vilana 12

08022 – Barcelona. Spain

E-mail: cgay@ub.edu

Received: 27/01/2007

Accepted: 6/12/2007

Indexed in:
-Index Medicus / MEDLINE / PubMed
-EMBASE, Excerpta Medica
-SCOPUS
-Indice Médico Español
-IBECS

Gargallo-Albiol J, Satorres-Nieto M, Puyuelo-Capablo JL, Sánchez-Garcés MA, Pi-Urgell J, Gay-Escoda C. Endosseous dental implant fractures an analysis of 21 cases. *Med Oral Patol Oral Cir Bucal*. 2008 Feb;13(2):E124-8.

© Medicina Oral S. L. C.I.F. B 96689336 - ISSN 1698-6946

URL: <http://www.medicinaoral.com/medoralfree01/v13i2/medoralv13i2p124.pdf>

Summary

Implant fracture is an infrequent cause of implant failure. The present study evaluates 21 fractured implants, with an analysis of patient age and sex, the type, length and diameter of the implant, positioning in the dental arch, the type of prosthetic rehabilitation involved, the number of abutments and pontics, the presence or absence of distal extensions or cantilevers, and loading time to fracture.

Implant fracture was more common in males than in females (15:4), and the mean patient age was 56.9 years. Most cases (n = 19) corresponded to implant-supported fixed prostheses - 16 with cantilevers of different lengths - while only two fractured implants were supporting overdentures instead of fixed prostheses. The great majority of fractured implants (80.9%) were located in the molar and premolar regions, and most fractured within 3-4 years after loading.

It is important to know and apply the measures required to prevent implant fracture, and to seek the best individualized solution for each case - though complete implant removal is usually the treatment of choice.

Key words: Dental implants, osteointegration, fracture.

Introduction

The incidence of dental implant fracture is between 0.16-1.5% of cases (1-11). There are two main causes of implant fracture: (a) Mechanical overload leading to metal fatigue. When the resistance limit is exceeded, fracture results. Overload can also be a consequence of patient physiological alterations (e.g., parafunctional activity). In effect, both centric and eccentric bruxism can lead to implant overload and metal fatigue. Other overload-related factors are of prosthetic origin, including inadequate occlusion, the presence of distal extensions or cantilevers in implant-

supported prostheses, and a lack of prosthetic passive fit over the implants (4,10,12-14); (b) Peri-implant vertical bone loss (4,10,12,15,16), attributable to both chronic peri-implant inflammation and occlusal trauma. When vertical bone loss coincides with the apical limit of the screw joining transepithelial abutment to implant, the risk of implant fracture increases considerably (10).

The present study analyzes dental implant fracture on one hand to avoid such complications, and on the other to define the best management solution when fracture effectively occurs.

Material and Method

Twenty-one implant fractures were documented, corresponding to the period 1985-2003. Different parameters were recorded for each case, including patient age and sex, the type, length and diameter of the implant, positioning in the dental arch, the type of prosthetic rehabilitation involved, the number of abutments and pontics, the presence or absence of distal extensions or cantilevers, loading time to fracture, and the presence of parafunctional activity. Lastly, the therapeutic solution offered in each case was analyzed.

Results

In a series of 1500 implants documented during the study period, we recorded 21 fractured implants, representing an incidence of 1.4%. Of these 21 fractured implants, 16 were of the Branemark® type (Nobel Biocare®, Göteborg, Sweden), 3 of the Screw-vent® type (Dentsply®, Core-Vent Implant Division, Encino, CA) and 2 of the Dyna® type (Dyna Dental Engineering b.v. Robouw, The Netherlands). Fractured implant length ranged from 10-15 mm, while the diameter was 3.75 mm in almost all cases (n = 20), versus 4 mm in a single case.

Males predominated over females (15:4), and the mean age was 56.9 years (range 45-81). Most of the fractures (n = 19) corresponded to implant-supported fixed prostheses - 16 with cantilevers of different lengths - while only two fractured implants were supporting overdentures instead of fixed prostheses (Figure 1). The great majority of fractured implants (80.9%) were located in the molar and premolar regions: 8 in the molar zone, 9 in the premolar region, and 4 in the canine area. Most implants fractured within 3-4 years after loading (Figure 2). Most patients with implant fracture (83%) presented bruxism.

As to the management approach adopted, 17 fractured implants (81%) were removed entirely with the help of explantation trephines. In four of these cases no further implant placement proved necessary, while in 8 cases additional implants were placed in the same surgical

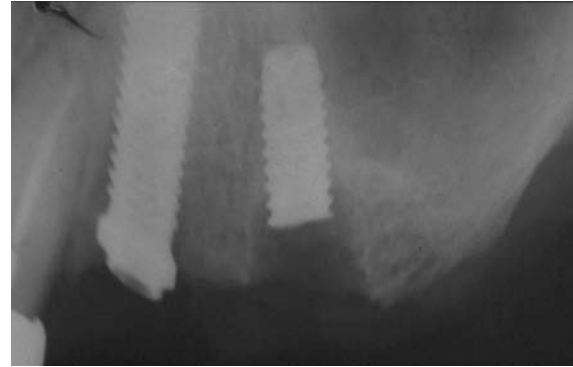

Fig. 1. Implant fracture (Case 12).

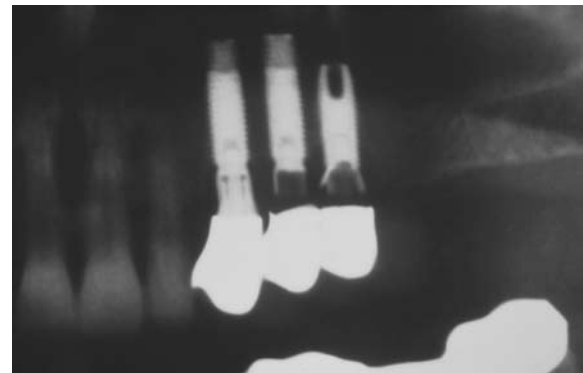

Fig. 3. Fixed prostheses supported over Core-Ven® implants (Case 1).

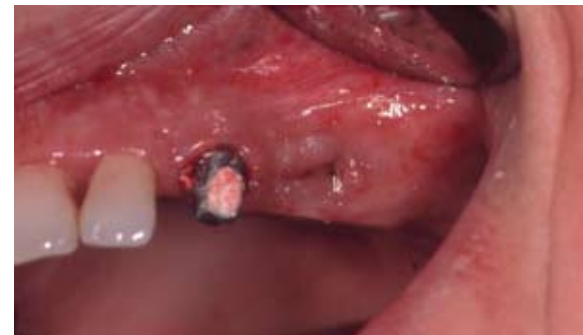

Fig. 4. Fracture of the two distal implants (Case 1).

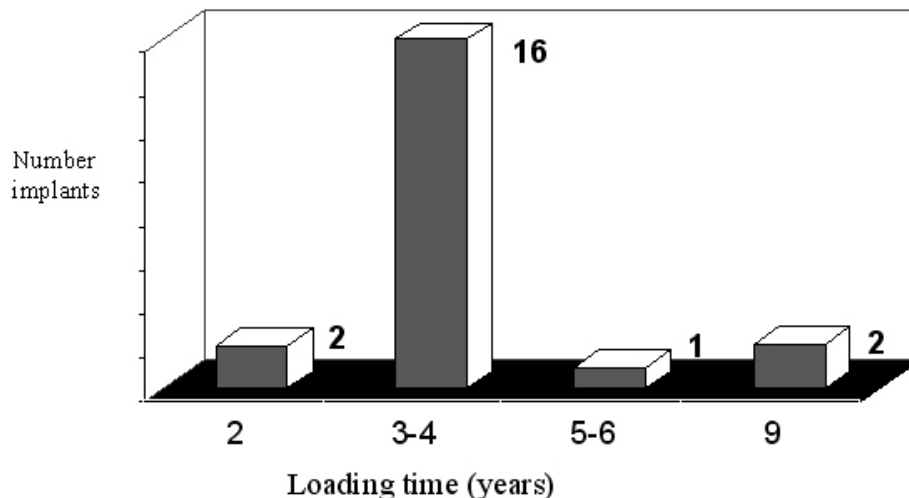


Fig. 2. Loading time to implant fracture.

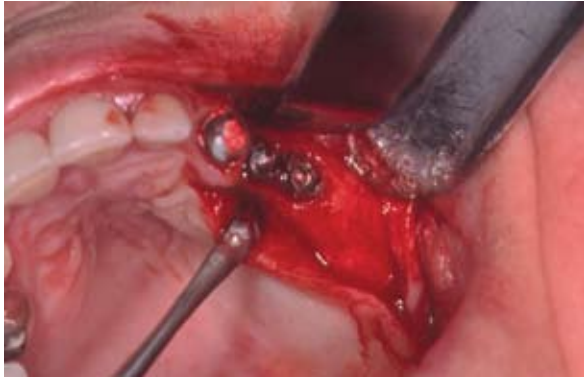

Fig. 5. Clinical view following bridge removal (Case 1).

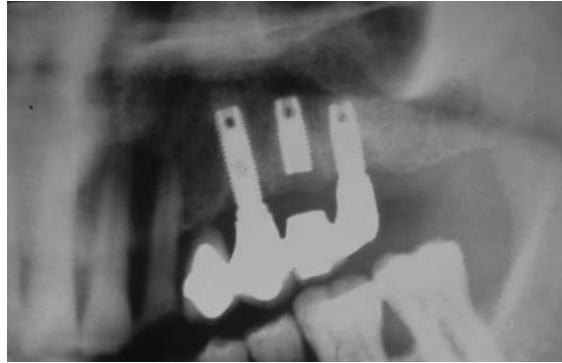


Fig. 9. New prosthodontic rehabilitation (Case 1).



Fig. 6. Surgical view prior to trephine removal of the fractured implants (Case 1).

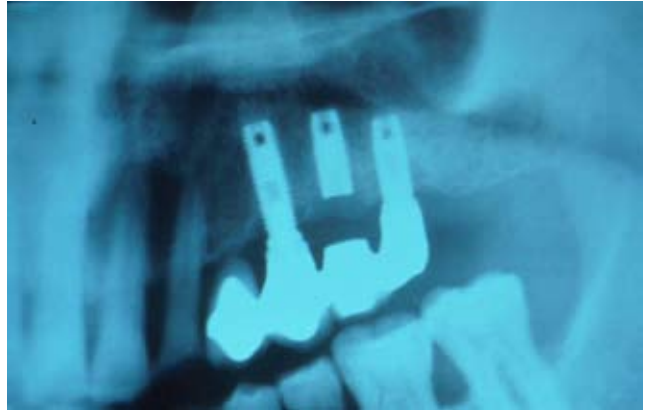

Fig. 10. Implant-supported fixed prosthesis. Apical portion of the fractured implant integrated in the maxillary bone.

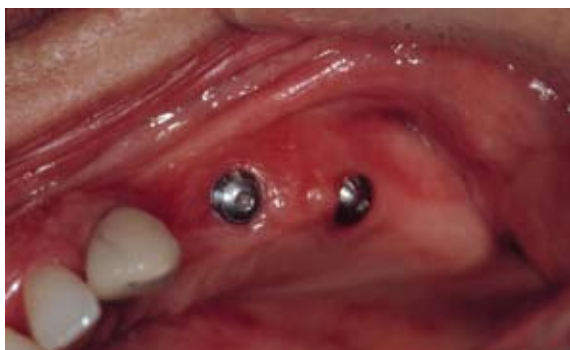

Fig. 7. Explanted implants. Note the bone bound to the implant surface (Case 1).

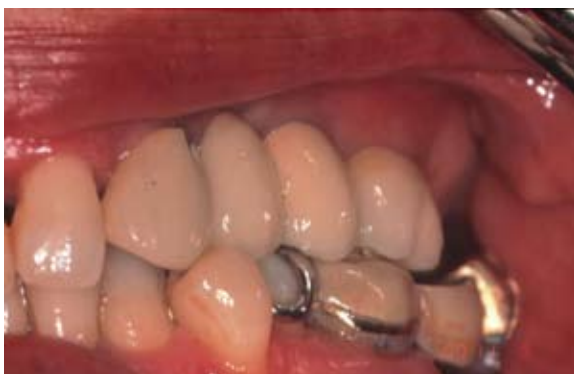

Fig. 8. Two Straumann AG® implants placed in the same surgical intervention (Case 1).

intervention (Figures 3-9). In the remaining 5 cases, regenerative techniques were used to prepare the bone bed for posterior implant placement.

Four fractured implants were subjected to removal of the coronal portion, leaving the apical component integrated in the maxillary bone (Figure 10). No case was managed by removing the coronal portion of the fractured implant, with posterior rectification of the apical fragment.

Discussion

The incidence of implant fracture in our series was 1.4%. This percentage is in line with the figures reported in the literature, since Pylant et al. (9) have reported an incidence of 0.98%, while Goodacre et al. (10) reported 1.5%.

Although implant fractures are infrequent, it is important to adopt measures to prevent them. In this context, a series of factors should be taken into account, such as implant location, diameter, the type of prosthesis, and the possible existence of parafunctional activity.

Regarding implant location, Rangert et al. (4) reported that 90% of fractured implants are located in the region of the molars and premolars. While this percentage is

slightly greater than our own, it coincides in pointing to an increased prevalence of fractures in this region. Similar observations were made by Balshi (2), who found all implant fractures to occur in the area of the premolars and molars - no distinction being made between the upper and lower maxillas. In our series there were no variations in relation to either jaw.

Another important factor is implant diameter, since 20 of our 21 implants presented a diameter of 3.75 mm. In comparison, only one implant with a diameter of 4 mm suffered fracture, versus none of the larger-diameter implants. Both Eckert et al. (7,17) and Balshi (2) found all fractured implants to measure 3.75 mm in diameter. In this sense, it has been shown that an increase in diameter increases resistance to fracture (12).

Another factor to be taken into account is the type of prosthesis involved. It has been seen that many fractured implants supported fixed prostheses, and most moreover presented cantilevers of different lengths - in coincidence with the observations published by Eckert et al. (7). Possibly the stress and tension transmitted by fixed prostheses to the implants is greater than when removable prostheses are involved. In the same way, the presence of distal cantilevers can also increase the transmission of load and tension to the implants (2,4,10,12,18) - though fracture is also possible in the case of implants supporting fixed prostheses without cantilevers, as seen in our study, since 10% of the fractured implants supporting fixed prostheses presented no extension pontics.

The existence of occlusal parafunctional activity such as bruxism has been described as an etiological factor that generates mechanical overload directly related to implant fracture (2,4,12). This was supported by the findings in our own series of patients, since 83% of the fractured implants corresponded to patients diagnosed with bruxism. Balshi (2) recorded an even greater incidence of parafunction. In effect, a full 100% of the implant fractures reported by this author corresponded to patients with bruxism.

In the event of implant fracture, three possible solutions have been described (2,10,12):

(a) Complete fractured implant removal with explantation trephines. The different commercial sources offer explantation trephines specifically adapted to the dimensions of their respective implants. Once the fractured implant has been completely removed, a new implant can be placed in the same surgical bed, or elsewhere. If the aim is to place a new implant in the same location, the external diameter of the explantation trephine must be taken into account, in order to insert an implant with a larger diameter and thus ensure primary stability.

(b) Another solution is removal of the coronal component of the fractured implant, leaving the remnant apical fragment integrated in the bone. If no further implants need to be placed, the prosthesis can be modified to ensure adequate fitting in the absence of the fractured implant.

If additional implants prove necessary, they can be placed elsewhere in accordance to the existing anatomical possibilities.

(c) Finally, a third option is removal of the coronal portion of the fractured implant with the purpose of mounting a new transepithelial abutment. Nobel Biocare® (Göteborg, Sweden) offers a kit for this purpose, including a rotary instrument to smoothen the fracture edges, and an instrument for working new internal threading for the implant.

Of the different management options, we consider complete removal of the fractured implant to be the treatment of choice. Accordingly, most of our cases (81%) were subjected to complete fractured implant removal.

The most important concern is the prevention of fracture. A number of planning and prosthodontic measures must be adopted in this sense. The planning measures include the placement of a larger number of implants, and of larger diameter, in the region of the premolars and molars. In this context, a larger number of implants, and occlusal splints, are indicated in patients with parafunctional habits.

Regarding the prosthodontic measures, occlusion must be optimized in order to achieve adequate occlusal contacts and avoid undesired forces.

It is important to know and apply the measures required to prevent implant fracture, and to seek the best individualized solution for each case - though complete implant removal is usually the treatment of choice.

References

1. Tolman DE, Laney WR. Tissue-integrated prosthesis complications. *Int J Oral Maxillofac Implants.* 1992 Winter;7(4):477-84.
2. Balshi TJ. An analysis and management of fractured implants: a clinical report. *Int J Oral Maxillofac Implants.* 1996 Sep-Oct;11(5):660-6.
3. Jemt T, Lekholm U. Oral implant treatment in posterior partially edentulous jaws: a 5-year follow-up report. *Int J Oral Maxillofac Implants.* 1993;8(6):635-40.
4. Rangert B, Krogh PH, Langer B, Van Roekel N. Bending overload and implant fracture: a retrospective clinical analysis. *Int J Oral Maxillofac Implants.* 1995 May-Jun;10(3):326-34.
5. Naert I, Quirynen M, Van Steenberghe D, Darius P. A study of 589 consecutive implants supporting complete fixed prostheses. Part II: Prosthetic aspects. *J Prosthet Dent.* 1992 Dec;68(6):949-56.
6. Gunne J, Jemt T, Lindén B. Implant treatment in partially edentulous patients: a report on prostheses after 3 years. *Int J Prosthodont.* 1994 Mar-Apr;7(2):143-8.
7. Eckert SE, Meraw SJ, Cal E, Ow RK. Analysis of incidence and associated factors with fractured implants: a retrospective study. *Int J Oral Maxillofac Implants.* 2000 Sep-Oct;15(5):662-7.
8. Lekholm U, van Steenberghe D, Herrmann I, Bolender C, Folmer T, Gumme J et al. Osseointegrated implants in the treatment of partially edentulous jaws. A prospective 5-year multicenter study. *Int J Oral Maxillofac Implant* 1994; 9: 627-35.
9. Pylant T, Triplett RG, Key MC, Brunsvold MA. A retrospective evaluation of endosseous titanium implants in the partially edentulous patient. *Int J Oral Maxillofac Implants.* 1992 Summer;7(2):195-202.
10. Goodacre CJ, Kan JY, Rungcharassaeng K. Clinical complications of osseointegrated implants. *J Prosthet Dent.* 1999 May;81(5):537-52.
11. Piattelli A, Scarano A, Piattelli M. Histologic observations on 230 retrieved dental implants: 8 years' experience (1989-1996). *J Periodontol.* 1998 Feb;69(2):178-84.

12. Piattelli A, Scarano A, Piattelli M, Vaia E, Matarasso S. Hollow implants retrieved for fracture: a light and scanning electron microscope analysis of 4 cases. *J Periodontol*. 1998 Feb;69(2):185-9.
13. Brunel G, Armand S, Miller N, Rue J. Histologic analysis of a fractured implant: a case report. *Int J Periodontics Restorative Dent*. 2000 Oct;20(5):520-6.
14. Flanagan D. External and occlusal trauma to dental implants and a case report. *Dent Traumatol*. 2003 Jun;19(3):160-4.
15. Sánchez-Gárces MA, Gay-Escoda C. Periimplantitis. *Med Oral Patol Oral Cir Bucal*. 2004;9 Suppl:69-74; 63-9.
16. Uribe R, Peñarrocha M, Sanchis JM, García O. Marginal peri-implantitis due to occlusal overload. A case report. *Med Oral*. 2004 Mar-Apr;9(2):160-2, 159-60.
17. Eckert SE, Wollan PC. Retrospective review of 1170 endosseous implants placed in partially edentulous jaws. *J Prosthet Dent*. 1998 Apr;79(4):415-21.
18. Niznick GA. Bending overload and implant fracture: a retrospective clinical analysis. *Int J Oral Maxillofac Implants*. 1996 Jul-Aug;11(4):431-2.