

## Study of available bone for interforaminal implant treatment using cone-beam computed tomography

Cristina Madrigal, Ricardo Ortega, Cristina Meniz, Juan López-Quiles

Associate Professor, Department of Medicine and Oral Surgery, Faculty of Odontology, Universidad Complutense de Madrid

### Correspondence:

Dr. Cristina Madrigal

José Ortega y Gasset, 54

28006 Madrid

E-mail: [crismadrigalmp@hotmail.com](mailto:crismadrigalmp@hotmail.com)

Received: 07/01/2007

Accepted: 02/04/2008

### Indexed in:

-Index Medicus / MEDLINE / PubMed  
-EMBASE, Excerpta Medica  
-SCOPUS  
-Índice Médico Español  
-IBCS

Madrigal C, Ortega R, Meniz C, López-Quiles J. Study of available bone for interforaminal implant treatment using cone-beam computed tomography. *Med Oral Patol Oral Cir Bucal*. 2008 May;13(5):E307-12.

© Medicina Oral S. L. C.I.F. B 96689336 - ISSN 1698-6946

<http://www.medicinaoral.com/medoralfree01/v13i5/medoralv13i5p307.pdf>

### Abstract

**Objectives:** To analyze the availability of bone in the interforaminal region and to demonstrate the variation in diagnosis between panoramic x-ray and cone-beam computed tomography (CBCT).

**Material and methods:** In 50 patients and in 5 areas of each, a series of parameters concerning available bone were measured on both the panoramic and the CT images.

**Results:** Panoramic images underestimate the vertical and horizontal measurements when compared with CBCT. Regarding implant treatment, the interforaminal region presents the same remaining bone height throughout its full extent, the correlation between one side of the midline and the other was highly significant for all the parameters studied, and 20% of the sample showed some buccal and/or lingual concavity.

**Conclusion:** Cone-beam CT is an advantageous system for interforaminal implant treatment planning, especially since the reported radiation dose is minimal and geometric accuracy is very high.

**Key words:** Cone-beam computed tomography, implant planning, mental foramen, bone morphology.

### Introduction

In implantology of the interforaminal region, in addition to anatomical knowledge, it is essential to have adequate diagnostic methods available to accurately assess the grade of resorption of the alveolar ridge and its angulation, the bone quality, location of the mental foramen, mental loop, and incisive canals, or the presence of any bone pathology (1-4). With this information, iatrogeny such as dehiscences or bone fenestrations, mandibular fractures, temporary or permanent lesions to the inferior dental or mental nerve, and even perforations of the lingual cortical during surgery causing hemorrhage in the floor of the mouth can be prevented (3,5).

Image explorations constitute the final step in diagnosis and treatment planning. However, since the information derived from conventional radiographic techniques is very limited, in order to correctly and accurately characterize

edentulous bone, in all its dimensions, it is necessary to call upon tomographic explorations (6-9).

Computed tomography (CT) allows the three-dimensional evaluation of any area, providing very detailed, high-contrast, high-resolution full-size images, without overlapping. Thus, CT is more precise than any other technique in locating anatomical structures and pathologic processes, in visualizing abnormalities of the maxilla and mandibula, and in the measurement of residual bone (10,11).

Basically, three types of CT units or scanners presently exist: the traditional scanner, the helicoid or volumetric scanner, and the cone-beam scanner (CBCT). The traditional scanner has a beam of x-rays in fan shape that sweeps the volume under study in layers of previously programmed thickness. The radiation source rotates 360° around the patient as many times as is necessary to complete the acquisition layers to study the full height of the volume,

achieving its representation by summing the information of the contiguous layers (8,12).

The helicoid or spiral scanner, also known as the volumetric or continuous rotation scanner in fact goes one step further than the traditional scanner. The x-ray tube turns continuously, emitting radiation while the patient's table moves in a continuous synchronized manner. In this way, the data acquisition is carried out by describing a spiral until completing the selected anatomical volume (12).

In the cone-beam scanner (CBCT) the beam of x-rays has a pyramid or cone formation centered in the detector, in such a way that with each shot it picks up information not of one layer, but of the whole volume under study. The source-detector system assembly makes a complete 360° rotation around the patient's head, while the patient remains stationary (8,13,14).

The objectives of this study were to analyze the distance between both mental foramina in order to establish the space available for implant, and to check the symmetry of the resorption pattern in this area. Furthermore, to demonstrate the variations in diagnosing ridge dimensions and locating anatomical structures of the interforaminal area through panoramic x-ray and CBCT in edentulous patients prior to dental implant treatment.

**Patients and Method**

Fifty patients (14 male and 36 female), partially or completely edentulous in the anterior mandibular area, were

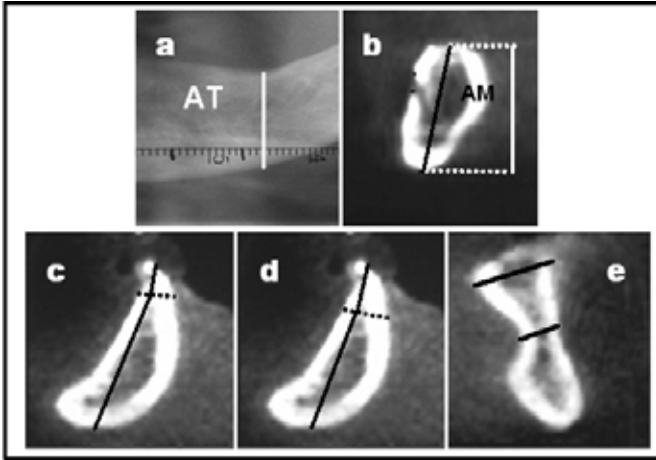
included in the study. For each patient, a panoramic x-ray, Ortofox (Siemens AG, Munich, Germany), and a CBCT, NewTom 9000 (QR s.r.l., Verona, Italy) was carried out. To make measurements on the images, a pair of compasses, a digital gauge calibrated in hundredths of millimeters, and an acetate template designed by Dr. R. Ortega were used. The acetate template facilitates reading in real terms the measurements obtained on the panoramic x-rays and corrects the horizontal and vertical magnification of the technique.

For each registered case, five locations were determined for study on the panoramic x-ray and on the cross-sectional and axial images of the CBCT: the midline, a parallel line at one centimeter to each side of the midline, and two other lines that passed through the center of the mental foramina, whenever it was possible to locate them. In these five areas a series of parameters were measured relative to the bone available for the possible insertion of implants listed in Table 1 and represented in Figure 1.

For statistical analysis, a basic statistical test (Means, univariate and frequency procedure) was used for the sample descriptions; contrast hypothesis for the mean; the ranges and signs test (univariate procedure) for the comparison of two quantitative variables; and the Cohen's kappa and Kappa generalized statistical test to measure the agreement between two qualitative variables. The confidence level was 95% (p < 0.05).

Table 1. Parameters studied.

<b>MENTAL FORAMEN TO MIDLINE DISTANCE</b>	Shortest distance between the most mesial point of the mental foramen and the mandibular midline.
<b>DISTANCE BETWEEN MENTAL FORAMINA</b>	Minimum distance between the most mesial points of both mental foramina.
<b>TOTAL BONE HEIGHT (TBH)</b>	Distances between the most coronal point of the crest and the most caudal point of the basis mandibulae measured on the vertical plane.
<b>MAXIMUM BONE HEIGHT (MBH))</b>	Maximum distance between the most coronal point of the upper cortex and the most caudal point of the basis mandibulae cortex measured on the axial axis of the border.
<b>REDUCING OSTEOTOMY to 5 mm Ø</b>	Distance from the most coronal point of the crest to the line perpendicular to the axial axis of the 5 mm border.
<b>REDUCING OSTEOTOMY to 6 mm Ø</b>	Distance from the most coronal point of the crest to the line perpendicular to the axial axis of the 6 mm border.
<b>IMPLANT HEIGHT I</b>	Difference between the MBH and the reducing osteotomy to 5 mm, this is, the bone height remaining after leveling the ridge to 5 mm thickness.
<b>IMPLANT HEIGHT II</b>	Difference between the MBH and the reducing osteotomy to 6 mm, this is, the bone height remaining after leveling the ridge to 6 mm thickness.
<b>MAXIMUM WIDTH (WMax)</b>	Maximum bone width of the ridge measured on a line perpendicular to the axial axis of the ridge.
<b>MINIMUM WIDTH (WMin)</b>	Minimum bone width of the ridge measured on a line perpendicular to the axial axis of the ridge, where this is less than 6 mm.



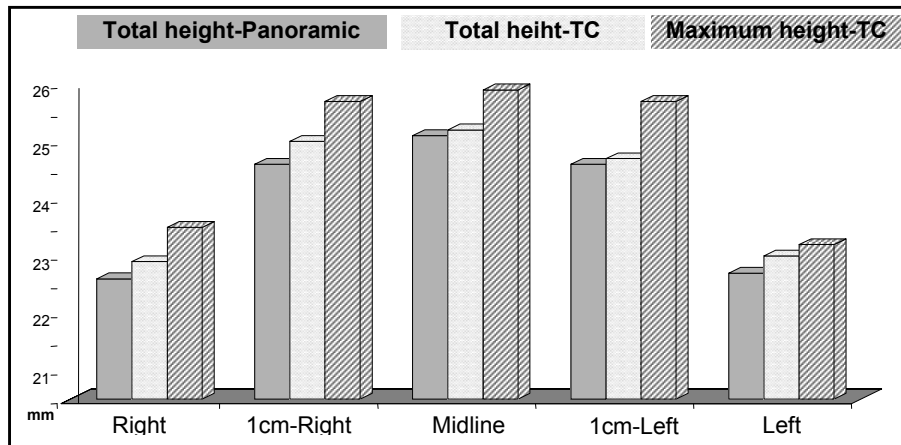
**Fig. 1.** Scheme of the studied parameters: (a) Total bone height (TBH) measured on the panoramic x-ray. (b) Maximum bone height (MBH) and total bone height (TBH) on the transversal slices of CT. (c) Reducing osteotomy to 5 mm and implant height I. (d) Reducing osteotomy to 6 mm and implant height II. (e) Maximum and minimum width.

**Results**

The distance between the mental foramen and the midline could only be evaluated on the panoramic x-ray of 36 patients, since in the remainder either one or both of the mental foramina could not be identified. There were no statistically significant differences between the distance of one mental foramen and the other to the midline, both in panoramic x-ray and in CBCT ( $p > 0.05$ ), therefore, the foramen are practically equidistant of the midline with a variation of  $0.5 \pm 2.1$  mm on the panoramic x-ray and  $0.2 \pm 1.4$  mm on the CBCT (Table 2).

The distance between both mental foramina measured on the panoramic x-ray was  $41.9 \pm 7.1$  mm and  $46.5 \pm 5$  mm on the CBCT. This difference between both explorations for both the mean and standard deviation was statistically significant ( $p = 0.009, < 0.05$ ) (Table 2).

The mean and standard deviation values both for the total bone height (TBH), and for the maximum bone height (MBH), are shown in Table 3 and in Figure 2. The highest values are found at the midline, followed by the areas at 1 cm either side, while the lowest were found in the emergent areas of the mental foramen.



**Fig. 2.** Distribution of the total bone height and maximum bone height values.

**Table 2.** Mean, standard deviation and maximum and minimum values of the distance from the mental foramen to the midline and the distance between both foramina, measured using the two techniques.

	Panoramic				CT			
	Mean	SD	Max.	Min.	Mean	SD	Max.	Min.
<b>DISTANCE FROM RIGHT MENTAL FORAMEN TO MIDLINE.</b>	21.3	3.5	29	13	23	2.8	28	16
<b>DISTANCE FROM LEFT MENTAL FORAMEN TO MIDLINE.</b>	21	3.9	27.5	11.5	23	2.4	29	18
<b>DISTANCE BETWEEN BOTH FORAMINA</b>	41.9	7.1	56.5	24.5	46.5	5	58	34

**Table 3.** Distribution in mm of the total bone height (TBH), the maximum bone height (MBH), the reducing osteotomy to 5 mm and 6 mm and implant heights I and II.

		<b>Right</b>	<b>1cm-Right</b>	<b>Line 1/2</b>	<b>1cm-Left</b>	<b>Left</b>
<b>TBH</b>	<b>Panoramic</b>	22.6 ± 6	24.6 ± 5.5	25.1 ± 5.2	24.6 ± 5.5	22.7 ± 5.5
	<b>CBCT</b>	22.9 ± 5.3	25 ± 4.7	25.2 ± 4.9	24.7 ± 5.1	23 ± 4.9
<b>MAXIMUM HEIGHT (MBH)</b>		23.5 ± 5.4	25.7 ± 4.7	25.9 ± 4.8	25.7 ± 4	23.2 ± 5.1
<b>REDUCING OSTEOTOMY to 5 mm</b>		2 ± 1.5	2.6 ± 2.3	3.5 ± 2.2	2.8 ± 2.3	2.3 ± 1.8
<b>PERCENTAGE OSTEOTOMY to 5 mm</b>		8.5%	10.1%	13.5%	10.9%	9.9%
<b>IMPLANT HEIGHT I</b>		21.5 ± 5.6	23.1 ± 4.7	22.5 ± 4.3	22.8 ± 5	20.9 ± 5.4
<b>REDUCING OSTEOTOMY to 6 mm</b>		2.9 ± 1.8	4 ± 3.1	4.8 ± 3	4.3 ± 3.3	3 ± 1.9
<b>PERCENTAGE OSTEOTOMY to 6 mm</b>		12.3%	15.7%	18.5%	16.7%	12.9%
<b>IMPLANT HEIGHT II</b>		20.5 ± 5.6	21.7 ± 4.8	21.1 ± 4.3	21.3 ± 5.2	20.1 ± 5.3

The values obtained for the 5 and 6 mm osteotomy reduction are expressed in Table 3. This is the amount of bone tissue necessary to be removed for the crest to have a buccolingual diameter of 5 and 6 mm. Also the values obtained for the residual bone height that would result after leveling the crest to 5 mm in thickness (implant height I) and after leveling the crest up to a 6 mm buccolingual diameter (implant height II) are shown.

Regarding the ridge maximum width, this was thicker at the midline ( $13 \pm 2$  mm) than in the other areas. This is due to the presence at this level of the mental apophysis. As for the minimum width, only those cross sections where, due to either lingual or vestibular concavity, the ridge thickness narrowed to less than 6 mm were registered. A total of 5 oblique cuts with buccal narrowing and 8 ridges with lingual narrowing were registered.

## Discussion

Despite in some cases exist the tendency to carry out only a panoramic x-ray of the interforaminal area, it has been demonstrated that the vertical dimension for implant insertion is determined incorrectly when using only this exploration. The risk of diagnostic error also increases considerably in edentulous mandibles with a higher degree of bone resorption (7,8,15).

With the objective of radiographically evaluating available mandibular bone, Bolin et al. (15) compared measurements obtained by panoramic x-ray and helicoid tomo-

graphy in 100 patients. The mean height in the panoramic x-ray was greater than in the tomography, the differences being statistically significant. Considerable dispersion was registered in their linear regression analysis, indicating the uncertainty involved in estimating available bone using only a panoramic x-ray.

CT is an appropriate exploration since it provides very fine sections with a high-quality image, allowing very precise, direct measurement; it gives information on bone quality, exploration time is reduced and the different images can be related with each other (7,11,12).

The first CBCT unit was marketed under the name of NewTom 9000 (QR s.r.l., Verona, Italy) and was developed basically for preimplant diagnostic assessment since it was only able to study a reduced area of the head (15x15x15 cm) (16). It was designed with the purpose of improving on the limitations of other equipment: the high radiation doses, the time taken to carry out the exploration and the cost of the equipment. Due to their technical properties, these CBCT units are very high speed and normal functions require less technology, resulting in lower production and maintenance costs (8,13,17).

Furthermore, the NewTom unit has a property called "intelligent beam", thanks to which, it automatically selects the initial intensity of the beam of rays according to the size of the patient, and even varies the intensity during acquisition in function of the density of tissue crossed, thus limiting absorbed radiation doses (16,18,19).

The geometric precision of the CBCT (NewTom 9000), essential in implant treatment planning, was examined by Mozzo et al. (16) in an *in vitro* study. The accuracy of the lineal measurements was also demonstrated by Kobayashi et al. (20) and Lascala et al. (21) in their respective studies. In addition, Marmulla et al. (22) in their study registered neither geometric deviation nor lineal distortions in their measurements, concluding that the NewTom 9000 unit generates images in which geometric distortion is lower than the image resolution.

Subsequently, new CBCT equipment came onto the market (NewTom 3G - QR s.r.l., Verona, Italy; DentoCATTM - Xoran Technologies, Michigan, USA; Siremobil Iso-C3D - Siemens, Munich, Germany and CB MercuRayTM - Hitachi, Tokyo, Japan) with the aim of improving upon the technical characteristics and software, and of developing higher resolution images without the need to increase radiation doses, as well as reducing the size of the apparatus and lowering the purchase price (2, 8, 9, 17, 23, 24).

Implant surgery in the space between the mental foramina involves muco-periosteal detachment, bone remodeling and insertion of two to six implants. It is therefore important to exactly locate the mental nerve, its exit foramen and loop before treatment (25, 26), as well as determining the availability and quality of bone for the implants. It should be remembered that on many occasions the most distal implant should be located as close as possible to the mental neurovascular bundle, in order to extend the prosthesis distal cantilever as far as is biomechanically possible (4).

A study by Bavitz et al. (26) on cadavers concluded that a lesion of the mental neurovascular bundle can be avoided if the space between the anterior border of the foramen and the last implant is greater than 1 mm. However, Wismeijer et al. (25), in their prospective study of 110 edentulous patients, registered sensorial alterations in the lower lip in 7% at 16 months of the operation, even when leaving a 3 mm margin.

It should be kept in mind that it is not always possible to partially or totally appreciate the mental foramina, especially the loop, in the panoramic x-rays (25), since their visualization depends on the technical specifications of the equipment, the image quality, the patient's bone pattern and the position of the mandible during the exploration. In 21% of cases in the present study the mental foramina could not be identified on the panoramic x-ray, however, it was possible in all the cases to identify them in the oblique cuts of the CBCT, except in two rather unclear images due to the presence of implants.

The panoramic x-ray evaluated the distance between both mental foramina (the space available for the required implants) by default, therefore measuring a greater length than the CBCT ( $46.5 \pm 5$  mm). This statistically significant difference between both explorations could be because the image of the mental foramen on the panoramic x-ray does not always correspond to the structure itself.

The values obtained for both TBH and MBH demonstrate that the total height measured in the vertical plane in the panoramic x-ray is equal to that measured in the CT images. From the values registered for the total height, it can be concluded that the orthopantomography made with the Ortofox® unit underestimated the vertical measurements, although the differences with respect to the CBCT were not significant in any area.

A study carried out by Lam et al. (27) compared the measurements obtained by CT and those obtained with panoramic x-ray in patients under preimplant evaluation. Contrary to our results, in the majority of their cases the bone height values were greater for measurements obtained from the panoramic x-rays, with statistically significant differences. The biggest discrepancies between the two techniques were registered in regions with less than 15 mm of remaining bone.

Although authors do not agree regarding minimum space, either for implant to remaining lingual or vestibular cortical bone, or between adjacent implants, or next to the periodontia of adjacent teeth, it would seem logical to believe that small thicknesses of bone tissue are not viable and resorb or necrose, thus compromising osteointegration. In the lingual and vestibular slopes, it is advisable to leave at least 1 to 2 mm of bone tissue, in the same way that it is convenient to leave a minimum distance of between 1 and 3 mm with respect to critical anatomical structures (28).

According to Bolin et al. (29), since the different implant systems vary between 3 and 5 mm in diameter, then the buccolingual dimension of the alveolar bone should be from 5 to 6 mm. In this study it was observed that for a buccolingual diameter of 5 mm, the necessary reducing osteotomy is equal to 13.5% of the maximum height, 10.5% at 1 cm each side of the midline and 9.2% in the distal areas. However, in order to leave the alveolar ridge with a thickness 6 mm, it would be necessary to eliminate 18.5% of the maximum height at the midline, 16.2% at 1 cm each side and 12.6% in the distal areas.

Although the ridge height was higher at the midline, once the crest is leveled to a thickness 5 mm at the midline and at 1 cm to each side, the residual height (implant height I) is practically the same, although greater than at the ends. However, when leaving an alveolar process thickness of 6 mm, the available bone height (implant height II) will be very similar throughout the whole interforaminal region ( $21 \pm 5.1$  mm). Concluding that, implantologically, the anterior mandibular region presents the same height of available bone throughout its full extent.

With regard to minimum width, 20% of the sample presented some narrowing or fossa in one or more of the areas studied, either vestibular or lingual, that left the residual ridge with a diameter less than 6 mm, possibly compromising the insertion of implants and contributing to an increased risk of perforating the cortical bone (3).

For all the studied parameters, the correlation at one side and the other of the mandibular midline was very significant; there is, therefore, symmetry in the location of anatomical structures and in the pattern of ridge resorption.

In conclusion, it is recommended to carry out a panoramic x-ray on all prospective implant patients in order to globally explore both maxilla and mandibula, to discount any possible pathology and to classify the case; and a CT in order to accurately characterize the edentulous bone in three-dimensions, and locate any possible deficit. The optimum image quality, the excellent geometric accuracy and the low radiation dose, together with the ease of handling and the low purchase and maintenance cost (1,2,9,30) make CBCT a suitable system for implant treatment planning of the anterior mandibular area.

## References

- Sato S, Arai Y, Shinoda K, Ito K. Clinical application of a new cone-beam computerized tomography system to assess multiple two-dimensional images for the preoperative treatment planning of maxillary implants: case reports. *Quintessence Int.* 2004 Jul-Aug;35(7):525-8.
- Schulze D, Heiland M, Blake F, Rother U, Schmelzle R. Evaluation of quality of reformatted images from two cone-beam computed tomographic systems. *J Craniomaxillofac Surg.* 2005 Feb;33(1):19-23.
- Tepper G, Hofschneider UB, Gahleitner A, Ulm C. Computed tomographic diagnosis and localization of bone canals in the mandibular interforaminal region for prevention of bleeding complications during implant surgery. *Int J Oral Maxillofac Implants.* 2001 Jan-Feb;16(1):68-72.
- Bou Serhal C, Jacobs R, Flygare L, Quirynen M, Van Steenberghe D. Perioperative validation of localisation of the mental foramen. *Dentomaxillofac Radiol.* 2002 Jan;31(1):39-43.
- Ten Bruggenkate CM, Krekeler G, Kraaijenhagen HA, Foitzik C, Oosterbeek HS. Hemorrhage of the floor of the mouth resulting from lingual perforation during implant placement: a clinical report. *Int J Oral Maxillofac Implants.* 1993;8(3):329-34.
- Reddy MS, Mayfield-Donahoo T, Vandervan FJ, Jeffcoat MK. A comparison of the diagnostic advantages of panoramic radiography and computed tomography scanning for placement of root form dental implants. *Clin Oral Implants Res.* 1994 Dec;5(4):229-38.
- Thunthy KH, Yeaton WR, Nasr HF. An illustrative study of the role of tomograms for the placement of dental implants. *J Oral Implantol.* 2003;29(2):91-5.
- Sukovic P. Cone beam computed tomography in craniofacial imaging. *Orthod Craniofac Res.* 2003;6 Suppl 1:31-6.
- Araki K, Maki K, Seki K, Sakamaki K, Harata Y, Sakaino R, et al. Characteristics of a newly developed dentomaxillofacial X-ray cone beam CT scanner (CB MercuRay): system configuration and physical properties. *Dentomaxillofac Radiol.* 2004 Jan;33(1):51-9.
- Mupparapu M, Singer SR. Implant imaging for the dentist. *J Can Dent Assoc.* 2004 Jan;70(1):32.
- Cucchiara R, Franchini F, Lamma A, Lamma E, Sansoni T, Sarti E. Enhancing implant surgery planning via computerized image processing. *Int J Comput Dent.* 2001 Jan;4(1):9-24.
- Hu H. Multi-slice helical CT: scan and reconstruction. *Med Phys.* 1999 Jan;26(1):5-18.
- Mah JK, Danforth RA, Bumann A, Hatcher D. Radiation absorbed in maxillofacial imaging with a new dental computed tomography device. *Oral Surg Oral Med Oral Pathol Oral Radiol Endod.* 2003 Oct;96(4):508-13.
- Arai Y, Tammisalo E, Iwai K, Hashimoto K, Shinoda K. Development of a compact computed tomographic apparatus for dental use. *Dentomaxillofac Radiol.* 1999 Jul;28(4):245-8.
- Bolin A, Eliasson S, Von Beetzen M, Jansson L. Radiographic evaluation of mandibular posterior implant sites: correlation between panoramic and tomographic determinations. *Clin Oral Implants Res.* 1996 Dec;7(4):354-9.
- Mozzo P, Procacci C, Tacconi A, Martini PT, Andreis IA. A new volumetric CT machine for dental imaging based on the cone-beam technique: preliminary results. *Eur Radiol.* 1998;8(9):1558-64.
- Yamamoto K, Ueno K, Seo K, Shinohara D. Development of dentomaxillofacial cone beam X-ray computed tomography system. *Orthod Craniofac Res.* 2003;6 Suppl 1:160-2.
- Ludlow JB, Davies-Ludlow LE, Brooks SL. Dosimetry of two extraoral direct digital imaging devices: NewTom cone beam CT and Orthophos Plus DS panoramic unit. *Dentomaxillofac Radiol.* 2003 Jul;32(4):229-34.
- Bianchi SD, Lojacano A. 2D and 3D images generated by cone beam computed tomography (CBCT) for dentomaxillofacial investigations. In: Lemke HU, Vannier MW, Inamura K, Farman A editors. Elsevier Science BV 1998:792-7.
- Kobayashi K, Shimoda S, Nakagawa Y, Yamamoto A. Accuracy in measurement of distance using limited cone-beam computerized tomography. *Int J Oral Maxillofac Implants.* 2004 Mar-Apr;19(2):228-31.
- Lascaia CA, Panella J, Marques MM. Analysis of the accuracy of linear measurements obtained by cone beam computed tomography (CBCT-NewTom). *Dentomaxillofac Radiol.* 2004 Sep;33(5):291-4.
- Marmulla R, Wörtche R, Mühling J, Hassfeld S. Geometric accuracy of the NewTom 9000 Cone Beam CT. *Dentomaxillofac Radiol.* 2005 Jan;34(1):28-31.
- Heiland M, Schmelzle R, Hebecker A, Schulze D. Intraoperative 3D imaging of the facial skeleton using the SIREMOBIL Iso-C3D. *Dentomaxillofac Radiol.* 2004 Mar;33(2):130-2.
- Schulze D, Heiland M, Thurmann H, Adam G. Radiation exposure during midfacial imaging using 4- and 16-slice computed tomography, cone beam computed tomography systems and conventional radiography. *Dentomaxillofac Radiol.* 2004 Mar;33(2):83-6.
- Wismeijer D, Van Waas MA, Vermeeren JI, Kalk W. Patients' perception of sensory disturbances of the mental nerve before and after implant surgery: a prospective study of 110 patients. *Br J Oral Maxillofac Surg.* 1997 Aug;35(4):254-9.
- Bavitz JB, Harn SD, Hansen CA, Lang M. An anatomical study of mental neurovascular bundle-implant relationships. *Int J Oral Maxillofac Implants.* 1993;8(5):563-7.
- Lam EW, Ruprecht A, Yang J. Comparison of two-dimensional orthoradially reformatted computed tomography and panoramic radiography for dental implant treatment planning. *J Prosthet Dent.* 1995 Jul;74(1):42-6.
- Quirynen M, Mraiwa N, Van Steenberghe D, Jacobs R. Morphology and dimensions of the mandibular jaw bone in the interforaminal region in patients requiring implants in the distal areas. *Clin Oral Implants Res.* 2003 Jun;14(3):280-5.
- Bolin A, Eliasson S. Panoramic and tomographic dimensional determinations for maxillary osseointegrated implants. Comparison of the morphologic information potential of two and three dimensional radiographic systems. *Swed Dent J.* 1995;19(1-2):65-71.
- Winter AA, Pollack AS, Frommer HH, Koenig L. Cone beam volumetric tomography vs. medical CT scanners. *N Y State Dent J.* 2005 Jun-Jul;71(4):28-33.