

Intraosseous mandibular hemangioma. A case report and review of the literature

Guillermo Gómez Oliveira, Alvaro García-Rozado, Ramón Luaces Rey

Oral and Maxillofacial Surgery Department. CHU Juan Canalejo. La Coruña

Correspondence:

Dr. Guillermo Gómez Oliveira
C/Almirante Mourelle 29 2º
15011 La Coruña. Spain
E-mail: ggomoli@hotmail.com

Received: 10/06/2007

Accepted: 06/07/2008

Indexed in:

-Index Medicus / MEDLINE / PubMed
-EMBASE, Excerpta Medica
-SCOPUS
-Indice Médico Español
-IBECs

Gómez-Oliveira G, García-Rozado A, Luaces-Rey R. Intraosseous mandibular hemangioma. A case report and review of the literature. *Med Oral Patol Oral Cir Bucal*. 2008 Aug 1;13(8):E496-8.
© Medicina Oral S. L. C.I.F. B 96689336 - ISSN 1698-6946
<http://www.medicinaoral.com/medoralfree01/v13i8/medoralv13i8p496.pdf>

Abstract

Intraosseous vascular lesions are rare conditions, comprising only 0.5% to 1% of all intraosseous tumors. They mainly occur in the second decade of life especially in women. The most common locations are the vertebral column and skull; nevertheless, the mandible is a quite rare location.

According to the World Health Organization, hemangiomas are benign vasoformative neoplasms of endothelial origin. However, the origin of central hemangioma is debatable. Some authors believe that it is a true neoplasm, whereas others state it is a hamartomatous lesion.

Clinically, the patient may be completely symptom-free or may present discomfort, pulsatile bleeding, bluish discoloration, mobile teeth, derangement of the arch form or accelerated dental exfoliation.

Most frequently radiographic finding is a multilocular radiolucent image with honeycombs or soap bubble appearance. Differential diagnosis includes neoplasms such as ameloblastoma, cystic lesions such as residual cyst, keratocyst and fibro-osseous lesions such as fibrous dysplasia.

There are some therapeutic alternatives, although wide surgical excision remains as the gold standard.

We now present a case report of a 51-year-old woman diagnosed in a mandibular hemangioma. Clinical, radiological and histological features of this unusual tumor are described.

Key words: Hemangioma, intraosseous, embolization, wide surgical excision.

Introduction

Hemangioma is a benign vasoformative neoplasm of endothelial origin (1,2). Its natural course includes a rapid post-natal growth followed by a slow spontaneous regression, which may take even several years (2). It is usually located in soft tissues (1). Intraosseous hemangioma is a quite rare condition, comprising less than 1% of all intraosseous tumors (1,3). It mainly occurs in the vertebral column. Mandible is a very infrequent location although possible (1,3). The female:male ratio is 2:1 and the peak of incidence is between the second and fifth decades of life (1,3).

Its origin is not defined at all. Some authors believe it is a true neoplasm, whereas others state it is a hamartoma resulting from proliferation of intraosseous mesodermal cells that undergo endothelial differentiation (1).

It is usually asymptomatic although may present signs

and symptoms including a slow growing bluish mass, discomfort, pulsatile sensation and mobile teeth (1,3).

Panoramic radiograph, CT – scan and MRI are the most useful radiographic studies. Radiological findings include (3,4):

1. Unilocular rounded lesion, of varying size and appearance, resembling a cyst.
2. Well defined cavity with sclerotic rims and anarchic inner trabeculation.
3. Bone trabeculae radiating from the center to the periphery of the lesion.
4. Honeycombed or sunburst appearance with spindles radiating towards the periphery. This feature is useful to differentiate hemangioma from ameloblastoma.
5. A radiodensity area is possible but represents a quite rare condition.

CT-scan allows clear visualization of cortical involvement while MRI shows blood flow, if present, as well as the relationship with surrounding soft tissues (4).

Differential diagnosis includes (4,5):

- Odontogenic tumours
 - Ameloblastoma. It is defined by histological ameloblastic differentiation and absence of a sunrise radiological image.
 - Mixoma. It presents spindle - cells scattered into a mucoid stroma filled with mucopolysaccharides.
- Cystic lesions
 - Odontogenic cyst. It usually appears in an edentulous area and lacks radiological inner bone trabeculation.
 - Aneurismatic bone cyst, characterized by its fast growth and its bad defined edges filled with liquid in the radiological exploration.
- Fibrous lesions
 - Fibrous dysplasia, is a painful lesion that presents reactive bone formation in a fibrous origin in contradistinction to the moderately remodeled laminar bone of the hemangioma.

In this article, we report the case of a patient diagnosed in a hemangioma with unspecific radiological features and a very infrequent location. The significance of a mandibular hemangioma lies in the proximity of the teeth representing a high risk of bleeding due to any traumatism or extraction attempt.

Case Report

A 51-year-old woman was referred to our consultation by her general dental practitioner for evaluation of a radiolucent area in the right mandible on a panoramic radiograph.

Intraoral examination showed a swelling located in the right mandibular body with soft consistency. There were no other associated symptoms.

A dental panoramic radiograph revealed a 30 x 30 mm unilocular, rounded and well-defined radiolucent image located in the mandible affecting from the right first central incisor to the right second premolar tooth (Figure 1).

Differential diagnosis included radicular cyst, solitary bone cyst, ameloblastoma, myxoma and bone hemangioma. Given these findings a CT facial scan was performed. It revealed a 30 x 17 mm bad-defined lesion with inner bone trabeculation and periostic reaction with cortices expansion of the mandible. The dental roots had no remarkable alterations although the inferior dental canal was wider than normal. The presumption diagnosis was hemangioma (Figure 2).

A FNAC was performed to confirm the diagnosis. It revealed a hematic material with no apparent cellularity. An arteriography was planned but could not be performed because of the small size of the lesion as well as the absence of a well defined nutritional vessel.

Wide surgical excision of the lesion, identification and

ligation of a small nutritional vessel was subsequently performed by means of an intraoral approach under general anesthesia.

The surgical specimen was described macroscopically as a 30-mm bluish and ovaled mass with surgical free margins. Microscopic examination showed a vascular proliferation of congested capillaries, surrounded by normal endothelial cells. There were no atypias or mitotic figures. The histopathologic diagnosis was cavernous hemangioma.

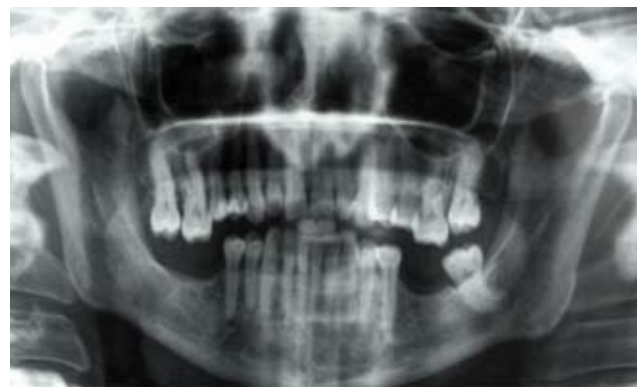

Fig. 1. Panoramic radiograph showing a radiolucent lesion in the right mandible.

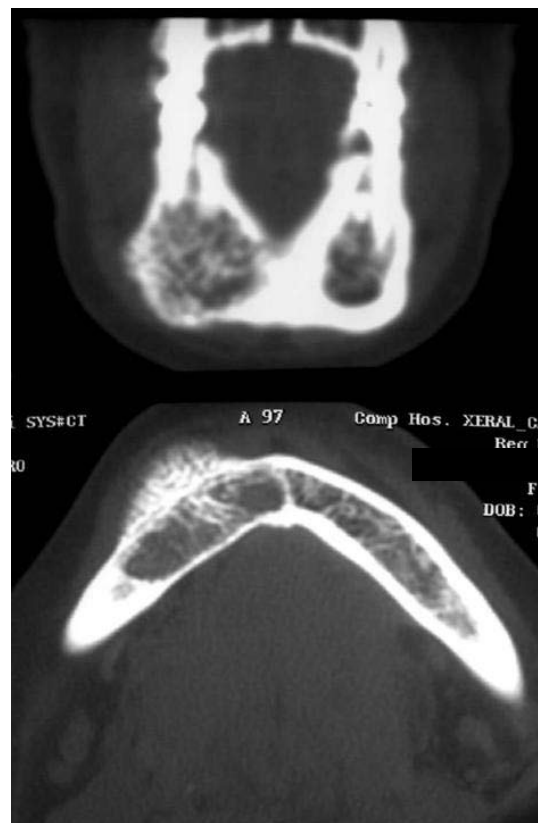


Fig. 2. CT - scan: Coronal (superior) and axial (inferior) mandibular sections. It can be observed the "honeycombed appearance" as well as the cortical bone insuflation. "Sunburst appearance" of the periostium with spindles radiating towards the periphery allows differentiating it from ameloblastoma and cystic odontogenic lesions.

Discussion

The most frequent location of hemangioma is the molar – premolar region (6).

Pathogenesis is still debatable (3) and several theories are postulated. Some authors describe hemangiomas as congenital lesions whereas others believe that the inferior dental canal is the origin of the lesion, based on its widening in the majority of these patients (3,6).

The initial diagnosis is usually complicated because of the absence of symptoms and the unspecific radiological findings (2,3). The last ones may include a multilocular or unilocular radiolucency sometimes associated with a peripheral sclerotic border or a resorption of the neighbouring root teeth (6). CT-scan or MRI are very useful in these cases (2,7).

The CT-scan allows clear visualization of cortical involvement (4,6) and is also useful to define the extension of the hemangioma and its relationship with surrounding soft tissues (3). The classical feature is the “polka-dot” appearance with cortical expansion. Honeycombed appearance and periostic reaction, as in our case, are extremely rare presentations (3,8).

Preoperative arteriography is usually unnecessary because a vascular flow cannot be identified in the majority of the cases (1,3). Nevertheless, it should be performed together with a presurgical embolization in big lesions to minimize the surgical bleeding (2,9).

Biopsy is formally contraindicated because of the high risk of bleeding (2).

There are two types of hemangioma: peripheral and central. Peripheral hemangioma is originated in the periostic vessels that grow into the medullar bone, while central hemangioma is originated into the medullar bone and grow towards the cortical bone (3).

Histologically, hemangioma can be divided into three groups: cavernous, is the most frequent one and is located into the mandible (3), capillary and mixed.

Treatment is indicated only in some conditions: aesthetic disfigurement, repetitive bleeding and palpable mass. Therapeutic alternatives include: surgery, radiotherapy, curettage and embolization (3,9).

Radiotherapy is useful to reduce the tumoral volume. Nevertheless, it has a lot of adverse effects such as damage to the normal adjacent tissues growth, residual scarring and malignization. So, radiotherapy is considered an unacceptable therapeutic option (3).

Simple curettage may lead to an uncontrollable bleeding as well as an incomplete excision of the lesion (3).

Percutaneous embolization has been defended by several authors, although technical risks are greater than benefits obtained (10).

In conclusion, the elective treatment should be a wide excision of the lesion including healthy surrounding bone, as well as ligation of the nutritional vessels, if present (6,9).

Clinical observation is only indicated in two conditions: asymptomatic patients or minimal facial deformity (3).

References

1. Alves S, Junqueira JL, De Oliveira EM, Pieri SS, De Magalhães MH, Dos Santos Pinto D Jr, et al. Condylar hemangioma: report of a case and review of the literature. *Oral Surg Oral Med Oral Pathol Oral Radiol Endod.* 2006 Nov;102(5):e23-7.
2. Williams HJ, Wake MJ, John PR. Intraosseous haemangioma of the mandible: a case report. *Pediatr Radiol.* 2002 Aug;32(8):605-8.
3. Cheng NC, Lai DM, Hsieh MH, Liao SL, Chen YB. Intraosseous hemangiomas of the facial bone. *Plast Reconstr Surg.* 2006 Jun;117(7):2366-72.
4. Fernández LR, Luberti RF, Domínguez FV. Radiographic features of osseous hemangioma in the maxillo-facial region. Bibliographic review and case report. *Med Oral.* 2003 May-Jul;8(3):166-77.
5. Capote Moreno A, González García R, Rodríguez Campo FJ, Naval Gías L, Muñoz Guerra MF, Hyun Nam S. Mixoma odontogénico mandibular. *Rev Esp Cirug Oral y Maxilofac.* 2003 Nov-Dec;25(6):371-3.
6. Drage NA, Whaites EJ, Hussain K. Haemangioma of the body of the mandible: a case report. *Br J Oral Maxillofac Surg.* 2003 Apr;41(2):112-4.
7. Sweet C, Silbergleit R, Mehta B. Primary intraosseous hemangioma of the orbit: CT and MR appearance. *AJNR Am J Neuroradiol.* 1997 Feb;18(2):379-81.
8. Zlotogorski A, Buchner A, Kaffe I, Schwartz-Arad D. Radiological features of central haemangioma of the jaws. *Dentomaxillofac Radiol.* 2005 Sep;34(5):292-6.
9. Perugini M, Renzi G, Gasparini G, Cerulli G, Becelli R. Intraosseous hemangioma of the maxillofacial district: clinical analysis and surgical treatment in 10 consecutive patients. *J Craniofac Surg.* 2004 Nov;15(6):980-5.
10. Jayakumar PN, Desai SV, Kovoor JM, Vasudev MK. Percutaneous embolization of mandibular hemangioma: a case report. *J Oral Maxillofac Surg.* 2002 Aug;60(8):945-8.