

Immediate loading and immediate restoration in 105 expanded-platform implants via the Diem System after a 16-month follow-up period

Jose Luis Calvo Guirado ¹, Antonio José Ortiz Ruiz ², Gerardo Gómez Moreno ³, Laura López Marí ⁴, Luis Alberto Bravo González ⁵

(1) Clinical Associate Professor of General Dentistry. Chairman and Head Lecturer of Implant Dentistry, Faculty of Medicine and Dentistry, University of Murcia, Spain

(2) Clinical Associate Professor of Children General Dentistry, Faculty of Medicine and Dentistry, University of Murcia, Spain

(3) Clinical Associate Professor of Special Care in Dentistry, Faculty of Dentistry, University of Granada, Spain

(4) Postgraduate Student of Master in Implant Dentistry, Faculty of Medicine and Dentistry University of Murcia. Spain

(5) Senior Lecturer of Orthodontics, Faculty of Medicine and Dentistry, University of Murcia, Spain

Correspondence:

Dr. Jose Luis Calvo Guirado
Mozart N° 1, 1° G,
30002 Murcia, Spain
E-mail: joseluis.calvo@um.es

Received: 19/05/2007

Accepted: 16/07/2008

Indexed in:

-Index Medicus / MEDLINE / PubMed
-EMBASE, Excerpta Medica
-SCOPUS
-Índice Médico Español
-IBECs

Calvo-Guirado JL, Ortiz-Ruiz AJ, Gómez-Moreno G, López-Marí L, Bravo-González LA. Immediate loading and immediate restoration in 105 expanded-platform implants via the Diem System after a 16-month follow-up period. *Med Oral Patol Oral Cir Bucal*. 2008 Sep;13(9):E576-81.

© Medicina Oral S. L. C.I.F. B 96689336 - ISSN 1698-6946

<http://www.medicinaoral.com/medoralfree01/v13i9/medoralv13i9p576.pdf>

Abstract

Objective: The aim of this study was to report on our experience and outcomes with Certain Prevail Implants and immediate loading via the Diem System after a 16-month follow-up period. **Materials and Methods:** Over a 16-month period, 105 (14 maxilla, 91 mandible) expanded-platform implants were placed in 18 patients (15 females, 3 males; 55.97 ± 7.25 SD years). Resonance frequency analysis (RFA) was measured on the day of placement and at 3, 12 and 16 months. All prostheses were screw mounted on IOL DIEM standard abutments. The follow-up time varied between 3 up to 16 months. **Results:** One implant (0.9%) failed during final prothetic placement (3 months). The RFA (ISQ) measurements at 16 months evaluation for 4 mm- and 5 mm diameter implants were: 76.13 ± 5.0 SD and 76 ± 7.7 SD respectively. The RFA data related to mandible and maxilla, the day 0 mean was 76.47 ± 4.75 SD and 70.13 ± 1.35 SD, at 3 months 70.53 ± 4.0 SD and 66.07 ± 2.9 SD, at 12 months 68.23 ± 3.6 SD and 66.40 ± 2.7 SD and 16 months 68.23 ± 3.6 SD and 66.60 ± 2.5 SD respectively. The crestal bone resorption was 0.6 mm at 16 months in platform switching implants. **Conclusions:** The cumulative implant survival rate during the follow-up period was 99.1% Immediate loading on IOL Diem abutments is a reliable and effective technique for edentulous patients in the maxilla and mandible.

Key words: Immediate loading, osseointegration, Osseotite®, RFA.

Introduction

Immediate implant loading following extraction may maintain crestal bone and interdental soft tissue but has achieved only mixed success. One of the main reasons for the failure of early attempts was the lack of understanding of the biological and mechanical principles that we now know are necessary for clinical success (1-2). With proper implant design, the implant gingival complex may maintain a shallow sulcular environment and allows the new placement of the biological width.

Dental implants that are immediately loaded should be

stable after insertion, and they should be rigidly splinted around the curvature of the arch. These simple guidelines have allowed for the predictable treatment of many patients who would otherwise have had to wear their dentures during the healing period or even go without them during the initial postoperative period. These procedures eliminate the need for additional surgical procedures after interface development and provide an environment for minimum chair time during the final restoration. The authors have outlined their technique for predictable loading of the edentulous mandible as well as the use of new components that make

the procedure faster and more user-friendly for the patient and the treating operating team (3-4).

The clinician is able to obtain predictable aesthetic results for implant restorations if the following biological parameters are taken into account: the different periodontal biotypes; bone density; the formation of the biological space; the distance between implants, the abutment-implant connection and the restoration (5-7).

The clinicians have developed numerous advances in implant design as well as the surgical and restorative techniques and they pose the question as to whether the non-loading of healing implants is still a prerequisite for success. Success rates for endosseous implants have been shown to be greater than 90% (8-9).

The concept of platform switching

The concept of platform switching refers to the use of a smaller diameter abutment on a larger diameter implant collar; this connection shifts the perimeter of the implant-abutment junction (IAJ) inward toward the central axis of the implant (10). Lazzara and Porter put forward the hypothesis that the inward movement of the IAJ is the manner, also shifts the inflammatory cell infiltrate inward and away from the crestal bone, which limits bone resorption around the coronal aspect of the implant (11).

The ability to reduce crestal bone loss and preserve cortical bone can result in significant aesthetic and clinical benefits. In order to facilitate the platform switching technique, expanded platform implants (Certain Prevail, Biomet 3i, Implants Innovations, Inc, Palm Beach Gardens, FL) have been developed. Their design utilizes full Osseotite® surfaces, instead of the original hybrid design, and allows maximum bone-to-implant contact (12,13).

The coronal aspect of Certain Prevail is slightly wider than the diameter of the straight-walled implant body, flaying out approximately at a 30° angle and resulting in a collar diameter of 4.8 mm. The expanded collar can provide a better engagement of the bone crest, an improved setting for immediate implants and greater primary stability. Restoring a 4.8 mm implant collar with the corresponding 4.1 mm prosthetic abutment shifts the implant abutment junction (IAJ) inward, moving the inflammatory infiltrate connective tissue away from the crestal bone (Fig. 1-2).

When two or more adjacent implants are placed into the anterior maxilla, predictable aesthetics are often difficult to achieve. Between adjacent implants the peri-implant tissue significantly alters their histological characteristics and physiological behaviour, thereby intensifying limitations for achieving aesthetic results. The aesthetic restoration of adjacent implants remains a challenge in implant dentistry, described by Tarnow and cols (14).

Calvo Guirado et al. also described the concept of the platform switching technique using a new modification of the implant design in 34 Certain Prevail implants, a one-step protocol and non-functional immediate temporary

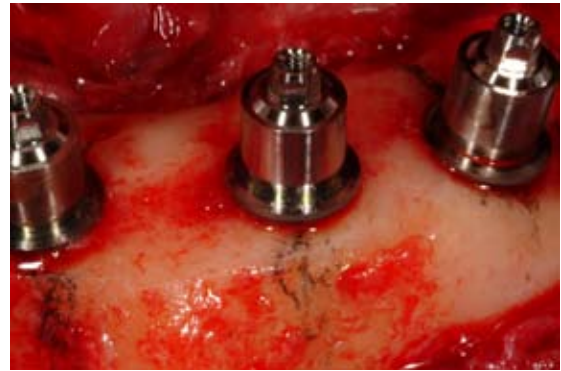


Fig. 1. IOL 4.1 mm abutments on 5/6/5 expanded platform implant.

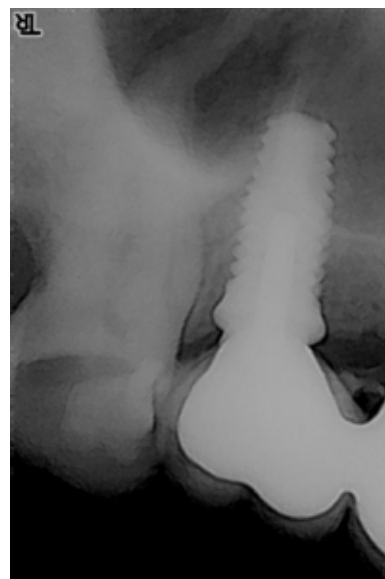


Fig. 2. Periapical radiograph of platform switching technique.

restoration for single implants, preserving crestal bone loss. The resultant mesial bone loss of the central incisor implants was 0.6mm. Mean bone loss was 0.8mm on the distal side of the central incisor implants, 0.7mm on the mesial side of the lateral incisor implants, and 0.6mm on the distal side of the lateral incisor implants (15).

An implant is placed with adequate primary stability; the corresponding restoration has full centric occlusion under maximum intercuspation and must be placed within 48 hours postsurgery. This process is based on a restoration design which aims to prevent the micromotion of the implant.

A fundamental requisite for IOL is adequate primary implant stability. Primary implant stability can be measured via insertion torque values and resonance frequency analysis (RFA) with the Ostell Mentor®. The Ostell Men-

tor is a wireless device and makes use of an aluminium peg attached to an implant. The smart peg is excited and the RFA is expressed electromagnetically as ISQ (implant stability quotient) units. RFA is extensively used in clinical research to monitor implant stability, in other words determined the stiffness of bone-implant complex in maxilla and mandible and the ISQ values varies from 1 to 100 (16-18).

Each implant system tolerates micromotion differently. For implants with roughened surfaces, tolerance falls within the range of 50 µm to 150 µm (19). Regardless of the type of implant selected, all restorative procedures should be completed within two days of implant placement according to the specific needs of the patient, after which time bone healing and implant stability may be disrupted by such intervention (20).

Clinical Evaluation of 105 Osseotite® expanded platform implants

This study was intended to provide a report of our clinical experience and outcomes with expanded platform implants and immediate loading with DIEM System after a 16-month follow-up period.

Materials and Methods

One hundred and five Certain Prevail Implants (14 maxilla, 91 mandible) were placed in 18 patients (15 females and 3 males) with a mean age of 55.97±7.25 SD years. The implant diameters were divided into 4 mm (n=99) and 5 mm (n=6) and the implant lengths were 13 mm (n=77), 11.5 mm (n=22), 10 mm (n=4) and 8.5 mm (n=2).

All implants were evaluated via a resonance frequency analysis device (Ostell Mentor®, Integration Diagnostics AB, Gamlestadvägen, Göteborg, Sweden) on the day of placement and at 3, 12 and 16 months. All the data collected were analyzed via SPSS 14.0

The prostheses were screw mounted on IOL DIEM abutments and the follow-up time was 16 months.

- Inclusion and exclusion criteria

The exclusion criteria include drug and alcohol abuse,

heavy smokers, stroke, uncontrolled diabetes, recent infarction, haemophilia, bleeding disorders or cumarin therapy, metabolic disorders, poor oral hygiene, signs of chronic bone disease, bruxism and general contraindications, poor bone density.(18)

The inclusion criteria are: Edentulous patients, good bone density, good general health and ISQ values more than 60.

- Crestal bone resorption

The crestal bone resorption was measured with digital radiograph on the mesial and distal site and the mean values were -0.5 mm day 0, 0.6 mm at 3, 12 and 16 months (table 1).

- Prosthesis preparation

After the implant placement, final impression was taken and send to the lab technician. Twenty four hours after bite registration , lip line, middle line and vertical dimension measurements were taken. Cad Cam Architect Bar (Biomet 3i, Implants Innovations Inc, Palm Beach Gardens, FL, USA) was send by the lab six days after implant placement to evaluate the passive fit on the IOL abutments. After 7 days of the initial surgery , sutures were removed and final prosthesis was placed.

Results

All the data were evaluated by SPSS 14.0 by ANOVA test.

One implant (4 mm diameter by 13 mm length) was lost at the moment of final prosthetic placement (3 months) in a female 45 year old patient due to smoking reasons in the maxilla.

The ISQ measurements on 4 mm-diameter implants were: day 0: 74.96 ± 5.42 SD, 3 months: 66.43 ± 4.57 SD, 12 months: 75.01 ± 5.39 SD and 16 months: 76.13 ± 5.0 SD. The same ISQ measurements for 5 mm-diameter implants were: day 0: 75.17 ± 3.48 SD, 3 months: 66.50 ± 1.87 SD, 12 months: 75.50 ± 7.39 SD and 16 months: 76 ± 7.77 SD The ISQ measurements for 8.5 mm-length implants were: day 0: 71.50 ± 0.7 SD, 3 months: 66.00 ± 4.24 SD, 12 months: 78.50 ± 0.7 SD and 16 months: 79.50 ± 0.7 SD.

Table 1. Mean marginal bone level change from implant placement to 16 months follow-up period.

	Implant placement day 0	Follow up 3 months	Follow up 12 months	Follow up 16 months
Average (mm)	-0.4	-0.5	-0.5	-0.5
SD	0.8	0.9	1.0	1.0
Number of implants	105	104	104	104
Maximun	0.6	0.7	0.8	0.8
Minimun	-2.0	-2.4	-2.6	-2.6
Mean	-0.5	0.6	0.6	0.6

Table 2. RFA mean in maxilla and mandible during 16 months follow-up period.

	Type	Mean	Standard Deviation	N
Day 0	Maxilla	70.13	1,356	14
	Mandible	76.47	4,752	91
	Total	75.58	4,953	105
3 Months	Maxilla	66.07	2,915	14
	Mandible	70.53	4,004	90
	Total	69.90	4,161	104
12 Months	Maxilla	66.40	2,720	14
	Mandible	68.23	3,630	90
	Total	67.97	3,563	104
16 Months	Maxilla	66.60	2,586	14
	Mandible	68.23	3,630	90
	Total	68.00	3,538	104

The same ISQ measurements for 10 mm length implants were: day 0: 77.5 ± 1.7 SD, 3 months: 66.7 ± 0.9 SD, 12 months: 80.25 ± 3.3 SD and 16 months: 80.50 ± 3.3 SD. The same ISQ measurements for 13 mm length implants were: day 0: 75.4 ± 5.7 SD, 3 months: 66.7 ± 4.8 SD, 12 months: 74.92 ± 5.4 SD and 16 months: 76.08 ± 5.2 SD. The mean ISQ measurements for maxilla was: day 0: 70.13 ± 1.3 SD, 3 months: 66.07 ± 2.9 SD, 12 months: 66.40 ± 2.7 SD and 16 months: 66.60 ± 2.5 SD. Furthermore the mean ISQ measurements for mandible was: day 0: 76.47 ± 4.7 SD, 3 months: 70.53 ± 4.0 SD, 12 months: 68.23 ± 3.6 SD and 16 months: 68.23 ± 3.6 SD (table 2).

We applied/analyzed a 'Mixed design of Repeated-measured ANOVA'. We do not meet nor the sphericity condition (we use Greenhouse-Geisser correction a more conservative criterion when data are not spherical) neither the homocedasticity. We consider the within-subjects effect 'time' (4 levels : day 0, 3 months, 12 months and 16 months). As Between-Subjects effect we consider the 'Type' variable with two levels: 'Maxilla' and 'Mandible'.

We found a significant effect of "time", $F(1,347,312)=70.254$ $p<0.05$ ss. and also for the interaction term 'time *type', $F(145.75,312)=11.006$, $p<0.05$ ss. The Between-Subjects effect was also significant $F(1,104)=15.712$ $p<0.05$ ss.

The violation of the sphericity assumption makes F-test inaccurate. We use Greenhouse-Geisser correction (we apply a more conservative criterion). It results significant ($p<0.05$) for "time", the same for "Time *type".

Only time was significant statistically important after 16 months follow up, related to bone remodeling and implant stiffness due to occlusal loading.

Discussion

Extended integration periods and multiple surgeries present a challenge to patient acceptance of implant therapy in the treatment of partially dentate and edentulous jaws. Immediate loading of oral implants could potentially

overcome these problems. It is widely accepted that immediate loading is a desirable procedure, if the outcome in terms of implant survival and success is comparable with that of conventional loading.

The experience in immediate occlusal loading of oral implants has led to different consensus papers (17,21).

Moreover, some review papers have been published on immediate loading (22-25). The large number of consensus statements and reviews suggest that immediate loading is a field that is still developing, and currently leaves room for different interpretations and philosophies.

The rough surface, a deeply located abutment-implant junction in relation to the prostheses, the type of abutment, the proximity between implants and teeth, and especially gingival biotypes, must be taken into account in order to minimize tissue resorption and crestal bone loss.

The stability of the peri-implant cervical bone around the neck of the implant and the absence of resorption are the key to maintaining gingival papillae and bone in the anterior region.

Bone preserving techniques such as platform switching have been utilized for more than ten years. According to the literature, several changes should occur after abutment connection. Resorption of bone approximately 1.5 mm from the implant abutment interface should occur circumferentially, noticeable on the buccal plate. As a result of these osseous changes, the soft-tissue architecture will be affected as biological width is re-established. Preliminary evidence suggests that the anticipated bone loss that occurs around two-stage implants may be reduced or eliminated when implants are restored with smaller-diameter abutments on larger platforms (17).

However, in the studies selected for Nkenke review, immediate loading was performed successfully when implants were placed in bruxers and non-bruxers, smokers and non-smokers and in patients having diabetes or other systemic diseases (18).

It is important to note that sufficient tissue depth (3mm or more) must be present in order to establish the adequate biological width. In the absence of sufficient soft tissue, bone resorption will likely occur, regardless of the implant geometry. In most of the studies on immediate loading, good bone quality has been mentioned as an important prognostic factor for the success of the procedure (22-26).

This requires the implant platform be placed below the bone crest to obtain adequate tissue depth. Additionally, sufficient ridge width (6.3 mm minimum), should be present in order to place a 4.8 mm implant collar (14).

It seems that planning for immediate loading of dental implants is facilitated by advanced imaging techniques. These techniques allow for selection of implant sites that have the highest Hounsfield values, which correlate with denser bone (27). Moreover, flapless implant placement becomes easier as conventional bone mapping is no longer necessary.

When an abutment is connected to a dental implant at the crestal level, bone loss around the fixture occurs. This bone loss has a horizontal component that results in 1.3 mm to 1.4 mm of resorption from the microgap to the bone in a horizontal direction. (28).

Additionally, the implants can be rigidly splinted directly after placement using a prefabricated, passively fitting superstructure. High implant survival and success rates have been described for this technique in multicentre studies; however, randomized-controlled studies are necessary to test whether this treatment option is superior to standard techniques (29). In the simplified protocol, the acrylic resin prosthesis provided adequate splinting of the implant positions, which apparently was maintained during the healing period. In fact, the authors believe that this could possibly be the most accurate method for impression making for an implant-supported prosthesis, since bone remodeling and healing take place over 3 months to adapt and conform to this prosthesis (30). Immediate implant loading achieved similar success rates as those reported in the delayed 2-stage approach.

- Primary implant stability is a key factor to consider before attempting immediate implant loading.

- Surgery-, host-, implant-, and occlusion related factors may influence the outcomes of immediate implant loading.

- Studies are needed to understand the possibility of immediate implant loading in patients who are diabetics, osteoporotics and heavy smokers as well as those who have other systemic compromising diseases.

- Long-term, prospective studies are still needed to evaluate other potential determining factors on this technique.

Cocnclusions

Immediate implant placement with immediate loading via an IOL Diem System such as platform switching is a sim-

ple, functional and predictable way to avoid peri-implant crestal bone loss around dental implants with mean 0.6 mm during 16 months follow-up period.

In the 68 patients with immediate loading on platform switching implants, obtained 98.6% success rate after a 16-month follow-up period, maintaining crestal bone stability with little resorption (mean 0.6 mm). The ISQ vales at 16 months for 4 mm- and 5 mm-diameter implants was 76.13 ± 5.0 SD and 76 ± 7.7 SD mm respectively. No significant differences were found between the diameter and length of the expanded platform implants. We found a difference in the ISQ measurements between maxilla and mandible with mean 66.60 ± 2.5 SD and 68.23 ± 3.6 SD respectively.

Despite these findings, "platform switching" is a subject that needs more investigation and definite clinical trials are currently underway.

References

1. Testori T, Wiseman L, Woolfe S, Porter SS. A prospective multicenter clinical study of the Osseotite implant: four-year interim report. *Int J Oral Maxillofac Implants.* 2001 Mar-Apr;16(2):193-200.
2. Tarnow DP, Emtiaz S, Classi A. Immediate loading of threaded implants at stage 1 surgery in edentulous arches: ten consecutive case reports with 1- to 5-year data. *Int J Oral Maxillofac Implants.* 1997 May-Jun;12(3):319-24.
3. Testori T, Szmukler-Moncler S, Francetti L, Del Fabbro M, Trisi P, Weinstein RL. Healing of Osseotite implants under submerged and immediate loading conditions in a single patient: a case report and interface analysis after 2 months. *Int J Periodontics Restorative Dent.* 2002 Aug;22(4):345-53.
4. Testori T, Del Fabbro M, Szmukler-Moncler S, Francetti L, Weinstein RL. Immediate occlusal loading of Osseotite implants in the completely edentulous mandible. *Int J Oral Maxillofac Implants.* 2003 Jul-Aug;18(4):544-51.
5. Grunder U, Spielman HP, Gaberthüel T. Implant-supported single tooth replacement in the aesthetic region: a complex challenge. *Pract Periodontics Aesthet Dent.* 1996 Nov-Dec;8(9):835-42.
6. Touati B. Improving aesthetics of implant-supported restorations. *Pract Periodontics Aesthet Dent.* 1995 Nov-Dec;7(9):81-92.
7. Tarnow DP, Cho SC, Wallace SS. The effect of inter-implant distance on the height of inter-implant bone crest. *J Periodontol.* 2000 Apr;71(4):546-9.
8. Saadoun AP, Le Gall MG, Touati B. Current trends in implantology: Part I--Biological response, implant stability, and implant design. *Pract Proced Aesthet Dent.* 2004 Aug;16(7):529-35.
9. Touati B, Rompen E, Van Dooren E. A new concept for optimizing soft tissue integration. *Pract Proced Aesthet Dent.* 2005 Nov-Dec;17(10):711-2, 714-5.
10. Ericsson I, Nilson H, Lindh T, Nilner K, Randow K. Immediate functional loading of Brånemark single tooth implants. An 18 months' clinical pilot follow-up study. *Clin Oral Implants Res.* 2000 Feb;11(1):26-33.
11. Lazzara RJ, Porter SS. Platform switching: a new concept in implant dentistry for controlling postrestorative crestal bone levels. *Int J Periodontics Restorative Dent.* 2006 Feb;26(1):9-17.
12. Gardner DM. Platform switching as a means to achieving implant esthetics. *N Y State Dent J.* 2005 Apr;71(3):34-7.
13. Baumgarten H, Cocchetto R, Testori T, Meltzer A, Porter S. A new implant design for crestal bone preservation: initial observations and case report. *Pract Proced Aesthet Dent.* 2005 Nov-Dec;17(10):735-40.
14. Tarnow DP, Magner AW, Fletcher P. The effect of the distance from the contact point to the crest of bone on the presence or absence of the interproximal dental papilla. *J Periodontol.* 1992 Dec;63(12):995-6.
15. Calvo Guirado JL, Saez Yuguero MR, Pardo Zamora G, Muñoz

- Barrio E. Immediate provisionalization on a new implant design for esthetic restoration and preserving crestal bone. *Implant Dent*. 2007 Jun;16(2):155-64.
16. Tarnow D, Elian N, Fletcher P, Froum S, Magner A, Cho SC, et al. Vertical distance from the crest of bone to the height of the interproximal papilla between adjacent implants. *J Periodontol*. 2003 Dec;74(12):1785-8.
17. Aparicio C, Rangert B, Sennerby L. Immediate/early loading of dental implants: a report from the Sociedad Española de Implantes World Congress consensus meeting in Barcelona, Spain, 2002. *Clin Implant Dent Relat Res*. 2003;5(1):57-60.
18. Nkenke E, Fenner M. Indications for immediate loading of implants and implant success. *Clin Oral Implants Res*. 2006 Oct;17 Suppl 2:19-34.
19. Cooper LF, Rahman A, Moriarty J, Chaffee N, Sacco D. Immediate mandibular rehabilitation with endosseous implants: simultaneous extraction, implant placement, and loading. *Int J Oral Maxillofac Implants*. 2002 Jul-Aug;17(4):517-25.
20. Aparicio C, Lang NP, Rangert B. Validity and clinical significance of biomechanical testing of implant/bone interface. *Clin Oral Implants Res*. 2006 Oct;17 Suppl 2:2-7.
21. Cochran DL, Morton D, Weber HP. Consensus statements and recommended clinical procedures regarding loading protocols for endosseous dental implants. *Int J Oral Maxillofac Implants*. 2004;19 Suppl:109-13.
22. Chiapasco M, Abati S, Romeo E, Vogel G. Implant-retained mandibular overdentures with Brånemark System MKII implants: a prospective comparative study between delayed and immediate loading. *Int J Oral Maxillofac Implants*. 2001 Jul-Aug;16(4):537-46.
23. Esposito M, Worthington HV, Thomsen P, Coulthard P. Interventions for replacing missing teeth: different times for loading dental implants. *Cochrane Database Syst Rev*. 2004;(3):CD003878.
24. Peñarrocha M, Uribe R, Balaguer J. Immediate implants after extraction. A review of the current situation. *Med Oral*. 2004 May-Jul;9(3):234-42.
25. Uribe R, Peñarrocha M, Balaguer J, Fulgueiras N. Immediate loading in oral implants. Present situation. *Med Oral Patol Oral Cir Bucal*. 2005 Jul 1;10 Suppl 2:E143-53.
26. De Kok IJ, Chang SS, Moriarty JD, Cooper LF. A retrospective analysis of peri-implant tissue responses at immediate load/provisionalized microthreaded implants. *Int J Oral Maxillofac Implants*. 2006 May-Jun;21(3):405-12.
27. Romeo E, Chiapasco M, Lazza A, Casentini P, Ghisolfi M, Iorio M, et al. Implant-retained mandibular overdentures with ITI implants. *Clin Oral Implants Res*. 2002 Oct;13(5):495-501.
28. Jaffin RA, Kumar A, Berman CL. Immediate loading of dental implants in the completely edentulous maxilla: a clinical report. *Int J Oral Maxillofac Implants*. 2004 Sep-Oct;19(5):721-30.
29. Testori T, Meltzer A, Del Fabbro M, Zuffetti F, Troiano M, Francetti L, et al. Immediate occlusal loading of Osseotite implants in the lower edentulous jaw. A multicenter prospective study. *Clin Oral Implants Res*. 2004 Jun;15(3):278-84.
30. Romanos GE, Toh CG, Siar CH, Swaminathan D. Histologic and histomorphometric evaluation of peri-implant bone subjected to immediate loading: an experimental study with *Macaca fascicularis*. *Int J Oral Maxillofac Implants*. 2002 Jan-Feb;17(1):44-51.