

## Local flap reconstruction of large scalp defects

José Antonio García del Campo <sup>1</sup>, José Antonio García de Marcos <sup>2</sup>, José Luis del Castillo Pardo de Vera <sup>1</sup>, María Jesús García de Marcos <sup>3</sup>

(1) Consultant. Oral and Maxillofacial Surgery Department. "La Paz" University Hospital. Madrid, Spain

(2) Consultant. Oral and Maxillofacial Surgery Department. Albacete University Complex. Albacete, Spain

(3) Stomatologist. Private practice. Madrid. Spain

### Correspondence:

Dr. José Antonio García del Campo

C/ Antonio Acuña. Nº10.5º Aizq.

28009. Madrid, Spain

E-mail: pepio2@hotmail.com

Received: 09/01/2008

Accepted: 16/05/2008

### Indexed in:

-Index Medicus / MEDLINE / PubMed  
-EMBASE, Excerpta Medica  
-SCOPUS  
-Índice Médico Español  
-IBECs

García-del Campo JA, García-de Marcos JA, del Castillo-Pardo de Vera JL, García-de Marcos MJ. Local flap reconstruction of large scalp defects.

Med Oral Patol Oral Cir Bucal. 2008 Oct;13(10):E666-70.

© Medicina Oral S. L. C.I.F. B 96689336 - ISSN 1698-6946

<http://www.medicinaoral.com/medoralfree01/v13i10/medoralv13i10p666.pdf>

### Abstract

Scalp defects can have a number of origins, and their repair is dependent upon their location, size and depth. In the case of the scalp, the repair of even small defects is complicated. Local flaps are the reference for the reconstruction of such defects. Knowledge of scalp anatomy is essential for preparing these flaps, which must be based on one or two vascular pedicles to afford a large rotation angle – thereby facilitating closure of the defect. The parietal zone is the location offering the greatest flap mobilization possibilities.

We present a case involving the repair of a major pericranial frontoparietal scalp defect. A local transverse posterior transpositioning scalp flap was raised with the posterior auricular and occipital arteries as vascular pedicle. Following repositioning of the flap, a free partial-thickness skin graft from the thigh was used to cover the donor zone. A review is provided of the different techniques for the reconstruction of large scalp defects.

**Key words:** Scalp, local flaps, reconstruction, scalp defects.

### Introduction

Scalp defects are caused by traumatism, tumor resection surgery, radiotherapy-induced necrosis, burns and infections (1-3). The repair of such defects is dependent upon their location, size and depth (2). Unlike in other head and neck areas where local flaps are used to repair large defects, in the region of the scalp the repair of even small defects is complicated (1,3-5). Rotation, advancement and transpositioning scalp flaps are the reference for reconstructing these defects. The correct design of such flaps includes preservation of the original hairline, acceptable redirectioning of the hair follicles, the incorporation of large vascular pedicles, and wound closure without excessive tension (3-6). These flaps in turn may require skin grafts to cover the donor zone (1,4,6).

Knowledge of scalp anatomy is essential for preparing these flaps (4). The skin layers of the scalp are easy to remember: SCALP (S: skin; C: subcutaneous tissue; A:

aponeurotic layer; L: loose areolar tissue; P: pericranium) (6-8). The skin in this region is the thickest in the body. It is resistant, very scantily elastic, and is covered with hair (3,6,8). The subcutaneous tissue in turn contains the blood vessels, nerves and hair follicles (6,7). An exception to this anatomical distribution is the location of the superficial temporal artery in the temporoparietal region, which is located in the temporoparietal fascia (6,7,9). The main arteries irrigating the scalp are the superficial temporal artery, with its frontal and parietal branches, the posterior auricular artery and the occipital artery – all of which are branches of the external carotid artery – and the supraorbital and trochlear arteries (branches of the internal carotid artery)(6,8). Local flaps must be based on one or two vascular pedicles of the scalp to afford a large rotation angle – thereby facilitating closure of the defect (1,6). The aponeurotic layer, also known as the epicranial aponeurosis, is the strongest layer of the scalp, and is anteriorly

contiguous to the frontal muscle; posteriorly to the occipital muscles; and laterally to the temporoparietal fascia (6,8). As a result of its scant elasticity, the aponeurosis opposes desired flap advancement. This can be overcome by making incisions perpendicular to the direction of flap movement (5,6,8). Correct closure with these flaps requires suturing the aponeurotic layer (6). Local scalp flaps are composed of skin, subcutaneous tissue and aponeurosis, intimately connected by fibrous trabeculae. The loose areolar tissue – also known as the subaponeurotic fascia, fascia innominata, and subaponeurotic plane – allows mobility of the scalp (6,8). In this context, the parietal zone is the most mobile scalp region. The pericranium is intimately adhered to the skull. It must be left intact as far as possible, since free skin grafts can be applied to it – thereby facilitating reconstruction (6).

There are a number of local flap techniques: single or multiple, and with or without skin grafting to close the donor defects. Single flaps in turn comprise rotation, advancement, transpositioning, bipedicle transpositioning, VY advancement and rhomboidal flaps, etc. (1,5,8,9). Multiple flaps in turn include the triple-flap technique described by Orticochea, the triple rotation (pinwheel) flap, double rotation flap, triple rhomboid flap, and V-Y-S scalp plasty technique, etc. (1,2,5). The patients at greatest risk of complications after scalp reconstruction are those previously subjected to radiotherapy, patients receiving adjuvant or postoperative chemotherapy, those with cerebrospinal fluid fistulas, and patients with anteriorly located defects (4).

We report the case of a patient with a recurrent scalp melanoma. Following resection of the lesion, a large frontoparietal defect including the pericranium remained. The defect was repaired by raising a local transverse posterior transpositioning scalp flap with the posterior auricular and occipital arteries as vascular pedicle. Following repositioning of the flap, a free partial-thickness skin graft from the thigh was used to cover the donor zone.

### Clinical Case

An 82-year-old man was referred to our Service for evaluation and treatment of a long-evolving excrescent lesion in the frontoparietal region, measuring 2 x 2 x 1.2 cm in size. The growth was of soft consistency, occasionally hemorrhagic, and was not adhered to deep layers. The personal history comprised surgery one month before for the removal of a basal cell epithelioma in the left nasogenian sulcus, and arterial hypertension treated with amiloride and hydrochlorothiazide.

The lesion was removed under local anesthesia, with safety margins and preserving the periosteum. The resulting defect was repaired with a full-thickness skin graft from the supraclavicular region. The histopathological diagnosis was ulcerated polypoid nodular melanoma, corresponding to Level III of the Clark classification, a

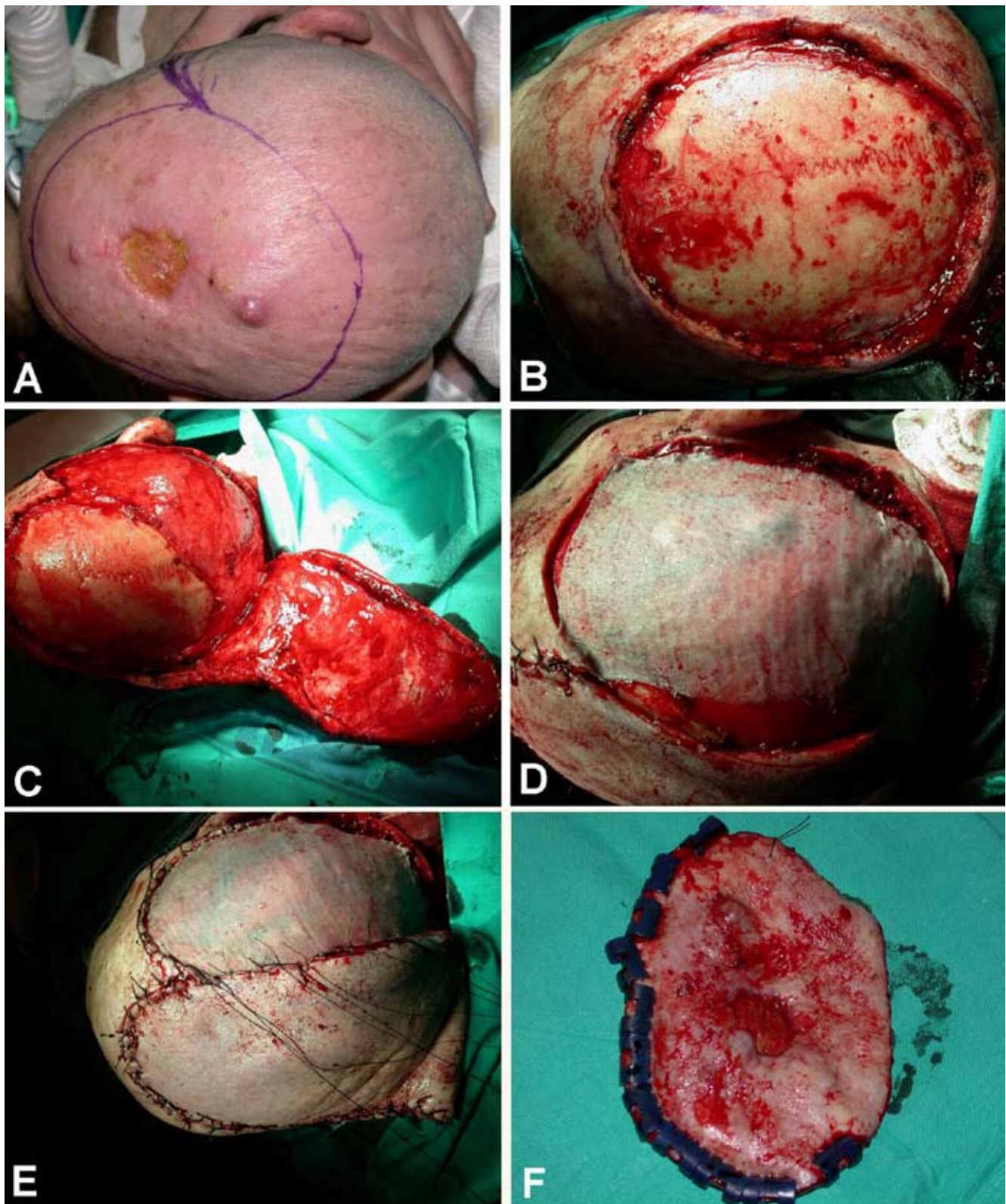
Breslow maximum thickness of 12 mm, and with tumor-free surgical margins.

Twenty days after the operation the patient presented a 2.5 x 2 cm ulcerated lesion in the operated zone, surrounded by multiple elevated nodular lesions – the largest measuring 5 mm in diameter (Fig. 1A). Recurrent melanoma with satellitosis was diagnosed. The physical examination revealed no evidence of distant disease spread. The complete blood count and biochemistry parameters were normal. A computed tomography scan from head to abdomen for the evaluation of possible metastases proved negative. Under general anesthesia, radical resection of the frontoparietal scalp lesions was carried out, including the pericranium (Fig. 1B). The resulting post-resection defect measured 12 x 8.5 x 0.4 cm in size. A local transverse posterior transpositioning scalp flap with preservation of the pericranium in the region of the flap was used to repair the defect (Fig. 1C). Following repositioning of the flap, a free partial-thickness skin graft from the right thigh was used to cover the donor zone (Fig. 1D and E). An aspirating drain was placed, and the wound was subjected to layered suturing. In the region of the local flap we placed a moderate compression bandage, while gauze impregnated in antibiotic cream was placed over the skin graft zone, affixed with silk, and compressing the graft to avoid hematoma formation. The histological study confirmed nodular melanoma metastasis, with disease-free resection margins (Fig. 1F). One and a half months after the operation, a flap scar plasty was performed, removing the “dog ear” left after surgery. The esthetic outcome was satisfactory (Fig. 2A and B). Five years after the last oncological operation, no evidence of local or regional disease recurrence is observed.

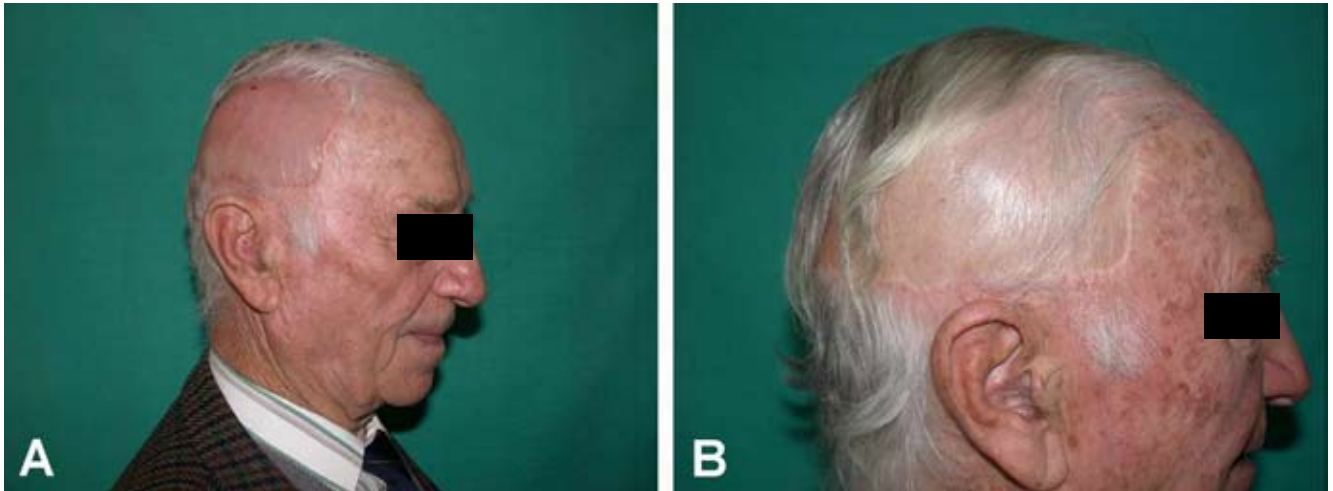### Discussion

There are many options for repairing large scalp defects (1,9). The use of tissue expanders facilitates direct defect closure (1,6). This latter technique yields a larger amount of scalp tissue by placing an expanding device in the loose areolar tissue – with good esthetic results (4). Expansion preferably should be carried out before removal of the lesion, and constitutes an excellent repair option for the reconstruction of defects following the resection of benign lesions (1,4).

Healing by second intention is a possibility for repairing scalp defects, though this option is not applicable in the presence of large defects with a lack of pericranium (1). The use of free skin grafts for reconstruction requires an intact pericranium to supply vascularization to the repaired zone. In addition, careful hemostasis of the receptor bed is necessary, since the formation of hematomas would compromise graft success. In the absence of a pericranium, and if grafting is the only repair option, perforations in the external cortical layer of the skull allow the formation of granulation tissue that would improve the prognosis of the second-step free skin graft (1,4).



**Fig. 1.** A: Preoperative view of the lesion, showing recurrence of the melanoma with satellitosis; B: Defect after tumor resection, in the frontoparietal region; C: Transverse posterior transpositioning flap, preserving the pericranium in the region of the flap; D: Partial-thickness skin graft from the thigh applied to the pericranial zone to cover the donor site; E: Final appearance. Note the “dog ear” in the flap rotation zone; F: View of the surgical piece.



**Fig. 2.** Postoperative view. A: Four months after oncological surgery; B: Ten months after oncological surgery.

The island graft is a local graft variant composed of a scalp island without pericranium, with a vascular pedicle surrounded by subcutaneous tissue and an aponeurotic layer. It is mobilized to cover scalp defects (3).

Pericranial and fascial flaps have also been described in which the pericranium, the frontal aponeurosis or temporoparietal fascia are mobilized below the donor zone and are rotated. Posteriorly, a skin graft is placed over the vascularized tissue (1).

Pedicled myocutaneous flaps from other anatomical regions have been used to reconstruct inferior temporal or occipital scalp defects (e.g., from the latissimus dorsi, trapezius and pectoral muscle regions) (1,7). In our patient the defect was located in the frontoparietal region, which precluded the use of such flaps.

Microvascularized flaps have become the treatment of choice for repairing extensive scalp defects – particularly in the presence of an associated bone defect (1,6). This technique can be applied to previously irradiated or infected tissues, or in areas with a traumatized bed, where the use of local flaps would not be indicated (10). Most authors agree that the most commonly used microvascularized flaps are the radial fasciocutaneous flap, the latissimus dorsi myocutaneous flap, serratus major, rectus abdominis myocutaneous flap, and the omentum flap (1,6,7). The advantage of these microvascularized flaps is that they allow the repair of large defects with highly vascularized tissue, in a single surgical step (1). The disadvantages are a prolongation of the surgical time, the possibility of total flap loss, morbidity in the donor zone, the fact that some flaps do not have enough skin to reconstruct large defect, and the absence of hair on the donor skin (1). It is advisable to reserve these flaps for cases where local flap placement, skin grafting or healing by second intention are not possible.

A basic principle in surgery is to first use the most simple

technique available (2). In our case we presented a simple local flap procedure for repairing a large scalp defect that included pericranium.

When these flaps are applied to the scalp region, the edges of the wound must be carefully treated, taking care to avoid excessive tension at the extremities, since localized ischemia with involution of the hair follicles could result. Prior local anesthetic infiltration with epinephrine reduces bleeding at the wound edges, and facilitates dissection of the loose areolar plane (6). Electrocauterization is to be avoided, in order to reduce thermal damage to the hair follicles. The use of these flaps generally leaves “dog ears” at the end of surgery. When this happens, the temptation to resect them in the same surgical procedure is to be avoided, since they tend to disappear over time, and removal during surgery would increase tension upon the flap – thereby placing the extremities of the latter at risk. If the esthetic deformity persists after a certain period of time, it can be corrected by means of a small operation under local anesthesia (6). In our patient, “dog ear” plasty under local anesthesia was performed one and a half months after the initial operation, without complications. The anteroposterior midline of the scalp is a zone where the vascular territories of both sides of the cranium converge, forming a physiological barrier. It is advisable not to surpass this zone too much when preparing the flap, particularly in the region of the nape of the neck, where skin circulation is less pronounced than at scalp level. When the transverse posterior flap is fully located within the scalp region, as in our case, circulation is better and the risk of necrosis is reduced as a result. In the immediate postoperative period it is advisable to apply slight pressure to the flap, in order to avoid hematoma formation. Excessive pressure is to be avoided, however, since ischemia secondary to compression of the vascular pedicles may result (8).

## Conclusion

The present case describes a simple procedure for repairing a large scalp defect including the pericranium, by means of a local flap and partial-thickness skin graft. The shortening of surgical time compared with other techniques, the simplicity of the surgical procedure, minimum morbidity in the free skin graft donor zone, and the satisfactory esthetic outcome make this an adequate option for repairing defects of this kind.

## References

1. Frodel JL Jr, Ahlstrom K. Reconstruction of complex scalp defects: the "Banana Peel" revisited. *Arch Facial Plast Surg*. 2004 Jan-Feb;6(1):54-60.
2. Demir Z, Velidedeoğlu H, Celebioğlu S. V-Y-S plasty for scalp defects. *Plast Reconstr Surg*. 2003 Sep 15;112(4):1054-8.
3. Mehrotra S, Nanda V, Shar RK. The islanded scalp flap: a better regional alternative to traditional flaps. *Plast Reconstr Surg*. 2005 Dec;116(7):2039-40.
4. Newman MI, Hanasono MM, Disa JJ, Cordeiro PG, Mehrara BJ. Scalp reconstruction: a 15-year experience. *Ann Plast Surg*. 2004 May;52(5):501-6.
5. Michaelidis IG, Stefanopoulos PK, Papadimitriou GA. The triple rotation scalp flap revisited: a case of reconstruction of cicatricial pressure alopecia. *Int J Oral Maxillofac Surg*. 2006 Dec;35(12):1153-5.
6. Leedy JE, Janis JE, Rohrich RJ. Reconstruction of acquired scalp defects: an algorithmic approach. *Plast Reconstr Surg*. 2005 Sep 15;116(4):54e-72e.
7. Tellioglu AT, Cimen K, Açar HI, Karaeminoğullar G, Tekdemir I. Scalp reconstruction with island hair-bearing flaps. *Plast Reconstr Surg*. 2005 Apr 15;115(5):1366-71.
8. Orticochea M. Colgajos de revestimiento cutáneo del cráneo. In: Grabbb WC, Myers MB, ed. *Colgajos cutáneos*. Barcelona: Salvat Editores, S.A; 1982. p. 149-75.
9. Onishi K, Maruyama Y, Hayashi A, Inami K. Repair of scalp defect using a superficial temporal fascia pedicle VY advancement scalp flap. *Br J Plast Surg*. 2005 Jul;58(5):676-80.
10. Patel MP, Spinelli HM. The scalping flap for reconstruction of upper cranial and cranial base defects. *Plast Reconstr Surg*. 2004 Jul;114(1):186-9.