

## Use of mineral trioxide aggregate in the non-surgical repair of perforating invasive cervical resorption

Jun-Beom Park <sup>1</sup>, Jeong-Heon Lee <sup>2</sup>

(1) Department of Pharmaceutical Sciences, College of Pharmacy, University of Michigan, Ann Arbor, Michigan, USA

(2) Seoul Eun Dental Clinic, Gunpo-si, Gyeonggi-do, Korea

### Correspondence:

Dr. Jun-Beom Park

Currently Visiting Scientist at Dpt. of Pharmaceutical Sciences,

College of Pharmacy, University of Michigan.

1664 McIntyre Drive Ann Arbor MI 48105

E-mail: jbassoonis@yahoo.co.kr

Received: 02/03/2008

Accepted: 29/03/2008

### Indexed in:

-Index Medicus / MEDLINE / PubMed  
-EMBASE, Excerpta Medica  
-SCOPUS  
-Indice Médico Español  
-IBECs

Park JB, Lee JH. Use of mineral trioxide aggregate in the non-surgical repair of perforating invasive cervical resorption. Med Oral Patol Oral Cir Bucal. 2008 Oct;13(10):E678-80.

© Medicina Oral S. L. C.I.F. B 96689336 - ISSN 1698-6946

<http://www.medicinaoral.com/medoralfree01/v13i10medoralv13i10p678.pdf>

### Abstract

Mineral trioxide aggregate (MTA) has shown potential as a repair material for perforations. This clinical case demonstrates that when MTA was used as a repair material for root perforation due to invasive cervical resorption, the tooth was well in function for 27 months. Both clinical and radiographic follow-up showed a stable condition without any probing defect, ongoing root resorption, or apical pathosis.

**Key words:** Mineral trioxide aggregate, invasive cervical resorption, perforation, orthograde approach, permanent pre-molar.

### Introduction

Invasive cervical resorption is a clinical term used to describe a relatively uncommon, insidious, and often aggressive form of external root resorption (1). It is seen in most cases as a late complication of traumatic injuries of the teeth, but it may also occur after orthodontic movement, orthognatic and other dentoalveolar surgery, periodontal treatment, bleaching of teeth, and a wide variety of traumatic conditions (2).

Mineral trioxide aggregate or MTA (MTA; Pro-Root®, Dentsply Tulsa, Tulsa, OK) is reported to show good sealing ability, a high degree of biocompatibility (3), and potential to be repair material for perforations (4,5). There is limited report on repairing permanent teeth with invasive cervical resorption using MTA (6). In this case report, the lingual perforation was repaired with MTA and the rest of the canal was filled with gutta percha points.

### Case Report

A 28-year-old Asian male patient presented with a complaint of acute pain that started a month before admis-

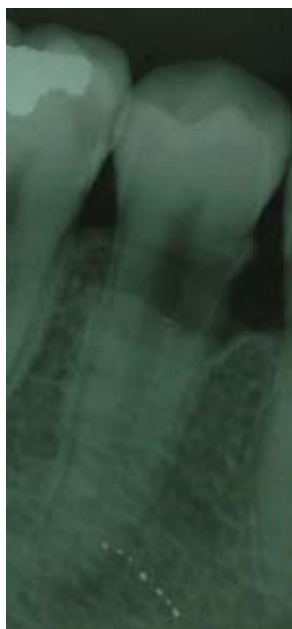sion. The patient had a history of trauma. He was in a traffic accident eight years ago. His medical history was noncontributory.

On the clinical examination of the right mandibular region, it was noted that the second premolar was painful during biting and percussion. The tooth was unresponsive to sensitivity testing with cold or an electric pulp tester (Parkell, Farmingdale, NY, USA). Radiographic examination demonstrated an apparent radiolucency in the coronal third of the root canal (Figure 1). There was clinically obvious pinkish color in tooth especially on the lingual side. There was no periodontal defect or a bleeding sign on probing. Clinical and radiographic examination indicated pulp necrosis with invasive cervical resorption with lingual perforation. The patient was given a detailed explanation concerning the planned treatment procedure and prognosis. Consent was received from the patient.

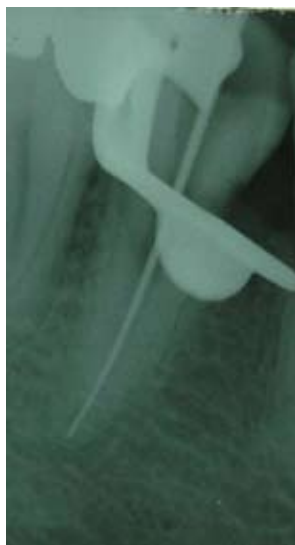The tooth was isolated with a rubber dam after the application of local anesthesia. A conventional access cavity was prepared in the occlusal surface of the first premolar with a 330-carbide bur, and the cavities were widened with an

Endo-Z bur (Dentsply Maillefer, Tulsa, OK) to enhance the visibility of the root canal. Irrigation of the canal was done several times with 5% sodium hypochlorite, and the last irrigation solution was left in the canal for 30 minutes to dissolve organic material. The canal was filled with calcium hydroxide, cotton and zinc oxide eugenol.

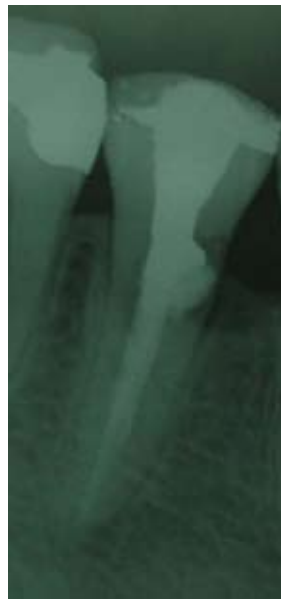
At the next visit, determination of the working length was done using an electronic apex locator (Root ZX®, J Morita Corporation. Kyoto, Japan) and radiograph (Figure 2). Canal enlargement was then performed using nickel-titanium rotary instruments (Profile, Dentsply Tulsa, Tulsa, OK, USA). At the third visit, which was one week after initial visit, MTA was mixed with sterile water to a paste consistency following the manufacturer's instructions. Local anesthesia was administered, and MTA was applied into the cervical resorption defect with a small plugger through the coronal access cavity with small increments. MTA was gently packed against the dentinal wall and the gingiva. The remaining root canal was filled with gutta-percha points and sealer (AH26, Dentsply, Konstanz, Germany) using a lateral condensation technique (Figure 3). An amalgam core was added, and the treated tooth was restored with a porcelain-fused metal crown. The tooth has been asymptomatic since the obturation. The patient was recalled regularly, and he was clinically and radiographically asymptomatic up to the 27-month follow-up (Figure 4).



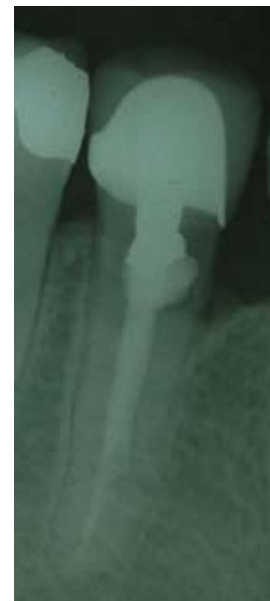**Fig. 1.** Preoperative radiograph of the lower right second premolar with invasive cervical resorption and root perforation.



**Fig. 2.** Working length radiograph.



**Fig. 3.** Radiograph of the mandibular right second premolar with MTA and gutta percha points.



**Fig. 4.** Twenty-seven-month postoperative radiograph showing stable condition.

### Discussion

MTA has an excellent sealing ability in the presence of moisture in a root canal (3). This property is especially important in teeth with perforation and cervical resorption because the material may be exposed to oral fluids. The orthograde delivery of the MTA is a more sensitive technique than the retrograde method (7). In this case, MTA was packed against the dentinal wall and the gingiva through the coronal access cavity. Local anesthesia was administered because the operator wanted to relieve the pain that the patient may experience when the filling material was packed against the tissue. The gingiva and remaining tooth structure served as the matrix.

Although the surgical intervention of perforation and repair with MTA were reported to be successful (8,9), there are several disadvantages to the surgical procedure. Formation of a physiological gingival crevice, function regeneration and maturation of the gingival connective tissue requires 3 to 5 weeks (10) and surgical intervention would be more difficult if the defect was located on the lingual aspect of the root (11). A patient's anxiety about the surgery and additional healing time for soft tissue may be a limiting factor.

Topical application of 90% aqueous trichloroacetic acid was introduced in the treatment of invasive cervical resorption, because it causes coagulation necrosis and makes the resorptive tissue avascular and inactive (12). In this case, 5% sodium hypochlorite was left in the canal for 30 minutes to dissolve the tissue. Sodium hypochlorite is well known to be effective in removing the smear layer from

the canal walls (13) and reducing the microorganisms (14) and inflammatory reaction (15) with its availability in the clinic.

This clinical case demonstrates that when MTA was used as a repair material for root perforation due to cervical resorption, the tooth was well in function for 27 months. Both clinical and radiographic follow-up showed a stable condition without any probing defect, ongoing root resorption, or apical pathosis.

In conclusion, MTA may be used as a repair material for root perforation due to cervical resorption using an orthograde approach.

## References

1. Heithersay GS. Invasive cervical resorption: an analysis of potential predisposing factors. *Quintessence Int.* 1999 Feb;30(2):83-95.
2. Gonzales JR, Rodekirchen H. Endodontic and periodontal treatment of an external cervical resorption. *Oral Surg Oral Med Oral Pathol Oral Radiol Endod.* 2007 Jul;104(1):e70-7.
3. Torabinejad M, Watson TF, Pitt Ford TR. Sealing ability of a mineral trioxide aggregate when used as a root end filling material. *J Endod.* 1993 Dec;19(12):591-5.
4. Lee SJ, Monsef M, Torabinejad M. Sealing ability of a mineral trioxide aggregate for repair of lateral root perforations. *J Endod.* 1993 Nov;19(11):541-4.
5. Arens DE, Torabinejad M. Repair of furcal perforations with mineral trioxide aggregate: two case reports. *Oral Surg Oral Med Oral Pathol Oral Radiol Endod.* 1996 Jul;82(1):84-8.
6. Baratto-Filho F, Limongi O, Araújo Cde J, Neto MD, Maia SM, Santana D. Treatment of invasive cervical resorption with MTA: case report. *Aust Endod J.* 2005 Aug;31(2):76-80.
7. Pace R, Giuliani V, Pini Prato L, Baccetti T, Pagavino G. Apical plug technique using mineral trioxide aggregate: results from a case series. *Int Endod J.* 2007 Jun;40(6):478-84.
8. Hsien HC, Cheng YA, Lee YL, Lan WH, Lin CP. Repair of perforating internal resorption with mineral trioxide aggregate: a case report. *J Endod.* 2003 Aug;29(8):538-9.
9. Ford HE, Ford TR. Surgical repair of a resorptive defect in an anterior tooth of an adolescent: a case report. *Int J Paediatr Dent.* 1998 Sep;8(3):219-22.
10. Ramfjord SP, Engler WO, Hiniker JJ. A radioautographic study of healing following simple gingivectomy. II. The connective tissue. *J Periodontol.* 1966 May-Jun;37(3):179-89.
11. Hunt PR. Safety aspects of mandibular lingual surgery. *J Periodontol.* 1976 Apr;47(4):224-9.
12. Heithersay GS. Treatment of invasive cervical resorption: an analysis of results using topical application of trichloroacetic acid, curettage, and restoration. *Quintessence Int.* 1999 Feb;30(2):96-110.
13. Teixeira CS, Felipe MC, Felipe WT. The effect of application time of EDTA and NaOCl on intracanal smear layer removal: an SEM analysis. *Int Endod J.* 2005 May;38(5):285-90.
14. Jiménez-Rubio A, Segura JJ, Llamas R, Jiménez-Planas A, Guerrero JM, Calvo JR. In vitro study of the effect of sodium hypochlorite and glutaraldehyde on substrate adherence capacity of macrophages. *J Endod.* 1997 Sep;23(9):562-4.
15. Ercan E, Ozekinci T, Atakul F, Gül K. Antibacterial activity of 2% chlorhexidine gluconate and 5.25% sodium hypochlorite in infected root canal: in vivo study. *J Endod.* 2004 Feb;30(2):84-7.

## Acknowledgement and Disclosure

This manuscript has not been published or submitted for publication elsewhere. All the authors have contributed significantly and are in agreement with the content of the manuscript. All the authors do not have conflicts of interest.