

## Prostatic adenocarcinoma with mandibular metastatic lesion: Case report

Daniel Reyes Court<sup>1,3</sup>, Susana Encina<sup>2,3</sup>, Irene Levy<sup>4</sup>

(1) Profesor Ayudante. Departamento de Cirugía y Traumatología Bucal y Máxilofacial, Facultad de Odontología, Universidad de Chile

(2) Profesor Titular Departamento de Cirugía y Traumatología Bucal y Máxilofacial, Facultad de Odontología, Universidad de Chile

(3) Unidad de Cirugía y Traumatología Bucal y Máxilofacial, Hospital San Borja Arriarán

(4) Unidad de Anatomía Patológica, Hospital Clínico San Borja-Arriarán. Santiago de Chile

### Correspondence:

Dr. Daniel Reyes Court

Dpto. de Cirugía y Traumatología Bucal y Máxilofacial,

Facultad de Odontología,

Universidad de Chile,

Calle Olivos 943, Independencia,

Santiago de Chile

E-mail: reyescourt@yahoo.es

Received: 7-07-2006

Accepted: 15-07-2007

Reyes-Court D, Encina S, Levy I. Prostatic adenocarcinoma with mandibular metastatic lesion: Case report. Med Oral Patol Oral Cir Bucal. 2007 Oct 1;12(6):E424-7.

© Medicina Oral S. L. C.I.F. B 96689336 - ISSN 1698-6946

### Indexed in:

-Index Medicus / MEDLINE / PubMed  
-EMBASE, Excerpta Medica  
-SCOPUS  
-Índice Médico Español  
-IBECs

### ABSTRACT

Metastatic lesions of primary tumors, which originate in different parts of the body, comprise almost 1 % of different types of oral cancers. These lesions can affect either bones or soft tissues in the maxillofacial region. Whenever the maxillofacial area is affected, the most common location is in the molar region of the mandible. The clinical presentation of mandibular metastasis follows a clinical pattern characterized by irradiated dental pain in the third molar region. The most frequent sign is paresthesia of the area innervated by the mandibular alveolar dental nerve. Differential diagnosis and treatment of these patients can be extremely difficult because there a number of pathologic conditions with similar symptoms and because diagnostic examination can be highly confusing.

The aim of this article is to present a case of prostatic adenocarcinoma where the only metastasis was found in the jaw. A literature review will be presented, hoping to contribute to the scarce information regarding this lesion, due to its low frequency and atypical expression of this type of metastasis in terms of etiology, biological behavior and treatment.

**Key words:** *Maxillofacial osseous metastasis, prostatic adenocarcinoma.*

### RESUMEN

Alrededor del 1% de todos los tipos de cáncer oral son metástasis de tumor primario originado en cualquier parte del organismo, pueden afectar tanto los tejidos blandos como los huesos maxilares. Las metástasis, desarrolladas en la mandíbula son poco frecuentes, sin embargo en el territorio máxilofacial, la zona más común de localización es en la mandíbula, y se ubica más frecuentemente en el área molar. La presentación clínica de la metástasis mandibular tiende a seguir algunas condiciones comunes como es el dolor de tipo dentario irradiado a la zona del tercer molar. El signo más frecuente de una metástasis mandibular es la parestesia en la zona de distribución del nervio dentario inferior. No obstante el diagnóstico y su terapéutica en estos pacientes puede ser difícil, debido a que los exámenes de diagnóstico pueden dar resultados confusos.

El objetivo de este artículo es realizar una revisión de la literatura a propósito de un caso de metástasis única mandibular de adenocarcinoma de próstata, considerando la expresión atípica de este tipo de metástasis, la poca información al respecto y la bajísima incidencia de esta lesión, poniendo énfasis en su etiología, comportamiento biológico y tratamiento.

**Palabras clave:** *Metástasis óseas maxilares, adenocarcinoma de próstata.*

## INTRODUCTION

Nearly 1% of all types of oral cancer are metastatic lesions of a primary tumor originating in another part of the body (1). There is a higher incidence of hard tissue lesions of metastatic tumors to the maxillofacial region than soft tissue lesions (2-6). The primary site of the tumor differs among genders. Breast cancer is the most frequent metastatic oral cancer in females and lung cancer followed by prostate cancer is the most frequent metastatic tumor in males. The most commonly affected bone in the maxillofacial region is the mandible and the most frequent location is the molar region. (1, 3, 6, 7).

In the majority of patients that present an oral metastasis, the primary tumor has generally been well diagnosed and treated. However in a small number of patients the oral metastasis represents the initial finding which ultimately leads to the detection of a hidden malignant lesion (6,7).

The frequency of metastatic oral lesions is low and is one of the reasons why it can present as a difficult diagnostic challenge (5-7). Extensive exams might be required which can delay the time between the initial detection of the disease and diagnosis of the metastasis. The presentation of mandibular metastasis follows a clinical pattern characterized by irradiated dental pain in the third molar region. Less frequently the lesion can present as pain in the temporomandibular joint region or as an osteomyelitis in the jaw or as trigeminal neuralgia (8). Clinical manifestations described by other authors, include a rapid development of swelling, pain and paresthesia. The most frequent sign of paresthesia in a mandibular metastasis is located in the area innervated by the mandibular alveolar dental nerve (1, 7-9). The increase in volume of the bone with a metastatic lesion, in some cases, is often associated with dental mobility and/or trismus (1,7,9).

In the majority of patients with mandibular metastasis of adenocarcinoma of the prostate gland radiographic examination reveals a radiopaque or a mixed image. In a minority of cases there is only a radiolucent zone or a complete lack of radiographic evidence. In some patients, an important finding is a pathological fracture (1, 7). Other complementary exams such as osseous scintigraphy, computerized tomography, single photon emission computed tomography (SPECT) are valuable tools in the early detection of a metastasis (8).

In some patients metastasis develops not only in the mandible but also in other parts of the body. In this situation, because of the severe spread of the disease, palliative treatment is the only option available to improve the immediate quality of life of these patients (6,9). If the oral tumor is diagnosed as the only metastatic lesion and the primary tumor is well identified and successfully treated, then a curative treatment can be considered for the oral metastasis (6). Most authors agree that the prognosis for this type of oral cancer is unfavourable (4-7, 9).

## CLINICAL CASE

A 68-year-old male was referred to San Borja Arriarán Hospital (Santiago, Chile) in December 2005. He presented with a dental history of 3 months of trismus of the masticatory muscles after extraction of tooth 4.7. Subsequent to the extraction the patient received treatment for post extraction socket inflammation. A few days afterwards the patient's condition worsened with more severe pain, difficulty in opening his mouth and an anesthesia sensation that increased progressively. The problem did not respond to pharmacological therapy.

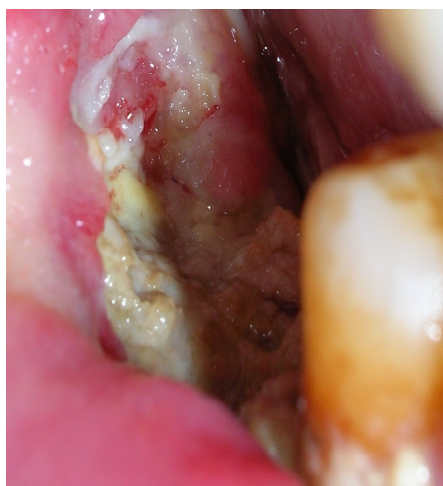The patient's medical history included controlled hypertension, alcoholism and chronic smoking with 7 years of abstinence. In 1998 he had a prostate biopsy by transrectal puncture which revealed a well differentiated adenocarcinoma histologically grade 1 on the Gleason scale. Patient rejected treatment for personal reasons, i.e., deficient information, depression and lack of confidence. In 2005 a new biopsy diagnosed the lesion histopathology as an infiltrating acinar adenocarcinoma grade 3 on the Gleason scale with a prostate-specific antigen of 23.33 ng/ml. The patient rejected all treatment options except for hormonal treatment of the prostate cancer.

Extraoral physical examination revealed a right perimandibular soft swelling. Vital signs were normal with hydrated skin and no neck adenopathy present. The intraoral physical examination revealed partially edentulous areas in both arches. He presented with limitation of mandibular opening and a soft end feel at 8mm. An exposed osseous lesion was identified in the mandible in relation to tooth 4.7 (Fig.1). The limits were found in the right retromolar trigone and part of the vertical ramus extending to tooth 4.5 which presented with grade 2 mobility. Vertically, the lesion went from the alveolar ridge, buccally, all the way down to the vestibule. Lingually, the highest part of the ridge was exposed, without compromising the floor of the mouth. The surrounding soft tissues i.e., gingiva, mucosa and buccal segments were hyperplastic and fibrous.

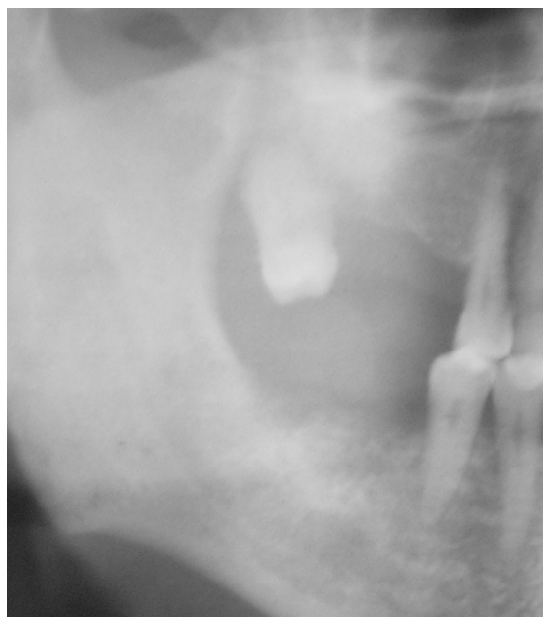Radiographically, an irregular ridge with recent osteolytic areas in relation to tooth 4.7 was seen in the Orthopantomography (Fig. 2). Computerized tomography (CT) only evidenced small irregular areas of osteoblastic calcification. In the scintigram with Tc99m MDP, the trace marker was intensively accumulated in both the prostate and horizontal right ramus of the mandible.

A core biopsy of hard and soft tissue was performed in the outpatient clinic under local anesthesia. Histopathological study of the lesion (Fig. 3) revealed an eroded mucosa with fragments of fibrous stroma infiltrated by solid groups and atypical cellular chains with some cells characterized by a clear cytoplasm and undergoing mitosis. Alveolar tissue was infiltrated by the adenocarcinoma and compatible with a prostatic origin. The immunohistochemical study confirmed the diagnosis, with a negative specific prostatic antigen and a positive acid prostatic phosphatase.

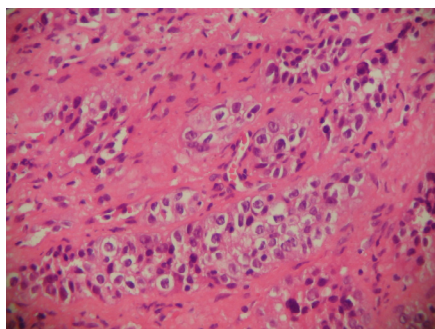
In regard to treatment of the metastasis, the patient was referred to the oncology department where he received mandibular radiotherapy. Unfortunately, he developed osteoradionecrosis resulting in a pathologic fracture of his mandible.



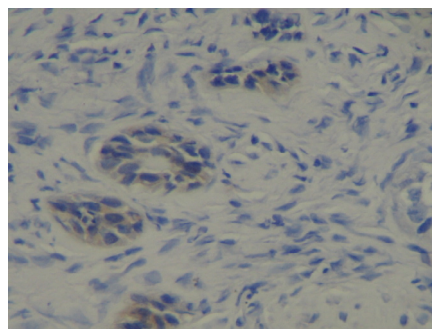
**Fig. 1.** Clinical aspect of the intraoral lesion. Osseous tissue lesion exposed to the oral cavity.



**Fig. 2.** Orthopantomography. Irregular osseous rim with areas of recent osteitis in relation to the tooth 4.7.



**A**



**B**

**Fig. 3.** A) Pathological anatomy. Stroma infiltrated by tubules and columns of atypical cells with clear cytoplasm and hyperchromatic nuclei. Hematoxylin-eosin stain, original augmentation 40X. B) Pathological anatomy. Immunohistochemistry, cytoplasmic stain of neoplastic cells with prostate acid fosfatase.

**DISCUSSION**

It is rare and unusual to find a mandibular unique metastasis in the most frequent cancerous lesions which affect the cranium and maxillofacial skeleton. When the metastasis is in the mandible, the primary tumor is frequently associated with a tendency to develop osseous metastasis (7, 8). The reported case, corresponds to a mandibular unique metastasis of a prostatic adenocarcinoma. Additional complementary exams confirmed that there were no other dissemination of the primary tumor; therefore this case is atypical, since whenever there is a mandibular metastasis, in general, other parts of the body are compromised with metastatic lesions as well (10).

Regarding the location of the lesion in the maxillofacial region, several authors describe the mandible as the most frequent site, followed by the maxilla and the bimaxillary lesion as the least common (7, 8). In the lower jaw, the molar area is affected with higher incidence. A previous study revealed that the presence of hematopoietic areas in the mandible favors the early deposit of hematopoietic cells (7, 11). This can, in part, explain why the most frequent site for the development of this mandibular metastasis is the molar area (7), which applies in this case. In the majority of the cases, the metastasis is found in the extraction site, with a latency period of 2 months between the extraction and the development of the metastasis (7). The same authors

determined there is no significant difference in the location of the oral metastasis between genders and age variable. The only difference is the most frequent type of primary tumor which differs in each gender. This case corresponds to a mandibular unique metastasis of a prostatic adenocarcinoma, located in the mandible in a 68-years-old male following molar extraction (tooth 4.7). The time elapsed between the extraction and the appearance of the metastasis was around 1 month. Due to these characteristics it is hard and unpredictable to diagnose the metastasis.

Regarding the clinical characteristics of the disease, swelling, pain, and anaesthesia sensation in the buccal mandibular region are the most frequent signs and symptoms. In this case, we can comment the patient had pain episodes before the extraction, which with time evolved into stabbing pain, irradiated to the ipsilateral joint. He presented anaesthetic sensation, all the way to the chin and persistent trismus, which did not respond to pharmacological therapy. Intraoral perifocal tissues were infiltrated, microscopically presenting atypical cells and mitosis with a pattern of adenocarcinoma.

Radiographically, this lesion does not always present with the same appearance (6,7,12). The majority of patients present a radiopaque or a mixed image and a minority of the cases a radiolucent zone or even a lack of radiographic evidence at all. In this case, an irregular osseous tissue with recent osteolysis was the radiographic expression of the lesion. This difference complicated diagnosis, since other metastasis of primary tumors have more radiographic pathognomonic typical signs that can ultimately lead to a more precise diagnosis, such as the clear cells tumor in the metastasis of kidney cancer.

The histological study Hematoxylin-eosin staining revealed the presence of atypical cells and mitosis together with alveolar tissue infiltrated with adenocarcinoma, compatible with prostatic origin. An immunohistochemical study was performed to confirm diagnosis. Results were negative to specific prostatic antigen and a positive acid prostatic phosphatase. This information confirmed the diagnosis, clearly demonstrating the presence of a malignant tumor. Nevertheless, this case required additional tests to clarify the origin of the primary lesion (13).

Local treatment of the mandibular metastasis generally requires radiotherapy, which usually decreases pain and prevents the functional loss (6, 9). Generally, prognosis in these patients is negative (5, 6, 9). In the reported case it is relevant to mention there was no treatment for the primary cancer. This is reflected when comparing results of 2005 for the prostatic antigen and histopathology Gleason Scale classification with the initial exam in 1997. The lack of treatment for the primary tumor complicated the treatment of the metastasis, ultimately leading to apply only a palliative therapy.

The incidence of metastatic diseases that affect the mandible is still unknown. Dentists should consider in their general physical exam the suspicion of a mandibular metastasis in cases with atypical symptoms, especially in patients with a well known malignant disease.

## REFERENCES

1. Valdivieso M, Ostria J, Lobos N. Oral and maxillofacial metastases of neoplasms from other sites of the body. *Med Oral*. 1999 Nov;4(5):583-7.
2. Hirshberg A, Buchner A. Metastatic tumours to the oral region. An overview. *Eur J Cancer B Oral Oncol*. 1995 Nov;31B(6):355-60.
3. Morishita M, Fukuda J. Hepatocellular carcinoma metastatic to the maxillary incisal gingiva. *J Oral Maxillofac Surg*. 1984 Dec;42(12):812-5.
4. Zachariades N, Koumoura F, Vairaktaris E, Mezitis M. Metastatic tumors to the jaws: a report of seven cases. *J Oral Maxillofac Surg*. 1989 Sep;47(9):991-6.
5. Piattelli A, Fioroni M, Rubini C. Gingival metastasis from a prostate adenocarcinoma: report of a case. *J Periodontol*. 1999 Apr;70(4):441-4.
6. Van der Waal RI, Buter J, Van der Waal I. Oral metastases: report of 24 cases. *Br J Oral Maxillofac Surg*. 2003 Feb;41(1):3-6.
7. Hirshberg A, Leibovich P, Buchner A. Metastatic tumors to the jawbones: analysis of 390 cases. *J Oral Pathol Med*. 1994 Sep;23(8):337-41.
8. Glaser C, Lang S, Pruckmayer M, Millesi W, Rasse M, Marosi C, et al. Clinical manifestations and diagnostic approach to metastatic cancer of the mandible. *Int J Oral Maxillofac Surg*. 1997 Oct;26(5):365-8.
9. Lossos A, Siegal T. Numb chin syndrome in cancer patients: etiology, response to treatment, and prognostic significance. *Neurology*. 1992 Jun;42(6):1181-4.
10. Cash CD, Royer RQ, Dahlin DC. Metastatic tumors of the jaws. *Oral Surg Oral Med Oral Pathol*. 1961 Aug;14:897-905.
11. Hashimoto N, Kurihara K, Yamasaki H, Ohba S, Sakai H, Yoshida S. Pathological characteristics of metastatic carcinoma in the human mandible. *J Oral Pathol*. 1987 Aug;16(7):362-7.
12. Bucin E, Andreasson L, Bjorlin G. Metastases in the oral cavity. Case reports. *Int Oral Surg*. 1982 Oct;11(5):321-5.
13. Foster Ch, Bostwick D. Pathology of the prostate. Mayor pathology problems vol. 34. Philadelphia: WB Saunders Comp; 1998.