

Osteochondroma of the coronoid process

Julio Villanueva ^{1,2}, Andrea González ^{1,2}, Marco Cornejo ^{1,3}, Cristián Núñez ^{1,2}, Susana Encina ^{1,2}

(1) Servicio de Cirugía Máxilo Facial. Hospital Clínico San Borja Arriarán

(2) Departamento de Cirugía Máxilo Facial. Facultad de Odontología. Universidad de Chile

(3) Departamento de Radiología. Facultad de Odontología. Universidad de Chile

Correspondence:

Dr. Julio Villanueva Maffei

Santa María 571, Recoleta

Chile

E-mail: javm@vtr.net

Received: 23-05-2004

Accepted: 16-10-2005

Villanueva J, González A, Cornejo M, Núñez C, Encina S. Osteochondroma of the coronoid process. *Med Oral Patol Oral Cir Bucal* 2006;11: E289-91.

© Medicina Oral S. L. C.I.F. B 96689336 - ISSN 1698-6946

[Click here to view the article in Spanish](#)

Indexed in:

-Index Medicus / MEDLINE / PubMed
-EMBASE, Excerpta Medica
-Índice Médico Español
-IBECS

ABSTRACT

Osteochondroma is the most common benign neoplasia of the skeleton. In the head it was been described in cranial base, posterior maxillary surface, maxillary sinus, and different mandibular areas like condyle, ramus, body and symphysis. Osteochondroma of the coronoid process are rare.

We present a review of the literature and the report of the cas of a 44 years old female patient presenting limited mouth opening and swelling of the left cheek, with diffuse limits, bony consistency, painless, and covered of normal skin. No temporomandibular joint disease was present.

In panoramic radiographs was evident a coronoid tumor localized in the union of zygomatic arch and bone.

Under general anaesthesia coronoidectomy was made, recovering mouth opening until 43 mm. The post-operative period was performed without complications.

Histopathological examinations revealed normal trabecular bone covered with hyaline cartilage. The histopathological diagnosis was osteochondroma.

Clinical and pathological aspects, treatment and differential diagnosis with other lesions are discussed.

Key words: *Osteochondroma, chondroma, Jacob's disease.*

RESUMEN

El osteocondroma es la neoplasia benigna más común del esqueleto. En la cabeza se ha descrito su localización en base de cráneo, cara posterior del maxilar, senos maxilares, y en diferentes áreas de la mandíbula, como cóndilo, rama, cuerpo y región sinfisiaria, siendo los osteocondromas coronoideos de baja frecuencia.

Presentamos una revisión de la literatura y el informe de un nuevo caso. Una mujer de 44 años que consulta por limitación de la apertura bucal y deformidad en la mejilla izquierda, de límites difusos, consistencia ósea, indolora y cubierta por piel de aspecto normal. No presentaba patología en la articulación temporomandibular.

En la radiografía panorámica se evidencia un tumor coronoideo localizado en la zona de unión del arco cigomático y el hueso malar.

Se realizó la coronoidectomía bajo anestesia general, recuperándose inmediatamente la apertura bucal hasta 43 mm. El postoperatorio se desarrolló sin complicaciones.

El estudio histopatológico reveló hueso esponjoso normal sobre el cual se encontró cartílago hialino. El diagnóstico fue osteocondroma.

Los aspectos clínicos y patológicos, su tratamiento y diagnóstico diferencial son discutidos.

Palabras clave: *Osteocondroma, condroma, enfermedad de Jacob.*

INTRODUCTION

Osteochondroma is the most common benign neoplasia of the skeleton. It is more frequently found in long bones due to the endochondral growth . It has been described in the head, on the cranial base, jaw, maxillary sinuses, condyle, ramus, body and symphyseal mandibular region. Coronoid process is a low frequent site. This benign tumor grows slowly. Distinctive signs are limited mouth opening and facial deformity. For diagnosis a panoramic radiograph and CT scan are useful in order to visualize the existing relations between the zygomatic arch and the coronoid process. Histologically, most of the lesions show growing bone surrounded by cartilages. There are just fifteen cases of coronoid osteochondroma in the related literature (4,5). The aim of this article is to present a case of an osteochondroma of the coronoid process.

CLINICAL CASE

A forty-four age female patient, sent to our unit due to a zygomatic region swelling and progressive limitation of mouth opening during the ten past months. No relevant medical history. Extraoral physical exam shows facial asymmetry due to left cheek swelling (Figure 1), with diffuse limits, osseous consistence with no pain, and normal skin aspect. 30 mm. mouth opening. Normal temporomandibular joint (TMJ). There was no noise or pain when opening. A large coronoid process was observed in the panoramic X ray (figure 2). The hypothesis was “Coronoid Tumor”. An incision was performed on the anterior border of the mandibular ramus, extracting all the inserts of the temporal muscle. A fibrous pseudo capsule was found around the mass and was released. Coronoidectomy was performed. Mouth opening was recovered up to 43 mm immediately. The follow up recovery time developed without complications and the patient was discharged 48 hours after the surgical procedure.

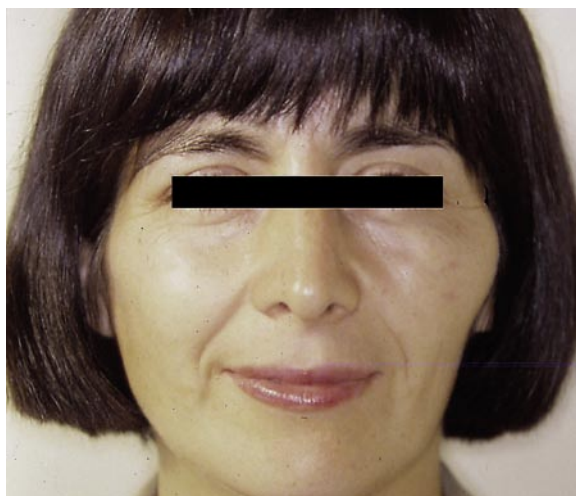

Fig. 1. Facial asymmetry due to left cheek swelling.

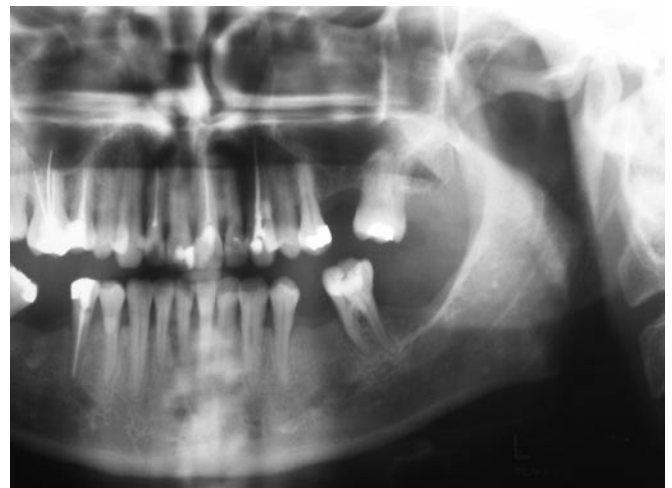

Fig. 2. A large coronoid process was observed.

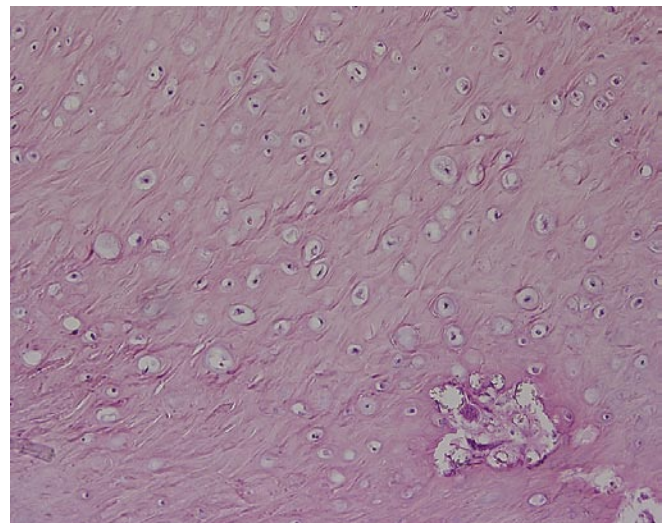


Fig. 3. Histological study: presence of fibers, neoformative bone and cartilaginous hyaline tissue.

Histopathologic study reported the presence of fibers, neoformative bone and cartilaginous hyaline tissue (Figura 3). The diagnosis was Osteochondroma.

She presented a non complicated follow up. Definitive discharge was after ten months, with recovering normal cheek contour.

DISCUSSION

Osteochondroma is low frequent pathological entity. Mouth opening limitation consecutive to it is associated to the dysfunctional pathology of tempomandibular articulation, as shown in the consulted literature (6). Solitary osteochondroma is an exophytic lesion of the bone that presents variable quantities of cartilaginous tissue whose clinical aspect resembles a mandibular condyle (2). Sometimes, cartilaginous

and osseous tissues present an active development, whereas in some other cases such development is diminished. Due to this variability, this lesion has received different names, such as “osteocartilaginous exostosis” or “osteochondroma”. Deformity of nearby structures was reported in a 60%. Several theories have been proposed to explain its etiology. Weinmann y Sicher (7) propose that the continuous activity of tendons inserted in the coronoids stimulates a hyperplastic development of embryonic cells with chondrogenic potential. Lichtenstein (1) proposes the periost to have pluripotentiality to produce cartilage and osseous tissue. Other causes could be trauma and functional alterations in shaped and structure of coronoid process. However, it has not been concluded whether Osteochondroma is a neoplasia (8-11) or an osseous repair.

Independently from etiology, the treatment's goal will be to recover acceptable mouth opening ranges. In cases of limited mouth opening due to coronoid process, the patient presents complaint in that region, more than in the TMJ. Next, the dynamic mandibular evaluation is performed.

As complement to the clinical exam an X ray is helpful in assessing a diagnoses for this pathology. Although Water's radiograph is useful to show coronoid hyperplasia and its relation to the zygoma, tridimensional reconstruction is essential to complete the diagnosis, determine tumor's size, its relation to near structures, and planning the surgery (2, 3, 6).

Until 1961, almost all reported tumors were enucleated via zygomatic facial approach, with or without separation of the zygomatic arch. Using this approach the facial nerve is in risk, an remaining as well an unacceptable, non esthetic scar(3).

Intraoral approach is the most used, for safety and facilitates the complete removal of the tumor. Its advantage is provide direct access to the lesion without facial nerve injuries or aesthetic alteration (3, 6).

Other possibility are extraoral approaches such as submandibular or coronal approach(6, 13). Disadvantages of this approaches are the mandibular nerve injury and submandibular scar. In cases of large coronoid process trapped in the zygomatic arch, the resection must be done by coronal approach, with the advantage of better visualization and esthetic scar within the line of hair. In addition, temporal muscle flap can be used when requiring TMJ reconstruction during the same surgery (3, 6).

Concerning the treatment, there is agreement on the only therapeutic alternative, that is based on surgical removal without reconstruction. In contrast to mandible condylar osteochondroma that do require reconstruction, most of the cases the coronoidectomy doesn't show recurrence (6).

Our case presents the features of coronoid process osteochondromas. However, there are differences worth to take into consideration: our patient seeks advice at the age of forty-four, a rare age for this kind of lesions with no articular pathology. We cannot be accurate about the etiology of this neoplasia, but we can fasten that she presented a very active development in contrast to most of the cases seen in literature.

Concerning the radiographic features of this case, we choose an extraoral approach that gave us a proper field for the coronoidectomy., used in the majority of the reported cases in the reviewed literature.

REFERENCES

1. Lichtenstein L. Bone tumors. St. Louis: CV Mosby; 1977. p. 17-29.
2. Kerscher A, Piette E, Tideman H, Wu PC. Osteochondroma of the coronoid process of the mandible: report of a case and review of the literature. *Oral Surg Oral Med Oral Pathol* 1993;75: 559-64.
3. Hernández-Alfaro F, Escudero O, Marco V. Joint formation between an osteochondroma of the coronoid process and the zygomatic arch (Jacob disease): report of case and review of the literature. *J Oral Maxillofac Surg* 2000;58:227-32.
4. Allan IM, Reid WH. Unilateral exostosis of the coronoid process of the mandible. *Br J Oral Surg* 1967;5:20-4.
5. Cooper JC, Finch LD. Coronoid osteochondroma presenting as a coronozygomatic ankylosis: a case report. *Br Dent J* 1974;137:99-102.
6. Ufuk E, Alp A, Defne O, Orhan C, Misten D. Osteochondroma of the coronoid process (Jacob's disease). *J Oral Maxillofac Surg* 2002;60:1354-6.
7. Weinmann JP, Sicher H, eds. Bone and bones: fundamentals of bone biology. St. Louis: CV Mosby; 1995. p. 88-126.
8. Shackelford RT, Brown WH. Restricted jaw motion due to osteochondroma of the coronoid process. *J Bone Joint Surg* 1949;31:107-14.
9. Antoni AA, Brown A, Johnson JH. Osteochondroma of the coronoid process of the mandible: report of case. *J Oral Surg* 1958;16:514-7.
10. Meyer RA. Osteochondroma of coronoid process of mandible: report of case. *J Oral Surg* 1972;30:297-300.
11. Totsuka Y, Fukada H, Iizuka T, Shindoh M, Amemiya A. Osteochondroma of the coronoid process of the mandible; review of a case showing histological evidence of neoplasia. *J Craniomaxillofac Surg* 1990;18:27-32.
12. Brady FA, Sapp JP, Christensen RE. Extracondylar osteochondromas of the jaws. *Oral Surg Oral Med Oral Pathol* 1978;46:658-68.
13. Jacob O. Une cause rare de contraction permanente des machaires. *Bull et Mem de la Société Anatomique de Paris* 1889;8: 917.