

Bisphosphonate-associated osteonecrosis of the jaw. A proposal for conservative treatment

Sacramento Bocanegra Pérez ¹, Mario Vicente Barrero ², Manuel Sosa Hernández ³, Milan Knezevic ⁴, José María Castellano Navarro ⁵, José Rodríguez Millares ⁶

(1) Surgeon-stomatologist

(2) Surgeon-stomatologist. Associate Professor

(3) Full Professor of general pathology

(4) Specialist in oral and maxillofacial surgery

(5) Medical doctor and odontologist

(6) Registered nurse

Hospital Universitario Insular. Centro de Ciencias de la Salud. Las Palmas de Gran Canaria

Correspondence:

Dr. Mario Vicente Barrero

c/ Alcalde Henríquez Pitti 13, 1^o izq

35400- Arucas, Las Palmas

mmvicente@wanadoo.es

Received: 05/02/2008

Accepted: 06/06/2008

Indexed in:

- Science Citation Index Expanded
- Journal Citation Reports
- Index Medicus, MEDLINE, PubMed
- Excerpta Medica, Embase, SCOPUS,
- Índice Médico Español

Bocanegra-Pérez S, Vicente-Barrero M, Sosa-Hernández M, Knezevic M, Castellano-Navarro JM, Rodríguez-Millares J. Bisphosphonate-associated osteonecrosis of the jaw. A proposal for conservative treatment. Med Oral Patol Oral Cir Bucal. 2008 Dec 1;13(12):E770-3. © Medicina Oral S. L. C.I.F. B 96689336 - ISSN 1698-6946 <http://www.medicinaoral.com/medoralfree01/v13i12/medoralv13i12p770.pdf>

Abstract

The use of bisphosphonates (BPs) has proven effective in the treatment of bone-related diseases, despite the potential risk of developing osteonecrosis of the jaw (ONJ). So far, results for the treatment of ONJ have not been satisfactory. In our study, we have treated two patients diagnosed with ONJ. In addition to local treatments a hydrogel was applied, with promising results. The fistulae disappeared 2-3 weeks into the treatment. After a six-month follow-up period there has been no sign of recurrence. The extent of maxillary bone exposure has diminished notably, although not entirely disappeared. In all cases, the patients exhibit no other symptoms (they suffer from no pain or swelling or functional impotence). For this reason we believe this protocol might be useful in the case of patients who suffer from pain and fistulation secondary to BP-associated ONJ to improve the state of their lesions until definitive treatment can be undertaken.

Although these findings are not conclusive, given that we are reporting data on two patients only, we believe that this might be an alternative treatment in refractory cases where other therapies are counter-indicated. A controlled randomized and prospective study would be required to confirm our findings.

Key words: Maxillary osteonecrosis, bisphosphonates, zoledronic acid, zoledronate, extraoral fistulation.

Introduction

Bisphosphonates (BPs) are powerful inhibitors of osteoclast activity, and via interaction with these cells bring about a reduction in bone resorption. In the case of patients suffering from cancer, the most frequently used BPs are pamidronate and zoledronic acid; commonly used in the treatment of malignant hypercalcemia, multiple myeloma and bone metastases from solid tumours

(breast, prostate and lung) in association with specific antineoplastic therapy.

Some patients suffering from multiple myeloma, breast or prostate cancer under treatment with pamidronate or intravenous zoledronic acid have exhibited a clinical picture of intraoral bone necrosis, spontaneously produced after dental extraction or oral trauma. These patients had not been treated with head or neck radiotherapy. These

oral lesions are known as BP-associated osteonecrosis of the jaw (ONJ), and are a new significant complication in BP-associated adjuvant treatment.

So far, their treatment has been controversial since there are different patterns and they do not respond to medical and/or surgical treatments.

In this paper we propose a possible conservative treatment of ONJ lesions, especially of cutaneous fistulae, by means of local treatments and the application of a hydrogel with alginate (Nu-Gel®).

Clinical Cases

BF-associated ONJ treatment was undertaken on two patients transferred from the Oncological Department to the Stomatological, Oral and Maxillofacial Surgery Department of the Hospital Universitario Insular de Las Palmas de Gran Canaria. Both suffered from oral bone exposure and fistulae in the submentonian region. Since there was no agreement concerning adequate treatment, a conservative treatment was administered by the following protocol:

1. Oral antibiotherapy:

- Amoxicillin/Clavulanic acid 1000/62.5 milligrams (Augmentine Plus®), 2 tablets/day for 30 days.
- Metronidazole 250 milligrams (Flagyl®), 2 tablets every 8 hours, for 10-20 days.

2. Oral rinsing with 0.12% chlorhexidine mouthwash (Bexident Gums®), 3-4 times a day.

3. Local treatment of fistulae by means of:

- Rinsing lesions with physiological serum.
- 4 ml irrigation solution for the intravenous perfusion of ciprofloxacin 2 mg/ml (Normon)
- Application of hydrogel with alginate (Nu-Gel®).

This treatment was performed daily until the fistulae healed. Later weekly check-ups were carried out during the follow-up period.

- Case 1

The patient was a 47 year-old male smoker, diagnosed 20 months earlier with poorly differentiated adenocarcinoma of the prostate with bone involvement. Under treatment with zoledronate for 20 months, with a total dose received of 80 mg. With a history of tooth 35 radicular remains removal 12 months before, which despite treatment did not heal despite the antibiotic treatment prescribed. He suffered from mucous ulceration, halitosis, bad taste in mouth, fever, nausea, exposed bone, mobility of tooth 34 and fistulae in the area surrounding tooth 44 and in the submentonian region. (Figures 1-4). Biopsy with no evidence of carcinomatous infiltration, with acute nonspecific chronic inflammatory signs.

Treatment was initially administered by the protocol described above, with local daily treatment from Monday to Saturday over a period of two weeks. The hydrogel was injected into the cutaneous fistula until its intraoral exit was verified on both sides. After two weeks the fistulae had

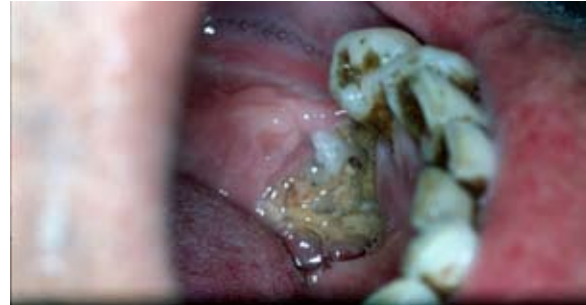

Fig. 1. Exposed bone in the area surrounding tooth 34.

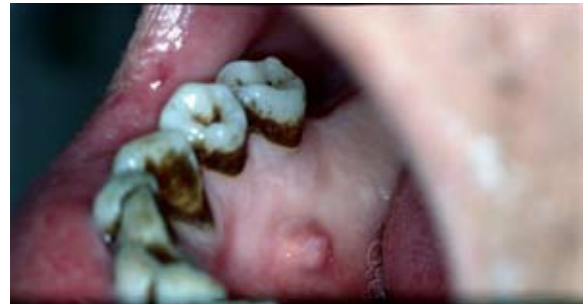

Fig. 2. Mucous fistulae.

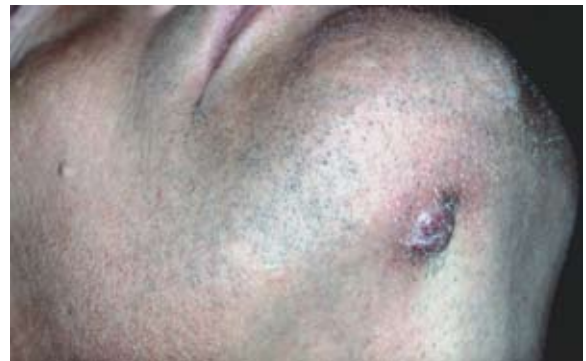

Fig. 3. Fistula in the submentonian region.

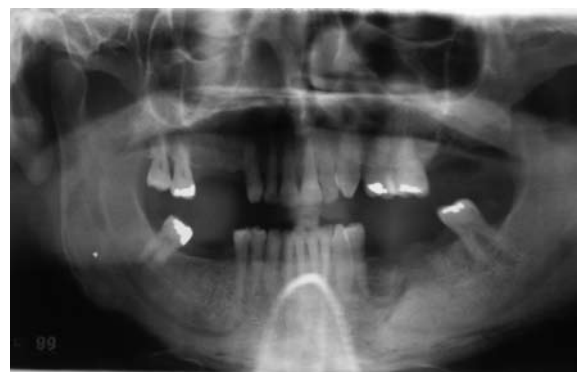

Fig. 4. Orthopantomography of the case 1.

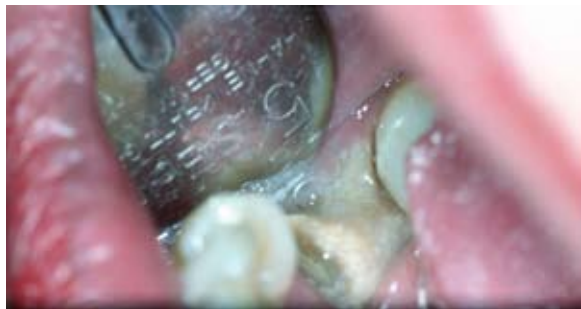


Fig. 5. Bone exposure in an area close to teeth 45-46.

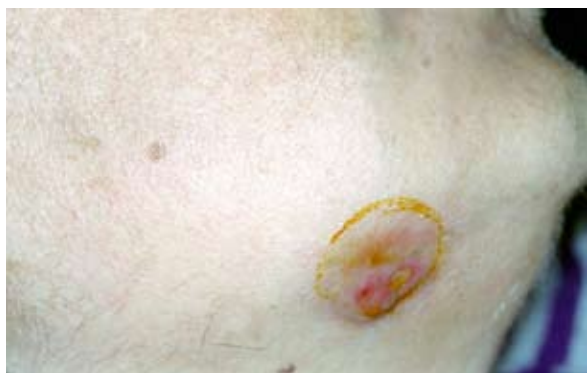

Fig. 6. Fistula in the submandibular region.

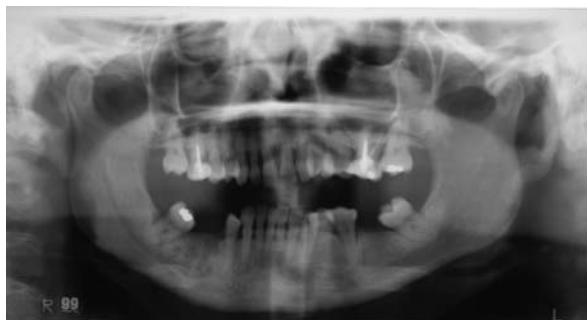

Fig. 7. Orthopantomography of the case 2.

healed. Currently, after a 7-month follow-up period, there has been no sign of fistulae recidivation and, although the bone is still exposed in the mouth, there is no pain or suppuration. The prosthesis does not cause any discomfort and he can eat without difficulty. He still smokes. He is not taking antibiotics and is reinforcing his oral hygiene with a chlorhexidine mouthwash.

- Case 2

A 42-year-old female diagnosed 7 years previously with infiltrating ductal carcinoma of the left breast. She also suffers from bone, hepatic and pleuropulmonary metastasis. She was treated with zoledronate (for 18 months, with a total dose received of 72 mg). She reported that 6 months ago she suffered from pain and swelling in the

area surrounding tooth 45, with no predisposing factors. Later her face swelled and she suffered from very fetid suppuration in the right mandibular region. Two months prior to coming to our department she spontaneously lost tooth 45. On examination, bone exposure was revealed in an area close to teeth 45-46. Clinically, she also suffered from paresthesiae, suppuration and fistula in the submandibular region which, though not painful, made eating difficult. (Figures 5-7).

Bone gammagraphy images reveal in relation to the ONJ diagnosis a focal pathological accretion in the right hemimandible. After three weeks of treatment by the protocol described the fistula had healed. Currently, after a six-month follow-up period, the patient reports clinical improvement, the fistula has not recurred and, although the bone is still exposed in the mouth, there is no pain and she has less difficulty in eating. She continues with intermittent antibiotic cycles (Amoxicillin/Clavulanic acid) rinsing her mouth with chlorhexidine.

Discussion

BF-associated ONJ is a recently described entity with numerous series and cases published (1-3).

The panels of experts constituted so far, representing the American Dental Association, the American Association of Oral and Maxillofacial Surgeons, the American Society for Bone and Mineral Research, the American Academy of Oral Medicine and the Spanish expert panel (4-8) agree on the fact that the exact incidence and risk posed by ONJ has not yet been established, and that there is no specific guide regarding the handling of patients treated with BP.

Many clinical protocols have been proposed, with irregular results. Radical surgical resections have not been effective and have even worsened the course of the disease. (2, 6, 9-11). Surgical debridement has not been successful either regarding the eradication of necrotic bones, and hyperbaric oxygen therapy has not been able to limit the progress of the disease. (1, 2, 6, 12, 13). Most authors, consequently, propose strictly conservative treatments when dealing with ONJ. (1, 14).

In our patients' case, we have followed the recommendations of the expert committees (4-8) regarding the administration of antiseptic mouthwashes, antibiotherapy by general route, but to this strategy we have added irrigation with antibiotics (ciprofloxacin) and the local application of a hydrogel. Nu-Gel® is an amorphous hydroactive gel that contains sodium alginate. This hydrogel is normally indicated for the debridement and reduction of ulcer exudates and for the treatment of chronic ulcers in all stages of healing. On the fistulae we have used the method described above, with successive applications of physiological serum, irrigation with ciprofloxacin in order to achieve a DNA gyrase enzyme-inhibiting bactericidal effect against a wide range of bacteria (15) and, finally, Nu-Gel is applied directly inside the fistula through the tube nozzle.

Oral and cutaneous fistulae disappeared after 2-3 weeks of treatment. After a six-month follow-up period there has been no sign of recurrence. Although it has not entirely disappeared, the extent of maxillary bone exposure has notably diminished. In no cases, do the patients exhibit any other symptoms, such as pain, swelling or functional impairment. For this reason, we believe this protocol might be useful in the case of patients who suffer from pain and fistulation secondary to BP-associated ONJ to improve the state of their lesions until definitive treatment can be undertaken.

References

1. Ruggiero SL, Mehrotra B, Rosenberg TJ, Engroff SL. Osteonecrosis of the jaws associated with the use of bisphosphonates: a review of 63 cases. *J Oral Maxillofac Surg.* 2004 May;62(5):527-34.
2. Marx RE, Sawatari Y, Fortin M, Broumand V. Bisphosphonate-induced exposed bone (osteonecrosis/osteopetrosis) of the jaws: risk factors, recognition, prevention, and treatment. *J Oral Maxillofac Surg.* 2005 Nov;63(11):1567-75.
3. Migliorati CA, Schubert MM, Peterson DE, Seneda LM. Bisphosphonate-associated osteonecrosis of mandibular and maxillary bone: an emerging oral complication of supportive cancer therapy. *Cancer.* 2005 Jul 1;104(1):83-93.
4. American Dental Association Council on Scientific Affairs. Dental management of patients receiving oral bisphosphonate therapy: expert panel recommendations. *J Am Dent Assoc.* 2006 Aug;137(8):1144-50.
5. Advisory Task Force on Bisphosphonate-Related Osteonecrosis of the Jaws, American Association of Oral and Maxillofacial Surgeons. American Association of Oral and Maxillofacial Surgeons position paper on bisphosphonate-related osteonecrosis of the jaws. *J Oral Maxillofac Surg.* 2007 Mar;65(3):369-76.
6. Migliorati CA, Casiglia J, Epstein J, Jacobsen PL, Siegel MA, Woo SB. Managing the care of patients with bisphosphonate-associated osteonecrosis: an American Academy of Oral Medicine position paper. *J Am Dent Assoc.* 2005 Dec;136(12):1658-68.
7. Khosla S, Burr D, Cauley J, Dempster DW, Ebeling PR, Felsenberg D, et al. Bisphosphonate-associated osteonecrosis of the jaw: report of a task force of the American Society for Bone and Mineral Research. *J Bone Miner Res.* 2007 Oct;22(10):1479-91.
8. Bagán J, Blade J, Cozar JM, Constela M, García Sanz R, Gómez Veiga F, et al. Recommendations for the prevention, diagnosis, and treatment of osteonecrosis of the jaw (ONJ) in cancer patients treated with bisphosphonates. *Med Oral Patol Oral Cir Bucal.* 2007 Aug 1;12(4):E336-40.
9. Pires FR, Miranda A, Cardoso ES, Cardoso AS, Fregnani ER, Pereira CM, et al. Oral avascular bone necrosis associated with chemotherapy and bisphosphonate therapy. *Oral Dis.* 2005 Nov;11(6):365-9.
10. Farrugia MC, Summerlin DJ, Krowiak E, Huntley T, Freeman S, Borrowdale R, et al. Osteonecrosis of the mandible or maxilla associated with the use of new generation bisphosphonates. *Laryngoscope.* 2006 Jan;116(1):115-20.
11. Ficarra G, Beninati F, Rubino I, Vannucchi A, Longo G, Tonelli P, et al. Osteonecrosis of the jaws in periodontal patients with a history of bisphosphonates treatment. *J Clin Periodontol.* 2005 Nov;32(11):1123-8.
12. Heras Rincón I, Zubillaga Rodríguez I, Castrillo Tambay M, Montalvo Moreno JJ. Osteonecrosis of the jaws and bisphosphonates. Report of fifteen cases. Therapeutic recommendations. *Med Oral Patol Oral Cir Bucal.* 2007 Aug 1;12(4):E267-71.
13. Woo SB, Hellstein JW, Kalmar JR. Narrative [corrected] review: bisphosphonates and osteonecrosis of the jaws. *Ann Intern Med.* 2006 May 16;144(10):753-61.
14. Migliorati CA, Siegel MA, Elting LS. Bisphosphonate-associated osteonecrosis: a long-term complication of bisphosphonate treatment. *Lancet Oncol.* 2006 Jun;7(6):508-14.
15. Alós JJ. Quinolones. *Enferm Infecc Microbiol Clin.* 2003 May;21(5):261-7.