

Repositioning of the inferior alveolar nerve in cases of severe mandibular atrophy. A clinical case

José Luis Del-Castillo-Pardo-de-Vera ¹, Manuel Chamorro-Pons ², José Luis Cebrián-Carretero ¹

(1) Staff physician. Department of Oral and Maxillofacial Surgery. La Paz University Hospital. Madrid (Spain)

(2) Clinical chief. Department of Oral and Maxillofacial Surgery. La Paz University Hospital. Madrid (Spain)

Correspondence:

Dr. José Luis Del Castillo-Pardo de Vera
Servicio de Cirugía Oral y Maxilofacial
Hospital Universitario La Paz
Paseo de la Castellana 261
28046 – Madrid (Spain)
delcastillo6@hotmail.com

Received: 05/10/2007
Accepted: 24/09/2008

Del-Castillo-Pardo-de-Vera JL, Chamorro-Pons M, Cebrián-Carretero JL. Repositioning of the inferior alveolar nerve in cases of severe mandibular atrophy. A clinical case. Med Oral Patol Oral Cir Bucal. 2008 Dec 1;13(12):E778-82.

© Medicina Oral S. L. C.I.F. B 96689336 - ISSN 1698-6946

<http://www.medicinaoral.com/medoralfree01/v13i12/medoralv13i12p778.pdf>

Indexed in:

- Science Citation Index Expanded
- Journal Citation Reports
- Index Medicus, MEDLINE, PubMed
- Excerpta Medica, Embase, SCOPUS,
- Índice Médico Español

Abstract

Implant-based rehabilitation of edentulous mandibular posterior sectors tends to be complicated by the presence of bone atrophy.

Following tooth loss, cortical bone suffers greater resorption on the vestibular than on the lingual aspect, and patients typically present narrow and low alveolar crests. In cases of moderate to severe mandibular atrophy, the bone height between the alveolar crest and the dental canal is small, and sometimes limited to only a few millimeters.

Implant placement in such situations is very difficult, and implies the risk of inferior alveolar nerve damage. In certain cases bone grafting may be considered to restore the alveolar crest.

We present a case of severe mandibular atrophy in which inferior alveolar nerve repositioning and implant placement were carried out. Such nerve repositioning may constitute a treatment alternative in patients with severe posterior sector mandibular atrophy and a consequent risk of dental nerve damage during the placement of dental implants.

Key words: *Edentulism, inferior alveolar nerve, dental implants.*

Introduction

In patients with limited alveolar crest height in edentulous posterior sectors of the mandible, different osseointegrated implant-based rehabilitation techniques can be used: placement of a bone graft in the alveolar crest, alveolar distraction, and inferior alveolar nerve repositioning.

The first of these techniques poses major inconveniences associated with the need for graft harvesting (generally from some extraoral location) – a procedure usually involving general anesthesia, hospital admission and a prolonged treatment duration. In addition, the resulting alveolar crest augmentation is difficult to predict with this technique. Osteogenic distraction of the alveolar crest is a versatile procedure that has become increasingly popular

in recent years, particularly in application to the anterior mandibular zone. In some cases the technique can be performed under local anesthesia, and it requires no graft harvesting – though strict patient cooperation and several surgical steps are required (1-4). In certain selected cases, inferior alveolar nerve repositioning can be carried out under local anesthesia and/or sedation, though general anesthesia is usually needed. The technique makes it possible to place the dental implants in the same surgical step. However, nerve repositioning is a complex procedure, with a high risk of sensory disturbances (anesthesia, paresthesia or neuralgia, mostly of a transient nature, but sometimes permanent)(5,6).

The inferior alveolar or dental nerve is the most volumi-

nous branch of the mandibular nerve. It penetrates the mandibular canal accompanied by the corresponding blood vessels, forming the inferior dental plexus, from which innervation in turn emerges for the teeth and gingival tissue. The trajectory finally gives rise to the mental nerve, which may innervate the incisors and canines before emerging to the exterior (7).

The first case of inferior alveolar nerve repositioning was published in 1977 by Alling (8), in the context of prosthetic rehabilitation in patients with severe atrophy and emergence of the nerve close to the alveolar crest. However, the first case of repositioning in the context of osseointegrated implant placement was described by Jensen and Nock (9) in 1987, with normalization of sensory function 5 weeks after surgery.

Lateralization of the inferior alveolar nerve offers the following advantages:

- * Implants of greater length can be placed in the same surgical step.
- * Greater primary implant stability is afforded thanks to the possibility of bicortical mandibular fixation (9-11).
- * Only a physical examination and simple radiological study (e.g., panoramic X-rays) are needed.
- * Increased protection of the dental neurovascular bundle is afforded during implant placement (12-14).
- * No bone grafting is needed, and donor site morbidity is avoided.

Surgical Technique

Two inferior alveolar nerve repositioning techniques have been developed: lateralization and fenestration. Both procedures begin with local infiltrating anesthesia in the form of lidocaine plus vasoconstrictors. An incision measuring about 5 mm is then made vestibular below the alveolar crest, with a vestibular releasing incision ahead of the mental foramen. The flaps are raised, one lingual to access the alveolar crest, and another vestibular for subperiosteal dissection of the inferior alveolar nerve, until an ample surgical field is obtained.

From this point onwards, the two surgical techniques are differentiated as described below.

- Lateralization

An osteotomy is performed at the mental foramen, drilling around the orifice to obtain a ring of external cortical bone. A window also may be made extending about 5 mm ahead of the foramen, in order to avoid damaging the nerve over its anterior curvature. An en bloc osteotomy is then made at external cortical level, or a posterior window is performed in the external cortical layer along the intrabony trajectory of the nerve. A round drill is used to perform the window, replacing it with a diamond drill on working close to the canal, to minimize the risk of nerve damage (Fig. 1-A).

In order to secure complete mobilization of the alveolar nerve, the incisor branch located about 5 mm from the

foramen must be sectioned. Then, with the nerve fully lateralized, the dental implants are placed under direct visualization – in this case bicortically, taking advantage of the mandibular basal layer. Once the implants have been positioned, the vestibular cortical layer is replaced in those cases where an osteotomy has been performed, or the nerve is passively positioned against the implants in those cases where cortical drilling has been carried out. In either case, emergence of the nerve becomes more distal (14).

- Fenestration

In this case neither dissection of the terminal branches of the nerve nor sectioning of the incisor branch is needed. The technique involves the preparation of a cortical bone window (via osteotomy or drilling) located posterior to the mental foramen. After carefully freeing the nerve, the latter is separated using a vessel loop – applying gentle traction outwards as the implants are positioned (15). Finally, the vessel loop is removed and the nerve is replaced, positioning a reabsorbable membrane between it and the bone window, to avoid direct contact with the implants. The procedure is completed by suturing the mucoperiosteal flap (Fig. 1-B).

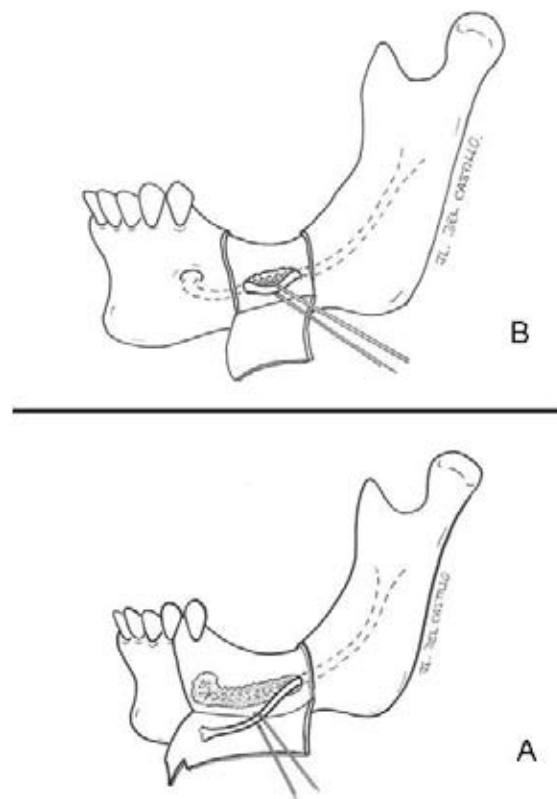


Fig. 1. A. Schematic representation of alveolar nerve lateralization. An osteotomy is performed around the alveolar nerve foramen, continuing with a posterior window until the nerve is fully freed from its intrabony trajectory.

Fig. 1. B. Schematic representation of alveolar nerve fenestration. A cortical bone window is performed posterior to the mental foramen, along the length of the canal. After freeing the nerve, gentle traction is exerted upon the latter using a vessel loop during positioning of the implants.

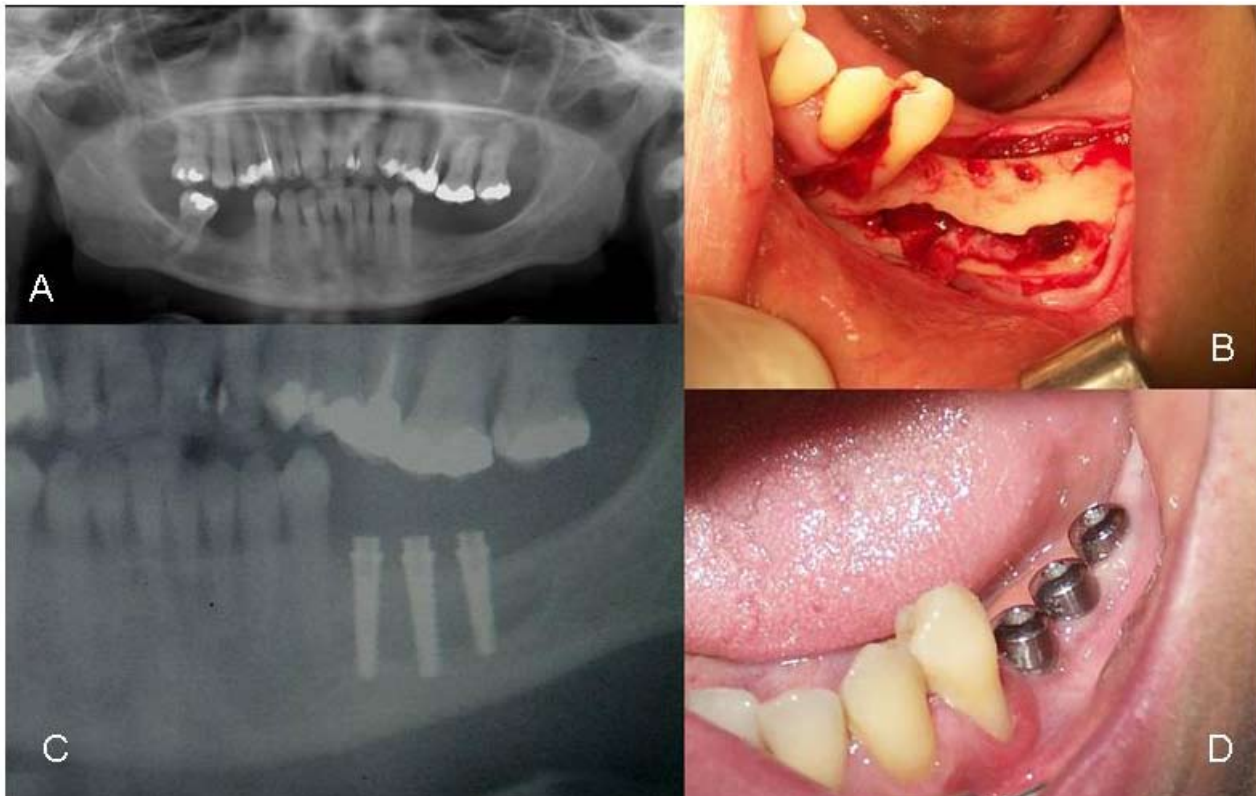


Fig. 2. A. Panoramic X-ray view prior to surgery, showing the poor crest height in the mandibular posterior sectors.
Fig. 2. B. Intraoperative view. After drilling around the mental foramen, a posterior window is created in the external cortex to ensure complete mobilization of the alveolar nerve and implant placement under direct visualization.
Fig. 2. C. Control panoramic X-ray view two months after the operation. The implants are seen to reach the mandibular basal layer.
Fig. 2. D. Second surgical step. Placement of the healing screws.

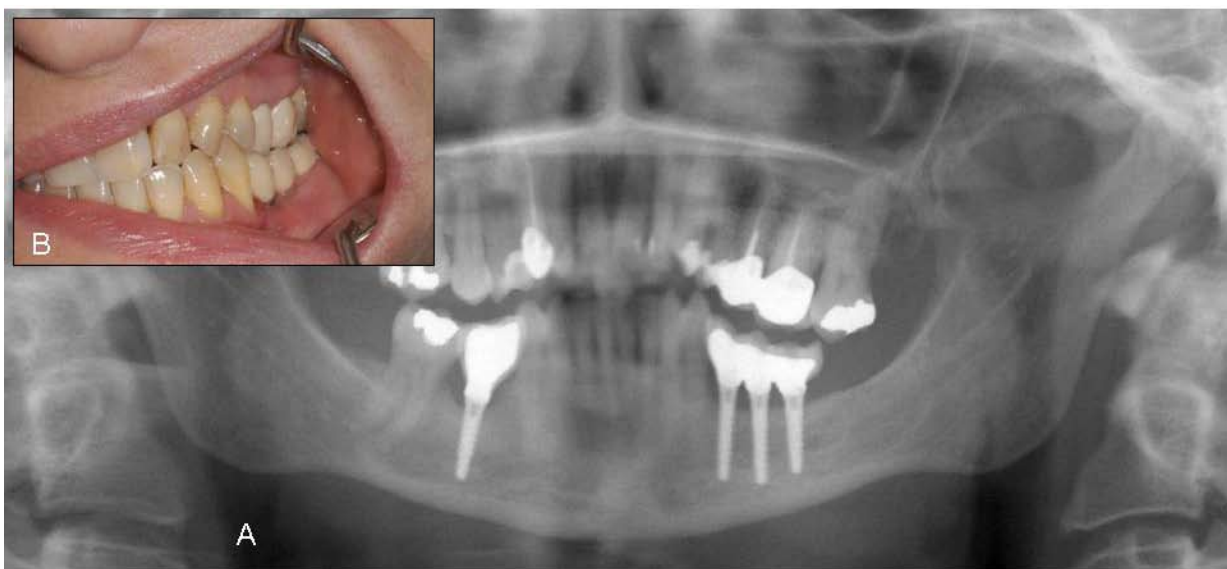


Fig. 3. A. Panoramic X-ray view of the final result.
Fig. 3. B. Final result. Intraoral view showing the implant-supported restoration.

Clinical Case

A 47-year-old woman presented with edentulous mandibular posterior sectors (Fig. 2-A). After studying the case and evaluating all the possible options for implant-supported rehabilitation with the patient, left inferior alveolar nerve repositioning was decided, with implant placement on both sides, in the same surgical step.

Following incision and raising of the vestibular gingiva, the inferior alveolar nerve foramen was identified and an osteotomy was performed ahead of the foramen using a diamond drill, until the nerve was fully exposed over its anterior curvature, with sectioning of the incisor branch. We continued drilling of the external cortical layer about 2 cm along the trajectory of the nerve until it was fully lateralized (Fig. 2-B). Then, under direct visualization, the 15-mm dental implants were positioned fixed at crestal level and in the mandibular basal layer – thereby affording important primary implant stability. Finally, the nerve was repositioned, and the gingival mucosa was sutured.

Broad spectrum antibiotic treatment was administered for 10 days. During the first week and until suture removal, a soft diet with good oral hygiene (including chlorhexidine rinses) was indicated. In the immediate postoperative period the patient reported slight paresthesia of the left half of the lower lip that persisted for a few weeks. Control panoramic X-rays were obtained (Fig. 2-C).

Six months after implant placement, lip sensitivity was fully restored, and the patient experienced no paresthesias or neuralgias. The control X-rays showed implant osseointegration; as a result, the second surgical step was performed under local anesthesia, exposing the implants and replacing the locking screws with transmucosal healing abutments (Fig. 2-D). Impressions were obtained after 15 days, and following metal testing and definitive prosthesis placement, good esthetic and functional results were obtained (Figs 3-A and 3-B).

Discussion

We have reviewed a number of studies published in the literature on repositioning of the inferior alveolar nerve for implant placement in mandibular posterior sectors.

The best results reported to date are those of Morrison et al. (14), who presented a series of 20 alveolar nerve lateralizations in 12 patients. In four cases sensory disturbances persisted for more than 6 months, though these did not interfere with daily life in any way. Only one patient suffered dysesthesias that subsided with carbamazepine and analgesics. Osseointegration of the 30 positioned implants was 100%.

Rosenquist et al. (12) in turn published the largest series (114 patients subjected to the lateralization technique), with the longest duration of follow-up. Implant osseointegration was 95% after 6 months, and 93% after 18 months. Eighty percent of the patients experienced neurosensory changes. After 18 months, 94% had normalized,

while 4% continued to present hypoesthesia that was well tolerated. Only one patient suffered permanent complete anesthesia.

Hori et al. (16) performed inferior alveolar nerve repositioning in 6 patients with the placement of 26 implants in mandibular posterior sectors. Three years after surgery, implant osseointegration was 100%, and 5 patients experienced mild hypoesthesia that was not regarded as a problem. Ferrigno et al. (11) published a series of 19 lateralizations in 15 patients, with the placement of 46 ITI implants. Two implants were lost, and only four patients suffered sensory changes during follow-up (12 to 78 months after surgery). Despite the minimal dysesthesias, the patients were satisfied with the overall procedure.

Inferior alveolar nerve repositioning allows implant placement in atrophic mandibles without the need for bone grafting, in the same surgical step. Important primary implant stability is achieved as a result of fixation in the mandibular basal layer. However, nerve repositioning is a complex procedure, with a high risk of sensory changes (anesthesia, paresthesia or neuralgia, mostly of a transient nature, but sometimes permanent). Careful nerve manipulation and mobilization is required in order to reduce the risk of neurosensory alterations.

Implant-based rehabilitation of edentulous mandibular posterior sectors with inferior alveolar nerve repositioning is thus a valid management option in selected cases, and despite the possible complications (e.g., paresthesias), the technique is usually well tolerated by the patients.

References

1. Polo WC, Cury PR, Sendyk WR, Gromatzky A. Posterior mandibular alveolar distraction osteogenesis utilizing an extraosseous distractor: a prospective study. *J Periodontol*. 2005 Sep;76(9):1463-8.
2. Basa S, Varol A, Turker N. Alternative bone expansion technique for immediate placement of implants in the edentulous posterior mandibular ridge: a clinical report. *Int J Oral Maxillofac Implants*. 2004 Jul-Aug;19(4):554-8.
3. Proussaefs P. Vertical alveolar ridge augmentation prior to inferior alveolar nerve repositioning: a patient report. *Int J Oral Maxillofac Implants*. 2005 Mar-Apr;20(2):296-301.
4. Peñarocha-Diago M, Gómez-Adrián MD, García-Mira B, Ivorra-Sais M. Bone grafting simultaneous to implant placement. Presentation of a case. *Med Oral Patol Oral Cir Bucal*. 2005 Nov-Dec;10(5):444-7.
5. Nocini PF, De Santis D, Fracasso E, Zanette G. Clinical and electrophysiological assessment of inferior alveolar nerve function after lateral nerve transposition. *Clin Oral Implants Res*. 1999 Apr;10(2):120-30.
6. Metzger MC, Bormann KH, Schoen R, Gellrich NC, Schmelzisen R. Inferior alveolar nerve transposition--an in vitro comparison between piezosurgery and conventional bur use. *J Oral Implantol*. 2006;32(1):19-25.
7. Levine MH, Goddard AL, Dodson TB. Inferior alveolar nerve canal position: a clinical and radiographic study. *J Oral Maxillofac Surg*. 2007 Mar;65(3):470-4.
8. Alling CC. Lateral repositioning of inferior alveolar neurovascular bundle. *J Oral Surg*. 1977 May;35(5):419.
9. Jensen O, Nock D. Inferior alveolar nerve repositioning in conjunction with placement of osseointegrated implants: a case report. *Oral Surg Oral Med Oral Pathol*. 1987 Mar;63(3):263-8.
10. Jensen J, Reiche-Fischel O, Sindet-Pedersen S. Nerve transposition and implant placement in the atrophic posterior mandibular alveolar ridge. *J Oral Maxillofac Surg*. 1994 Jul;52(7):662-8.

11. Ferrigno N, Laureti M, Fanali S. Inferior alveolar nerve transposition in conjunction with implant placement. *Int J Oral Maxillofac Implants.* 2005 Jul-Aug;20(4):610-20.
12. Rosenquist B. Fixture placement posterior to the mental foramen with transpositioning of the inferior alveolar nerve. *Int J Oral Maxillofac Implants.* 1992 Spring;7(1):45-50.
13. Louis PJ. Inferior alveolar nerve repositioning. *Atlas Oral Maxillofac Surg Clin North Am.* 2001 Sep;9(2):93-128.
14. Morrison A, Chiarot M, Kirby S. Mental nerve function after inferior alveolar nerve transposition for placement of dental implants. *J Can Dent Assoc.* 2002 Jan;68(1):46-50.
15. Babbush CA. Transpositioning and repositioning the inferior alveolar and mental nerves in conjunction with endosteal implant reconstruction. *Periodontol 2000.* 1998 Jun;17:183-90.
16. Hori M, Sato T, Kaneko K, Okaue M, Matsumoto M, Sato H, et al. Neurosensory function and implant survival rate following implant placement with nerve transpositioning: a case study. *J Oral Sci.* 2001 Jun;43(2):139-44.