



**VNIVERSITAT
DE VALÈNCIA**

**UNIVERSIDAD DE VALENCIA
FACULTAD DE MEDICINA Y ODONTOLOGÍA
TUTELA ACADÉMICA R.D. 99/2011
Programa de Doctorado 3139 Medicina
Línea de Investigación: OFTALMOLOGIA**

**DOCTORAL THESIS
CHOROIDAL THICKNESS AND MORPHOLOGY ANALYSED BY OPTICAL
COHERENCE TOMOGRAPHY AS A METHOD TO APPROACH DIABETIC
OCULAR DISEASE PROGNOSIS AND PROGRESSION**

DOCTORANDO:

Lilianne Gonçalves Duarte

Director and Co-Director

María Dolores Pinazo-Duran, MD, PhD

José Salgado-Borges, MD, PhD

Roberto Gallego-Pinazo, MD, PhD

July, 2018

DOCTORAL THESIS

“CHOROIDAL THICKNESS AND MORPHOLOGY ANALYSED BY OPTICAL
COHERENCE TOMOGRAPHY AS A METHOD TO APPROACH DIABETIC
OCULAR DISEASE PROGNOSIS AND PROGRESSION”

Doctoral thesis presented by Lilianne Gonçalves Duarte, medical doctor, with the
passport number: 566209506, to obtain the PhD degree.

Signature: Lilianne Gonçalves Duarte

Valencia, July the 31st

Directors:

Prof. María Dolores Pinazo Durán

Prof. José Salgado-Borges

Prof. Roberto Gallego Pinazo

Dña. María Dolores Pinazo Durán

Profesora Asociada de Oftalmología. Departamento de Cirugía de la Facultad de Medicina y Odontología de la Universidad de Valencia.

Dr. José Manuel Salgado Borges

Doctor en Oftalmología por la Facultad de Medicina de la Universidad de Porto, Portugal. MD, PhD, FEBO.

Dr. Roberto Gallego Pinazo

Doctor en Medicina y Cirugía por la Universidad de Valencia, Especialista en Oftalmología. FEBO. Subespecialista en mácula.

INFORMAN:

Que la Sra. Doña Lilianne Gonçalves Duarte ha realizado el presente trabajo de Tesis Doctoral bajo nuestra supervisión, y habiendo revisado la versión final la encontramos apropiada para ser presentada y defendida ante tribunal para optar al grado de Doctor de la Universidad de Valencia.

En Valencia a 31 de Julio de 2018

M D Pinazo Duran

J M Salgado Borges

R Gallego Pinazo

ACKNOWLEDGMENTS

Firstly, I would like to express my sincere gratitude to my tutors Prof. María Dolores Pinazo Duran, Prof. José Salgado-Borges and Prof. Roberto Gallego Pinazo for the continuous support of my Doctoral study and research, for their patience, motivation, and immense knowledge. Their guidance was fundamental for the pursuit of the hard work required to perform the study. They were highly supportive for motivation in the difficult moments and in the last step of writing this thesis.

My sincere thanks to all that have contributed to the achievement of my research:

— The technicians of my Department for performing the ophthalmologic imaging exams — Susana Ventura, Libânia Dias, Raquel Leitão, Helena Ferreira, Raquel Rocha;

- The Nurses, in particular Carla Peralta.
- Dr. Miguel Ruão as a grader for choroidal boundaries in OCT images.
- The Residents for their work on data collection — Dr.^a Ana Rita Laiginhas and Dr.^a Jennifer Jesus.
- Dr.^a Sandra Barrão, Ophthalmologist and Orthoptist Pedro Camacho from the Instituto Oftalmológico Gama Pinto for the images for the ancillary study.
- Dr. Diogo Semedo for the partial statistical analysis and Prof. Sandrina Nunes for the main study statistical analysis and support.
- Mr. Afonso Martinho and Mr. Pedro Abreu (Oftaltec — Spectralis OCT), Mr. Leandro Pereira and Mr. Luís Feijó (Optometron — Nidek OCT) for the support and loan of OCT devices to perform the pilot studies.

- Prof. Maria Cândida Gonçalves, my mother, for the writing editing, and my brother Cláudio Alexandre G. Duarte for the assistance in my hard computer moments, and both for the eternal support and love.

I must thank Mr. Oskar Barrachina for his constant availability to help in matters in Valencia, shortening the distances issues from Portugal to Spain.

Last but not the least, I would like to thank my family, Paulo, Ruben, Mariana and my father Cláudio Duarte, for supporting me with patience throughout my research, writing this thesis and my life in general.

TABLE OF CONTENTS

GLOSSARY OF ABBREVIATIONS AND ACRONYMS	8
TABLES, GRAPHICS AND FIGURES	10
SUMMARY	16
RESUMEN	19
CHAPTER 1 — INTRODUCTION	22
1.1. VASCULAR COMPLICATIONS OF DIABETES	25
1.2. THE DIABETIC RETINOPATHY — A VASCULAR DISEASE	28
1.3. THE CHOROID — A COMPLEX VASCULAR STRUCTURE. THE DIABETIC CHOROIDOPATHY	30
1.3.1. ANATOMY AND FUNCTION.....	30
1.3.2. THE DIABETIC CHOROIDOPATHY	33
1.4. OPTICAL COHERENCE TOMOGRAPHY — A METHOD TO VIEW THE CHOROID	36
1.5. LITERATURE REVIEW ON DIABETIC CHOROIDOPATHY ANALYSED WITH OCT	43
CHAPTER 2 — REASON AND PURPOSE OF THE STUDY	47
2.1. MAIN STUDY PURPOSE	49
2.2. SECONDARY, ANCILLARY OR PILOT STUDY PURPOSE	49

CHAPTER 3 — MATERIAL AND METHODS	51
3.1. DESIGN OF THE STUDY AND SETTING	52
3.2. MAIN STUDY SUBJECTS.....	53
3.2.1. GROUP 1 — INCLUSION CRITERIA	53
3.2.2. GROUP 2 — INCLUSION CRITERIA	53
3.2.3. EXCLUSION CRITERIA (BOTH GROUPS).....	53
3.2.4. DROP OUT or LOST TO FOLLOW UP (DO or LFU).....	54
3.3. MAIN STUDY CLINICAL EVALUATION	54
3.4. IMAGING ACQUISITION AND ANALYSIS	55
3.4.1 FUNDUS PHOTOGRAPHY.....	56
3.4.2. FLUORESCEIN ANGIOGRAPHY	56
3.4.3. OPTICAL COHERENCE TOMOGRAPHY (OCT).....	56
3.4.3.1. OCT DEVICES	56
3.4.3.2. ACQUISITION PROTOCOLS.....	57
3.4.3.3. IMAGE ANALYSIS	58
3.5. STATISTICAL ANALYSIS	61
3.6. ETHICS AND CONFIDENTIALITY COMPLAINE	62
CHAPTER 4 — RESULTS	64

4.1. PILOT STUDIES.....	65
4.2. MAIN STUDY.....	71
4.2.1 MORPHOLOGICAL ANALYSIS	72
4.2.2. ANCILARY MORPHOLOGICAL STUDY	95
4.2.3. STATISTICAL RESULTS	99
4.2.3.1 BASELINE	100
4.2.3.2 PROGRESSION	112
CHAPTER 5 — DISSCUSSION	118
CHAPTER 6 — CONCLUSION	146
REFERENCES	149
APPENDICES.....	168

GLOSSARY OF ABBREVIATIONS AND ACRONYMS

ACCORD	Action to control cardiovascular risk in type 2 Diabetes
AGE	Advanced glycation end products
BP	Blood pressure
CCD	Charge-coupled device
CFRT	Central foveal retinal thickness
CHEDV	Centro Hospitalar Entre o Douro e o Vouga
ChS	Choriocapillaris/Sattler
CL	Choroidal layers
CME	Cystoid macular edema
CRF	Case Report Form
CSME	Clinically significant macular edema
CT	Choroidal Thickness
DME	Diabetic macular edema
DO	Drop out
DR	Diabetic Retinopathy
DRIL	Disorganization of retinal inner layers
EDI	Enhanced depth imaging
ETDRS	Early Treatment Diabetic Retinopathy Study
FD	Fourier domain
IRMA	Intraretinal microvascular abnormalities
LFU	Lost of follow up
ME	Macular edema
MIT	Massachusetts Institute of Technology
NDR	No diabetic retinopathy
NPDR	Non-proliferative diabetic retinopathy
NSD	Neurosensorial Detachment
NVD	New vessels on the disc
NVE	New vessels elsewhere
OCT	Optical Coherence Tomography
OD	Oculus dextrus — right eye

OP	Ocular pressure
OS	Oculus sinister — left eye
PDR	Proliferative diabetic retinopathy
PKC	Protein Kinase C
RPE	Retinal Pigment Epithelium
RT	Retinal Thickness
SCI	Sclero-choroidal interface
SD	Standard deviation
SD-OCT	Spectral Domain Optical Coherence Tomography
SFCT	Sub foveal choroidal thickness
SLD	Super Luminescent diode
SMD	Sub macular detachment
SS-OCT	Swept Source Optical Coherence Tomography
TD-OCT	Time Domain Optical Coherence Tomography
UKPDS	United Kingdom Prospective Diabetes Study
VA	Visual Acuity
VEGF	Vascular endothelial growth factor

TABLES, GRAPHICS AND FIGURES

TABLES

Table 1 — Most cited studies of Choroidal Thickness in healthy population	40
Table 2 — Most cited studies of Choroidal Thickness in Diabetic population	45
Table 3 — Demographics and Mean values of SFCT — pilot study	70
Table 4 — Main study - choroidal morphologic features by group.	74
Table 5 — Correlation of choroidal morphologic findings with the retinopathy grade.	77
Table 6 — Correlation of choroidal thickness changes with retinal thickness progression	85
Table 7 — Correlation of retinal thickness changes with choroidal thickness progression.	85
Table 8 — Demographics of Diabetic group (analysis per eye).	100
Table 9 — Demographics of Diabetic group (analysis per subject).	100
Table 10 — Diabetic group — Choroidal and retinal thickness and metabolic status.	101
Table 11 — Diabetic group — Choroidal thickness for each Diabetic retinopathy (DR) stage.	101
Table 12 — Demographics of Control group (analysis per eye).	104
Table 13 — Demographic of Control group (analysis per subject)	104

Table 14 — Control group — Choroidal and retinal thickness.	105
Table 15 — Diabetic group — Differences between eyes.....	106
Table 16 — Control group — Differences between eyes	107
Table 17 — Statistical results comparing the 2 groups for statistical difference ..	108
Table 18 — Comparison of SFCT and CFRT between the two groups.	108
Table 19 — SFCT mean values by diabetic retinopathy (DR) stage.	108
Table 20 — SFCT mean values by presence of macular edema (ME).....	109
Table 21 — Multivariate analysis with SFCT as the dependent variable — Diabetic group.....	110
Table 22 — Multivariate analysis with SFCT as the dependent variable — Control group.....	111
Table 23 — Progression analysis — diabetic group.	112
Table 24 — Correlation analysis between SFCT variation and CFRT and systemic variables- diabetic group.....	113
Table 25 — Correlation of Variation of SCFT with duration of Diabetes and with age	113
Table 26 — Progression analysis — control group.	115
Table 27 — Correlation analysis between SFCT variation and CFRT and systemic variables — control group.....	116
Table 28 — Multivariate analysis of progression of variables with SFCT progression — control group.	116

GRAPHICS

Graphic 1 — Diabetic group — Distribution of SFCT	102
Graphic 2 — Diabetic group — Distribution/dispersion of SFCT for each included eye by age	103
Graphic 3 — Diabetic group — Distribution/dispersion of SFCT for each subject by CFRT	103
Graphic 4 — Control group — Distribution of SFCT	105
Graphic 5 — Control group — Distribution/dispersion of SFCT for each included eye by age	106
Graphic 6 — Correlation of progression of SFCT and CFRT — control group	117

FIGURES

Figure 1 — Example of boundaries for the measurement of SFCT	59
Figure 2 — Example of an image with inability to visualize the sclero-choroidal limit.	60
Figure 3 — Choroidal morphological analysis from Branchini et al.....	61
Figure 4 — Normal choroid morphology classification — pilot study	66

Figure 5 — Abnormal choroid morphology in Diabetic Macular Edema — pilot study. 67

Figure 6 — Abnormal choroid morphology in PDR — pilot study. 68

Figure 7 — Abnormal choroid morphology in PDR — pilot study. 68

Figure 8 — Progressive change in choroid morphology in the different DR stages. 69

Figure 9 — Choroidal morphologic changes in Control..... 75

Figure 10 — Choroidal morphologic changes in Control..... 76

Figure 11 — Choroidal morphologic changes in Control..... 77

Figure 12 — Choroidal morphologic changes in a Diabetic with no retinopathy.... 79

Figure 13 — Choroidal morphologic changes in a Mild non-proliferative retinopathy. 79

Figure 14 — Proliferative diabetic retinopathy with normal choroidal morphology. 80

Figure 15 — Choroidal morphologic changes in Macular edema. 80

Figure 16 — Variation of normal choroidal vessels morphology. 81

Figure 17 — Choroidal morphologic changes in a Mild non-proliferative retinopathy. 81

Figure 18 — Choroidal thinning with age. 82

Figure 19 — Choroidal morphologic changes in Macular edema. 83

Figure 20 — Focal retinal and subjacent choroidal morphologic changes..... 83

Figure 21 — Focal retinal and subjacent choroidal morphologic changes..... 84

Figure 22 — Focal retinal and subjacent choroidal morphologic changes..... 84

Figure 23 — Example in Macular edema progression. 86

Figure 24 — Example of CT increase with no retinal changes. 87

Figure 25 — Choroidal morphologic changes in Retinal improved progression. ... 88

Figure 26 — Choroidal morphologic changes in Retinal worsening progression... 89

Figure 27 — Choroidal morphologic changes in Retinal worsening progression... 90

Figure 28 — Progression in a Diabetic with no retinopathy. 91

Figure 29 — Choroidal morphologic changes in a macular edema progression. .. 92

Figure 30 — Choroidal morphologic changes in retinopathy grade progression. .. 92

Figure 31 — Choroidal morphologic changes in a macular edema progression. .. 93

Figure 32 — Choroidal morphologic changes after macular edema resolution. 94

Figure 33 — Choroidal morphologic changes after macular edema resolution. 95

Figure 34 — Choroidal thickness maps in healthy and different retinopathy stages.
..... 96

Figure 35 — Schematic and OCT image of normal choroidal morphology. 140

Figure 36 — Schematic image of normal choroidal morphology with vasoconstriction
..... 141

Figure 37 — Schematic image of normal choroidal morphology with vasodilatation
..... 142

Figure 38 — Schematic image of normal choroidal morphology 143

Figure 39 — Schematic and OCT image of an abnormal or pathologic choroidal
morphology 144

SUMMARY

TITLE

CHOROIDAL THICKNESS AND MORPHOLOGY ANALYSED BY OPTICAL COHERENCE TOMOGRAPHY AS A METHOD TO APPROACH DIABETIC OCULAR DISEASE PROGNOSIS AND PROGRESSION

INTRODUCTION

Clinical evidence of diabetic choroidopathy (DC) in-vivo has been difficult to demonstrate clinically due to the lack of means to visualize the choroid. Advances of Optical Coherence Tomography (OCT) technology allowed in-vivo visualization of the choroid. Controversial results in Diabetes for choroidal thickness (CT) and lack in the identification of morphologic changes makes DC identified with OCT still to be understood.

PURPOSE

To evaluate whether CT measurement alone is a reliable parameter to characterize DC, to characterize choroidal morphological findings using the OCT and correlation with CT and the diabetic retinopathy (DR).

METHODS

A cohort, prospective, longitudinal and observational study, where diabetic and healthy controls were followed in consecutive visits. Inclusion criteria were: healthy

and Diabetic patients without or with any stage of DR, aged 18 or more, signed voluntarily informed consent. Exclusion criteria were: previous treatment of any kind for DR; previous or ongoing ocular disease or history of ocular surgery; relevant media opacities; refractive errors greater than ± 6 Diopters; systemic chronic steroid or immunosuppressive medication; any serious and uncontrolled systemic condition. Previous studies were performed to identify choroidal morphological findings on OCT to be used as classification method. Quantitative assessment of retinal and subfoveal choroidal thickness (SFCT), qualitative assessment of choroidal morphological findings, and correlation with the retinal diabetic disease state. Evaluation of progression and predictive relevancy.

RESULTS

One hundred and ninety-six diabetic eyes and seventy-eight healthy eyes were included. From choroidal morphologic analysis we found: on healthy 78% were normal, and abnormalities found were always on the great vessels layers with preserved choriocapillaris/Sattler (ChS) layers. Most of diabetic eyes with no abnormalities had no and initial stages of DR. Focal choroidal vascular changes were correlated with the subjacent retinal disease. Atrophy of the ChS layer or the great vessels layer was well correlated with more advanced stages of DR and maculopathy. Progression of choroidal morphologic changes was well evidenced and correlated with progression of retinal disease. From statistical analysis: SFCT showed huge variability with multifactorial dependence. Statistical significance of correlation with SFCT was found only for age for both groups and choroidal layers abnormalities for diabetics and systolic blood pressure for healthy.

CONCLUSION

SFCT showed to be dependent on multifactorial variables with a wide range of values showing not to be a reliable parameter alone for DC evaluation. With OCT images we can identify and classify as normal or abnormal choroidal morphologic findings. Abnormal choroidal findings are well correlated with suprajacent retinal diabetic disease and can be a marker of evolution or progression of the disease of treatment effect.

RESUMEN

TÍTULO

ESPESOR COROIDEO Y MORFOLOGÍA ANALIZADO POR TOMOGRAFÍA DE COHERENCIA ÓPTICA COMO MÉTODO PARA ABORDAR LA PROGNOSIS Y LA PROGRESIÓN DE LA ENFERMEDAD OCULAR DIABÉTICA

INTRODUCCIÓN

La evidencia clínica in vivo de corioidopatía diabética (DC) ha sido difícil de demostrar clínicamente debido a la falta de medios para visualizar la coroides. Los avances de la tecnología de la tomografía de coherencia óptica (OCT) permitieron la visualización in vivo de la coroides. Los resultados controvertidos en la Diabetes para el grosor coroideo (CT) y la falta de identificación de los cambios morfológicos hacen que la DC identificada con OCT aún no se conozca.

PROPÓSITO

Evaluar si la medición por CT sola es un parámetro confiable para caracterizar la DC, para caracterizar los hallazgos morfológicos coroidales usando la OCT y la correlación con la CT y la retinopatía diabética (DR).

MÉTODOS

Estudio cohorte, prospectivo, longitudinal y observacional, donde se siguieron los controles diabéticos y sanos en visitas consecutivas. Los criterios de inclusión

fueron: pacientes sanos y diabéticos sin o con cualquier estadio de RD, de 18 años o más, firmados voluntariamente con consentimiento informado. Los criterios de exclusión fueron: tratamiento previo de cualquier tipo para DR; enfermedad ocular previa o en curso o antecedentes de cirugía ocular; opacidades de medios relevantes; errores de refracción mayores que ± 6 dioptrías; medicamentos séricos crónicos o inmunosupresores sistémicos; cualquier condición sistémica grave e incontrolada. Se realizaron estudios previos para identificar los hallazgos morfológicos de la coroides en OCT que se utilizarán como método de clasificación. Evaluación cuantitativa del grosor de la coroides retiniana y subfoveal (SFCT), evaluación cualitativa de los hallazgos morfológicos coroidales y correlación con el estado de la enfermedad diabética retiniana. Evaluación de progresión y relevancia predictiva.

RESULTADOS

Se incluyeron 96 ojos diabéticos y setenta y ocho ojos sanos. A partir del análisis morfológico de la coroides, encontramos que el 78% de los sanos eran normales y las anomalías encontradas siempre en las capas de grandes vasos con capas preservadas de coriocapilar / Sattler (ChS). La mayoría de los ojos diabéticos sin anomalías no tenían y las etapas iniciales de DR. Los cambios vasculares coroidales focales se correlacionaron con la enfermedad retiniana subyacente. La atrofia de la capa de ChS o la capa de grandes vasos estaba bien correlacionada con etapas más avanzadas de DR y maculopatía. La progresión de los cambios morfológicos coroidales se evidenció y se correlacionó con la progresión de la enfermedad retiniana. A partir del análisis estadístico: SFCT mostró una gran variabilidad con la

dependencia multifactorial. La significación estadística de la correlación con SFCT se encontró solo para la edad para ambos grupos y las anomalías de las capas coroides para los diabéticos y la presión arterial sistólica para la salud.

CONCLUSIÓN

SFCT mostró ser dependiente de variables multifactoriales con una amplia gama de valores que muestran que no es un parámetro confiable solo para la evaluación de DC. Con las imágenes de OCT podemos identificar y clasificar como hallazgos morfológicos coroidales normales o anormales. Los hallazgos anormales de la coroides están bien correlacionados con la enfermedad diabética retiniana suprayacente y pueden ser un marcador de evolución o progresión de la enfermedad del efecto del tratamiento.

CHAPTER 1 — INTRODUCTION

1 — INTRODUCTION

Diabetes Mellitus has been increasing in prevalence over the last decades. According to the last report by the International Diabetes Federation, there were 425 million diabetic patients in the adult population worldwide in 2017. This number projected to the year of 2045 will arise to 629 million¹. Due to this epidemic prevalence of Diabetes, the World Health Organization emphasized on the World Health Day of 2016 the need to increase awareness on Diabetes and its morbidity and burden, and to stablish specific and effective actions to tackle Diabetes.²

Diabetes is a metabolic disease associated to hyperglycemia. Severe acute or prolonged hyperglycemia leads to the macrovascular and microvascular diabetic disease affecting several organs and tissues. Microvascular complications are responsible for the diabetic nephropathy, neuropathy and retinopathy, while macrovascular complications affect mostly the heart and peripheral vascular systems and can be associated with stroke³. It is important to understand the pathophysiology of vascular damage due to hyperglycemia and the changes in vessels so that we can look for signs of risk to progression and ways to prevent and/or treat the vascular complications, such as in Diabetic retinopathy.

According to a large systematic analysis, Diabetic retinopathy was responsible for 1.9% of moderate to severe visual impairment globally and 2.6% of blindness in 2010⁴. Another meta-analysis demonstrated a worrying increase from 1990 to 2010 of 27% in blindness and 64% of moderate to severe visual impairment due to

Diabetic retinopathy⁵. Higher risk and prevalence were found in older populations and high-income regions, such as Western Europe, North America and Australasia⁵.

Diabetic retinopathy was first described by Eduard Jäger, in 1856, as a finding with the new ophthalmology instrument developed just few years earlier, the ophthalmoscope.⁶⁻⁸ Acceptance of a specific pattern of diabetic lesions in the retina only came on the 40's with Ballantyne's description⁹ and later with Ashton and Cogan.^{7,9-11} In the 60's, the publication of the new technique fluorescein angiography and its progressive use in ophthalmology, brought about new insights into the pathophysiology of diabetic retinopathy and allowed new advances in diagnosis and treatment guidelines.^{12,13}

For about 3 decades, the only ophthalmic imaging systems available for examination and diagnosis were fundus photography and angiography. In the early 90's David Huang presents a paper on the Optical Coherence Tomography.¹⁴ It was a breakthrough in Ophthalmology and in the diagnosis, treatment and follow up for ocular diseases, with special focus on retinal diseases. Since the initial development, commercialization of the first device for clinical purpose till now, the Optical Coherence Tomography (OCT) systems have been improving in acquisition systems, hardware and software for better resolution, increased speed and increased information.^{15,16} The OCT has allowed, with a noninvasive ophthalmological exam, to have qualitative and quantitative information of the retina, with anatomical and in-depth information. It has also been very important in the workup of Diabetic retinopathy, in the diagnosis and classification of macular edema,

in guiding treatment indications, efficacy and follow up, decreasing the need of the invasive ophthalmological exams, such as fluorescein angiography.

The first OCTs, due to a limitation of the system, were unable to give information of deeper structures such the choroid. In 2008 Spaide et al. described a novel imaging technique using the OCT Spectralis system that allowed to improve choroidal visualization, the Enhanced Depth Imaging (EDI).^{17,18} Since then with the evolution of the OCT systems with increased acquisition speed, increased resolution and the availability of the Swept-Source OCT, choroidal visualization has been improved. New data from retinal and choroidal diseases have emerged with this additional feature of the OCTs.

Since the first publication by Spaide describing the EDI, several papers have been published regarding choroidal thickness and its correlation with retinal disease. Several look for a correlation of choroidal thickness changes with the diabetic retinopathy trying to find signs of a diabetic choroidopathy. The results between the papers vary and sometimes are controversial.

In this Section a review of current data was presented as the base for the rationale for this study.

1.1. VASCULAR COMPLICATIONS OF DIABETES

Diabetes and hyperglycemia cause disease in several tissues by affecting the vascular system. Great vessels and smaller/microscopic vessels affected by

hyperglycemia injury lead to two separated diabetic vascular disease: the macrovascular and the microvascular diabetic complications.

It is important to understand how vascular complications occur, since the pathophysiology of diabetic retinopathy undergoes from them. The choroid is a mainly vascular structure, so it is expectable to have a diabetic choroidal vascular disease leading to a diabetic choroidopathy.

Macrovascular diabetic disease affects primarily greater vessels with atherosclerotic process and hypercoagulation states increasing the risk of thrombosis, vessel occlusion and stroke. The exact mechanism how Diabetes increases the risk of atheroma formation is not well understood. Several studies had shown the association of Diabetes with an increased risk of cardiovascular disorders.^{3,19–24}

Type 2 Diabetes is a complex metabolic clinical condition that comes with increased blood glucose, hypertension, overweight, dyslipidemia, all of these contributing to a higher risk of cardiovascular disorder. So, the association of Diabetes with cardiovascular disorder seems to be a part of a multifactorial condition. Nevertheless, intensive control of blood pressure and lipid levels in Diabetic patients have shown a decrease in cardiovascular events.^{22,24–26} In type 1 Diabetic patients, usually thinner, younger with less propensity to high blood pressure or dyslipidemia, hyperglycemia was correlated to higher heart rate, a risk factor for cardiovascular disease.^{3,21,26} Macrovascular diabetic disease is associated to increased death risk.

Microvascular diabetic disease tends to cause intrinsic damage on the anatomy and function of the affected organs. It refers to the disease affecting vessels with an

internal diameter of 100 or less microns. The most important manifestations of diabetic microvascular disease are the Diabetic retinopathy, nephropathy and neuropathy, being the retinopathy the most common complication. Microvascular disease in Diabetes occurs due to a particular vessel cellular response and damage caused by increased and sustained hyperglycemia.²⁷⁻²⁹ Although several studies demonstrate that hyperglycemia is a major risk factor for microvascular damage in Diabetes, other causes underly such concomitant pathologies (e.g. hypertension and dyslipidemia) and genetic predisposition³⁰⁻³².

Microvascular disease includes endothelial dysfunction, pericytes or podocytes death, increased vascular permeability and angiogenesis, basement membrane thickening, cell growth and apoptosis, vascular occlusion and dilatation, extracellular matrix expansion and dysfunctional enzymatic activity. From the increased metabolic products of the glycolytic pathway in hyperglycemic state, modulated by genetic predisposition and local tissue response, several mechanisms are involved into the microvascular lesion: the activation of specific enzymes, such as the protein kinase C (PKC), phospholipase, adenosine triphosphatase and others, leads to altered cell signaling or molecule transduction; the activation of the polyol pathway, the formation of advanced glycation end products (AGE) and the production of superoxide and reactive oxygen species, leads to oxidative and endoplasmic reticulum stress, and the increase in inflammatory cytokines. All of these changes cause abnormal turnover and vascular and cell dysfunction leading to the diabetic retinopathy, neuropathy and nephropathy.^{27,33,34}

1.2. THE DIABETIC RETINOPATHY — A VASCULAR DISEASE

Since the earliest description of diabetic retinopathy with ophthalmoscopy we have been able to identify vascular involvement of the diabetic disease by observing microaneurysms (small capillaries dilatations), intra-retinal hemorrhages, signs of exudation, vessel abnormalities and new-vessels. Fluorescein Angiography allows us to observe the anatomical and dynamic (flow and perfusion) changes in the vascular retina occurring in the diabetic disease. Optical coherence tomography demonstrates the presence of anatomical and thickness changes as the result of permeability alterations with fluid accumulation, cysts, and chronic sequelae as atrophy and loss of tissue and fibrosis. The classification of diabetic retinopathy has been evolving since the first, the Arlie House classification, to more simplified classifications such as the International Clinical Disease Severity Scale for Diabetic Retinopathy. The severity of the diabetic retinopathy is classified according to the extent of the vascular changes encountered.^{35–38}

Klein et al. described as earliest changes observed in diabetic retinopathy the widening of retinal venules, even before the appearance of microaneurysms and blot hemorrhages.³⁹ In a most recent review it is summarized how retinal microvasculature measured and quantified can indicate the risk of progression of diabetic retinal disease in pre-clinical stages.⁴⁰ At the early clinical stages of diabetic retinopathy where findings are essentially microaneurysms, the turnover (or rate of appearance and disappearance) and count over time of the microaneurysms are biomarkers of disease progression.^{41–46} Also the turnover of microaneurysms and presence of foveal avascular zone abnormalities were described as characteristics allowing to

determine patterns or phenotypes of risk of progression to a more advanced disease.^{47–49} As the diabetic retinopathy progresses to more advanced stages, signs of alteration of the blood-retinal barrier permeability appear with more extensive retinal hemorrhages, hard exudates (representing lipidic deposition in the extravascular retinal space as a consequence of the lipoprotein leakage from the vessels), leakage and edema. More extensive vascular lesion can be observed with anatomical changes such as tortuosity, beading, loops, and infarction of the nerve fiber layer appearing as whitish or cotton wool spots. In severe or proliferative stages non-perfusion/ ischemia leads to neovascularization in the superficial retina with high risk of bleeding to the vitreous. Although some authors claim retinal neurodegenerative diabetic changes, it is not clear if they precede microvascular disease or are a consequence.^{50–54} It remains that the most important changes occurring in the retina and responsible for the morbidity and visual function disability are related to the vascular disease.

Hyperglycemia is the trigger in Diabetes for the development of diabetic retinopathy. As previously described it leads by several biochemical, cellular, physiological and inflammatory mechanisms to vascular changes as the pericyte loss, endothelial cells damage, basement membrane thickening, capillary occlusion, blood-retinal barrier dysfunction and increased permeability, increased circulating growth factors and oxidative products. However other concomitant conditions can act as incrementing risk factors for the microvascular disease, such as hypertension, dyslipidemia and genetics. The UKPDS showed benefit and decrease in the risk of progression of diabetic retinopathy in lowering blood pressure in uncontrolled hypertension.²² But the ACCORD did not find any benefit in lowering blood pressure in mild hypertensive

or normotensive patients in order to prevent diabetic retinopathy progression.⁵⁵ Some studies suggest that the control of lipid serum levels might have a small effect on diabetic retinopathy progression, but the physiologic mechanism is not clear.

1.3. THE CHOROID — A COMPLEX VASCULAR STRUCTURE. THE DIABETIC CHOROIDOPATHY

1.3.1. ANATOMY AND FUNCTION^{56–68}

The choroid is a part of the uveal tract of the eye. It is an extensive vascular network involved by connective tissue that goes from the *ora serrata* up to the optic nerve and lies between the sclera and the retina. From histology data the choroid varies in thickness from 220 μ posteriorly to 100 μ anteriorly.

The choroid is supplied by ciliary arteries derived from the first branch of the internal carotid artery that pierce the sclera more anteriorly by the long posterior ciliary arteries and peripapillary by the short posterior ciliary arteries, until the choriocapillaris. The venous drainage is made primarily by the vortex vein system that ultimately drain to the superior and inferior ophthalmic veins.

The enervation of the choroid has parasympathetic and sympathetic nerves, but only the latter has an autoregulatory influence in the choroidal blood flow.

The choroid has a very specific anatomic architecture. Histologically it is divided in four layers: the Bruch's membrane, the choriocapillaris, the stroma and the suprachoroid.

The Bruch's membrane separates the retinal pigmented epithelium (RPE) from the choriocapillaris. It is essentially a collagenous and elastic fiber tissue.

The choriocapillaris, described for the first time in the 18th century by Hovius, corresponds to the choroidal layer with the smallest vessels, with a 10 to 30 μm thickness. It is composed of modified capillaries with an unusual larger diameter (up to 40 μm) comparing with capillaries elsewhere in the body, and with the particularity of fenestrated walls. We can find gap junctions between endothelial cells but there are far fewer pericytes as those we find over retinal vascular endothelial cells. The support for the vascular system is mostly provided by the involving connective tissue. The whole choriocapillaris has an elaborated architecture in various functional independent lobules. Each lobule is supplied in its center by a precapillary arteriole to the flat and one-layer capillary network that drains into postcapillary venules. These characteristics have influence on the high speed of blood flow leakage from the capillaries. The choriocapillaris blood flow was found to have up to more 77% higher speed than retinal capillaries.

The stroma is composed of larger vessels than those found on the choriocapillaris, and the vessel diameter increases from the choriocapillaris adjacent side to the more posterior or scleral one. Involving the vessels there is connective tissue, melanocytes, nerve fibers, fibroblasts and non-vascular smooth muscle, macrophages, lymphocytes, plasma and mast cells. It is divided into two vessel layers: the medium diameter vessel layer or Sattler's layer, and the large vessel layer or the Haller's layer. The vessels of the stroma are not fenestrated or organized in lobules, they are rather intertwined and, especially in the Haller's layer, the arteries

are similar to those elsewhere with contractile ability due to the presence of internal elastic lamina and smooth muscle. They don't leak as the choriocapillaris. The vessel system is supported by the involving tissue and cells, and it was suggested that the non-vascular smooth muscle and fibroblasts plays a role in the choroidal thickness changes occurring in physiologic states as on retinal defocus.

The suprachoroid separates the Haller's layer from the lamina fusca (pigmented layer of the sclera). It is an avascular layer rich in melanocytes, collagen and elastic fibers, fibroblasts and nerve fibers and cells.

It is important to know the anatomy of the choroid in order to better interpret OCT images.

The physiological role of the choroid is highly related to its blood flow. It is responsible for the major supply of oxygen and nutrients to the outer retina with particular influence on the metabolic processes of the photoreceptors and light absorption due to its rich melanocytes content; it has a retinal thermoregulation role; it is important in the immunologic response of the eye since it works as a provider of mast and inflammatory cells to the eye and a barrier for certain kind of molecules; and it is responsible for about 35% of the humor aqueous drainage with a role in the ocular pressure control. Since it is a highly vascular structure with elevated blood flow speed, it is also susceptible to systemic changes. Beside those functional roles, it has been suggested that the changes in choroidal thickness can be correlated with refractive states and even with the eye growth process.

The high and speedy blood flow of the choroid and particularly of the choriocapillaris is necessary to outdo the barriers of the Bruch's membrane and retinal pigment epithelium to provide the increased amount of oxygen required for the extremely metabolically active photoreceptors. The large caliber capillaries of the choroid and the fact that they are fenestrated allow permeability to large molecules that do not pass through the retinal capillaries, such as glucose, proteins and other nutrients. This is important not only for the contribution of nutrients and molecules for the outer retina, but also for the removal of the waste produced from metabolic processes of the outer retina.

Choroidal and retinal disorders are intimately related due to the high dependence of the normal and efficient outer retina function to choroidal blood flow supply. Systemic diseases affecting vascular system or spread by blood can affect both the choroid and the retina. A malfunction of the choroid will have a strong effect on the outer retina and photoreceptor metabolism. Until now it is not clear if the choroid might have an autoregulation mechanism, but the choroid may react in response to retinal pathology, as a response to an increased or decreased need for nutrition or metabolic input of retinal cells, or to the excessive retinal metabolic products to be expelled to blood circulation.

1.3.2. THE DIABETIC CHOROIDOPATHY

Diabetic retinal disease is much better known than diabetic choroidal disease, a great part because of easier visibility by fundoscopic exam and imaging such as fluorescein angiography and first OCTs.

Searching PubMed, the first paper using the term “Diabetic choroidopathy” was published on 1982 by Sarraco et al., where they described vascular anomalies, microaneurysms, and obliterated zones similar to the retinal changes of diabetic patients.⁶⁹ The exact pathophysiology of a Diabetic choroidopathy is still unknown, but several histologic and imaging studies indicate changes occurring in the choroid in diabetic patients.

Hidayat and Fine⁷⁰ in 1985 described histologic findings in eyes of subjects who had suffered for long standing Diabetes, with capillary dropout and basement membrane thickening. In 1988, Fryczkowski et al⁷¹ using scanning electron microscopy also found a drop-out of the choriocapillaris and they described additional findings such as increased tortuosity, dilation, narrowing, hypercellularity, vascular loop, microaneurysm formation, and sinus-like structure formation between choroidal lobules. Another important histologic study demonstrating evidence of changes in the choroid of Diabetic patients was performed by Cao et al⁷² in 1998: they described two types of choriocapillaris degeneration, focal and diffuse, and the evidence of neovascularization and increased basal laminar deposits. Focal choriocapillaris degeneration was found to be more prominent in the posterior pole than in the equatorial or peripheral choroid, not associated to neovascularization and 4-fold greater in diabetics than in nondiabetics. As choriocapillaris degeneration increased from focal to diffuse, neovascularization was identified beneath the RPE cells, and most were in the peripheral choroid. Diffuse choriocapillaris degeneration was associated with increased thickness of Basal Laminar Deposits, suggesting that deposition of this material at Bruch’s membrane was related to the atrophy of the choriocapillaris. They also postulate that visual acuity loss can occur due to diabetic

choroidopathy before having retinopathy. In 2013, Luty et al⁷³ described same findings described previously by Cao et al, but they introduced two types of choroidal neovascularization: the intrachoroidal regarding capillary network near the lamina fusca, and the extrachoroidal located primarily between the retinal pigment epithelium and the Bruch's membrane and within the latter. Neovascularization was found more peripherally.

Flow studies, whether quantitative or dynamic, also showed evidence of changes in the choroid of diabetic patients suggesting Diabetic Choroidopathy. Dimitrova et al in 2001⁷⁴ using Color doppler imaging showed that in early stages of diabetic retinopathy the choroidal circulation is affected with findings suggesting occlusive or hyper viscosity phenomena reducing blood flow. In 2004, Nagaoka et al⁷⁵ using laser doppler flowmetry demonstrated that the choroidal blood flow in the foveal region was significantly lower in patients with Diabetes, especially those with macular edema. Pemp et al⁷⁶, in a review of literature found some contradictory data but the most consistent was that studies assessing the choroidal blood flow beneath the fovea with the use of laser doppler flowmetry delivered more consistent results, indicating a reduction of choroidal blood flow in patients with nonproliferative and proliferative diabetic retinopathy.

Studies using imaging techniques for choroidal and retinal blood flow also demonstrated changes in diabetic eyes. Shiragami et al⁷⁷, found on Indocyanine green angiography choroidal abnormalities that they described as: hypofluorescent spots, small and large hyperfluorescent spots. The severity of diabetic retinopathy was significantly associated with the presence of hypofluorescent spots. Hua et al in

2013⁷⁸ also described the same findings and found late choroidal nonperfusion regions more predominant in advanced stages of retinopathy (proliferative). They described an “inverted inflow phenomena” referring to a finding where choroidal vessel filling time was longer than retinal vessel filling time.

Both from histologic and angiographic studies we do have evidence that there is a Diabetic choroidopathy. Histologic proof or diagnosis can only be obtained from enucleated or post-mortem eyes, with only retrospective value. Angiographic exams can be performed *in vivo* with diagnostic and prospective clinical value, but are invasive, and with limited capacity of choroidal changes information due to limited resolution and natural image overshadowing by the pigment of the RPE. Ultrasonography and Doppler flowmetry are another ophthalmological exams that can give limited information when we want to evaluate the choroid.

The technology improvement in Optical Coherence Tomography in the last 10 years has brought about the possibility to evaluate the choroid in a noninvasive exam, giving more detailed and new information correlated to physiologic and pathologic states.

1.4. OPTICAL COHERENCE TOMOGRAPHY — A METHOD TO VIEW THE CHOROID

Almost 30 years ago, ocular and especially posterior pole imaging was revolutionized with a new technology, the Optical Coherence Tomography (OCT) described by Huang et al. from their work at the James Fujimoto laboratory at the Massachusetts Institute of Technology (MIT).^{14,15} The technique was an optical

imaging modality using the same rationale of ultrasonography of measuring backscattering signal, but using light instead of sound. It allowed in a noninvasive, noncontact, simple and rapid way to image cross-sectional anatomy of the retina. First in vivo images were shown in 1993 and since 1996 when the first commercial device was released, it became widely used and now it is an indispensable tool in current clinical practice in Ophthalmology.^{15,79} OCT is based on low-coherence interferometry employing near- infrared light to produce cross-sectional two- and three-dimensional high resolution images.^{14,15,80}

The first device was an innovation for retinal clinical practice, but it had some limitations in image quality. Those limitations were related to the scanning speed (100 A-scans/second) and the technology used, the Time Domain (TD). Structures and layers of the retina were identified by software in a false color code to facilitate diagnosis, since the resolution was broad. The quality of images was highly susceptible to movement and other factors. In the subsequent models the TD-OCTs were improved in image quality, resolution and speed of acquisition. It evolved from 100 A-scan/s with 20 μ of axial resolution for the 1st OCT to 400 A-scans/s with 10 μ of axial resolution for the last TD-OCT, the SRATUS from Zeiss. With the latest TD-OCT, image resolution of the retina and details improved, but due to highly pigmented retinal pigmented epithelium, signal was unable to penetrate deeper and image the choroid. From the first commercial device, it took about OCT imaging 10 years to make the leap. The technology switched from Time domain to Frequency or Fourier Domain (FD). Basically, the image is obtained from backscattered light as frequency information acquired with a light source, charge-coupled device (CCD) camera, and a spectrometer, the Spectral Domain OCT (SD-OCT) or by sweeping a

narrow-bandwidth source through a broad range of frequencies with a photodetector, the Swept source OCT (SS-OCT). These new OCTs use light sources from 880nm for SD to 1060nm for SS. With these improvements in technology, along with improvement and development of software, tracking, averaging, digital image corrections, it is now possible to have devices with axial resolution up to 2μ , acquisition speed of 100 000 A-scan/s. Image resolution and depth penetration of the signal allow good and detailed visualization of the retina and the choroid, three-dimensional and volumetric information.¹⁵

The interest and studies of the choroid with OCT were driven with the first description of the Enhanced Depth Imaging by Spaide¹⁷ with the SD-OCT Spectralis from Heidelberg Engineering and later with the SS-OCT. With those technologies the difficulty in viewing the choroid and its scleral limit due to scattering of light by the pigment of the RPE was solved. With both it become possible to visualize the choroid until the scleral limit and sometimes beyond that, with good identification of the different vascular layers and the suprachoroidal space. Choriocapillaris microscopic details still exceeds the resolution capacity of these devices.

Several ocular diseases were studied and important findings were reported in Central Serous Chorioretinopathy, Diabetic Retinopathy, Glaucoma, Tumors, Age Related Macular Disease, High Myopia, Inflammatory diseases and some inherited retinal diseases.^{81,82,83}

Since OCT choroidal morphologic or anatomic findings were and still are not well known, most studies tried to correlate with pathology the easiest parameter to evaluate, the choroidal thickness.

Until the end of 2014, year of start of our study, the status regarding imaging the choroid with OCT was as described below.

Mrejen and Spaide⁸⁴ published in 2013 a very good review regarding Choroidal OCT imaging. They found that in most studies the choroidal thickness was measured with the anterior limit at the outer edge of the RPE and the posterior limit of the choroid was considered as the inner border of the hyperreflective surface posterior to the large choroidal vessels, named as scleral/choroidal interface. Several studies evaluated and found good intersystem and interobserver reproducibility and repeatability of choroidal thickness measurements.⁸⁵⁻⁹³ Studies in normal or healthy populations were made in order to determine normal thickness values and the effect of various parameters (Table 1)^{18,86,94-104}.

Author	Year Publication	n eyes	mean age (years)	±SD	range (years)	mean SFCT (µ)	±SD	range (µ)	Correlation age	Country	OCT
Margolis	2009	54	50.4		19-85	287	76		-15.6/10Y	usa	SD
Manjunath	2010	34	51.1		22-78	272	81			usa	SD
Ikuno	2010	79	39.4	16	23-88	354	111	191-573	-14/10Y	Japan	SS
Rahman	2011	100	38		30-49	332		142-563		GB	SD
Hirata	2011	31	64.6	17.3	21-87	202.6	83.5		-30/10Y	Japan	SS
Ding	2011	420	49.73	17.89	20-85	261.93	88.42			China	SD
Ouyang	2011	55	32.85	11.45	20-68	297.8	82.2		-19.5/10Y	usa	SD
Chen OD	2012	100	38	5	30-49	334	94	172-568		australia	SD
Chen OS	2012	100	38	5	30-49	333	90	133-555		australia	SD
Shin	2012	57	45.28	14.8	23-80	270.82	51.4	161-383	-13.1/10Y	Korea	SD
Wei	2013	3233	64.3	9.6	50-93	253.8	107.4	8-854	-33/10Y	China	SD
Rea d	2013	194	8.2	1.9	4-12	330	65	189-538		australia	SD
Sanchez-Cano	2014	95	23.8	3.2	19-32	345.67	81.8	152-519		spain	SD
Pappuru	2014	221	42.8	13.6	21-80	280.1	46.5		-11.8/10Y	india	SD

Table 1 — Most cited studies of Choroidal Thickness in healthy population
 Legend: n — number; SD — standard deviation; SFCT — subfoveal choroidal thickness; µ - micron; OCT — optical coherence tomography technology; SD OCT — spectral domain; SS OCT — swept source. Blank spaces mean lack of data on publication.

Table 1 shows that there is a great variability between the published studies regarding the sample size, mean and range of subjects age. But the greater variability is in the subfoveal choroidal thickness (SFCT) measurement, with variable mean values with great standard deviations (SD) and large range of thickness measurements. Not all studies presented all data, missing in some the information regarding SD values or the range of measurements. The studies were performed in different ethnicity populations, but no evidence at the time indicates that it can be a bias factor. Almost all studies reported strong correlation with age, with a decrease in thickness with ageing, some indicating the rate of thickness loss per year.^{18,96,98-101,103} But Ding et al in their study stratified the subjects by age and found no correlation of choroidal thickness with age in the group less than 60 years old. Negative correlation was found only with the older population.¹⁰⁰ On the other hand, Read et al. in their study in a pediatric population found that choroidal thickness is thinner in the youngest and get thicker until the teen age.⁹⁴ In the largest population study, the Beijing Study, they found the greater variability and range of choroidal thickness measurements, and found significant correlation with a multitude of parameters such myopia, axial length, high blood pressure, deep anterior chamber depth and others.¹⁰⁴ The great variability of choroidal thickness was noted by Kahn et al in a comment to the study of Rahman (more than 80% of choroidal thickness variation not explained by age) postulating that other causes may be behind this variability than age alone.^{105,86} Choroidal thickness was evaluated in some studies with several measurements in different locations or as macular volume or maps measurements.^{89,95,99,101,106-112,113} The common finding in those studies is that in healthy subjects the thicker point of the choroid is found centrally and the thicker

quadrant is usually the superior and the thinnest the nasal. Correlation of choroidal thickness measurements was found with other factors such as diurnal variation, blood pressure, water intake, coffee, thicker choroids.^{83,92,114–119} Some authors tried to look to vascular choroidal morphology.^{120–126} Most of these studies are descriptions of software development with no application or reproducibility for use with current available devices used in clinics. Nevertheless Zhang et al. concludes in their work that it is possible to do segmentation of most of the choroidal vasculature with standard SD-OCT.¹²¹ The only study that describes and characterizes normal findings on OCT images of the choroidal vasculature was the one published by Branchini et al.¹²⁷ After evaluating images of a wide-age range of healthy subjects (23 to 89 years) they conclude that normal/healthy vascular morphology on OCT images of the choroid includes the following characteristics: 1 — choroid is thicker in subfoveal zone; 2 — the posterior boundary or choroid-scleral border has a convex or “bowl” shape and is clearly identifiable; 3 — there is no focal thinning ; 4 — the continuum in size of choroidal vessels axially with “even”, i.e., that larger vessels lie closer to the choroid-sclera junction and smaller vessels closer to the Bruch’s membrane; 5 — and the large vessels are uniformly spaced. Suprachoroidal layer was described only by Rahman⁸⁶ and Yiu¹²⁴ as the hyporreflective layer or space visualized in some patients, posteriorly to the hyperreflective limit that lays after the large choroidal vessels. It is more frequent in hyperopic eyes and may be a cause of misjudgment of the correct limit for choroidal thickness measurement.

1.5. LITERATURE REVIEW ON DIABETIC CHOROIDOPATHY ANALYSED WITH OCT

The literature search was done using the PubMed, Web of Science databases engines and Google search using selective and advanced search filters with the words: diabetic/ Diabetes/ choroid/ choroidopathy/ OCT/ optical coherence tomography, to identify all pertinent and peer-reviewed publications until 2014.

A few cross-sectional studies were published looking for choroidal changes in diabetic patients. The majority of authors found a decrease in choroidal thickness in diabetic patients but with different patterns. Esmaeelpour et al. found in type 1 and type 2 diabetic patients that the CT was thinner in diabetic patients when compared with controls, particularly centrally, but with no correlation with retinal thickness. No focal CT thinning was found below retinal lesions^{128,129} Regatieri et al. and Unsal et al. found significant CT thinning when compared with controls only in severe cases of diabetic retinopathy (DR) as proliferative diabetic retinopathy (PDR) and macular edema (ME). Mean values of CT for control and early stages of DR were similar.^{81,130} Querques et al. also found decreased CT in diabetic patients, even with no evidence of DR. They describe focal thinning of the choroid correlated with suprajacent retinal thickening. In contrast Vujosevic et al. and Lee et al, describe CT thinning but only in patients with evidence of DR, and no correlation was found with clinically significant macular edema (CSME).^{131,132} Two groups looked specially for the correlation with diabetic macular edema (DME). Hua et al. compared findings in subjects with DME and submacular detachment (SMD) or DME without SMD. CT was thinner in those patients without SMD.⁷⁸ Gerendas et al. showed a significant

decrease in CT in eyes with DME and in the counter-lateral eye with no DME when compared with controls, but no correlation was found between CT and retinal thickness (RT).¹³³ When looking to younger populations, Sayin et al. found no difference in CT between diabetic and control patients.¹³⁴ Duration of Diabetes was found to have a weak correlation with CT by Yülek et al.¹³⁵ and microalbuminuria was found correlated with CT thinning in pre-retinopathy diabetic patients.¹³⁶ CT appeared to increase after intensive control of several systemic and metabolic factors.¹³⁷ There was two studies within all those published until 2014, with a large sample of subjects analyzed reporting, controversially, an increase in CT. Kim et al found an increase of CT with increasing severity of the DR. Only subjects with treated PDR had a decrease in CT. They found that CT increased progressively from cystoid DME, diffuse DME to DME with SMD.¹³⁸ In the other study, Xu et al. found, after adjusting for other factors, a significant positive correlation between CT and the diagnosis of Diabetes and glycosylated hemoglobin serum values, but none with the presence or severity of retinopathy. Significant correlation was found with a variety of parameters, ocular and systemic, suggesting that CT measurements are multifactorial dependent.¹³⁹

Findings had some discrepancies between studies, probably due to different designs and analysis made. The sample of subjects also was very variable between studies and in several just a few parameters were taken in account (Table 2)^{78,128,130,131,136,138–142}.

CHOROIDAL THICKNESS AND MORPHOLOGY ANALYSED BY OPTICAL COHERENCE TOMOGRAPHY AS A METHOD TO APPROACH DIABETIC OCULAR DISEASE PROGNOSIS AND PROGRESSION

Author	n	Age		TOTAL			NDR			MNDR			SNPDR			PDR			DME			DMESMD				
		(mean years)	±SD	Range (years)	SFCT (mean μ)	±SD	Range (μ)	SFCT (mean μ)	±SD	Range (μ)	SFCT (mean μ)	±SD	Range (μ)	SFCT (mean μ)	±SD	Range (μ)	SFCT (mean μ)	±SD	Range (μ)	SFCT (mean μ)	±SD	Range (μ)	SFCT (mean μ)	±SD	Range (μ)	
Esmaci pour et al	63			41-82			214	55	114-365	208	49	122-313	205	54	122-321					211	76	117-365				
Hua et al	18						280.6	68.6												276						
Vojosevic et al	102	57.5	13.3	31-83						279.4	81.6									230.5	25.8					
Regallier C et al	49	68								222	21.6									162.7	7					
Farias et al	62					2238.87																				
Kim et al	235	62.6	12.4				262.3	68.4		244.6	77		291.1	107.7						363.6	74.9					
Lee et al	203	58	12	32-78			219.1	47.8	98-318	158	56.3	111-326	161.2	38.5	101-398					228.5	38.9	164-284				
Xu et al	246	66	9.2				266	108	45-724																	
Unsal F et al	151	60.5	8.2							235.4	84.5									203.8	46.8					
Querques G et al	63	65	9	48-83			238.4	47.9		207	55.9									190.8	48.4					

Table 2 — Most cited studies of Choroidal Thickness in Diabetic population
 Legend: n — number; SD — standard deviation; SFCT — subfoveal choroidal thickness; μ - micron; NDR — no diabetic retinopathy; MNDR — mild/moderate nonproliferative diabetic retinopathy; SNPDR — severe nonproliferative diabetic retinopathy; PDR - proliferative diabetic retinopathy; DME — diabetic macular edema; SMD — submacular detachment. Blank spaces mean lack of data on publication.

All authors considered mean thickness values to perform the analysis and correlations except on the paper published by Adhi et al.¹⁴³ On their work they looked for choroidal vascular changes occurring in diabetic patients. They used the choroidal morphologic features described by Branchini for healthy subjects.¹²⁷ They found that more than 90% of the diabetic patients had irregular choroidoscleral contour (or S shaped) in contrast to none on the control group. Diabetic patients had thinning of central CT and focal CT thinning zones, more frequent in DME. None was found in controls. There was a decrease in large choroidal vessel layer thickness in DR eyes.

CHAPTER 2 — REASON AND PURPOSE OF THE STUDY

2 — REASON AND PURPOSE OF THE STUDY

From histological, flowmetry and angiographic studies, we do know that there is a diabetic choroidopathy. Choriocapillaris drop-out, focal or lobular lesion, occlusion and blood flow impairment, vasodilatation, tortuosity and neovascularization are changes occurring in the choroid in Diabetes. We also know that the choroid has an important role in posterior retinal segment function and choroidal malfunction or pathology can be on the origin and/or consequence of the retinal pathology.^{69,70,144–}

146

Optical coherence tomography has revolutionized imaging of the eye. With the improvement of the technology it is now possible with the commercially available devices to better view the choroid to study ocular pathology. Several studies were published regarding choroid imaging in healthy and diabetic patients. Nevertheless, discrepancies in results are found.

We found a lack of studies trying to correlate vascular morphology of the choroid with the retinal disease. The choroid is a tissue with a particular anatomy where previous studies had demonstrated a certain independence in function of the lobular units of the choriocapillaris and a possible focal effect in the retina immediately above. On the other hand, the choroid as a highly vascularized tissue me be affected by several other factors, in physiological or pathological systemic conditions.

Choroidal thickness is a parameter that increases or decreases with choroidal vascular changes. But from the studies on healthy populations we can find that there is a great variability of measurements, dependent on individual characteristics, age,

ocular and systemic factors, and others so a cut off or mean normal value stays difficult to establish. Beside the limitations of the published studies pointed above, the most important is may be the lack of correlation of morphological findings with thickness measurements and longitudinal or over time evaluations for progression.

2.1. MAIN STUDY PURPOSE

The main purpose of this study is:

- To evaluate whether choroidal thickness measurement alone is a reliable parameter to characterize diabetic choroidopathy;
- To characterize choroidal morphological findings using the OCT and correlate these findings with choroidal thickness and the diabetic retinopathy
- To determine if diabetic choroidopathy can be identified, classified and used as a biomarker of ocular diabetic disease and progression.

2.2. SECONDARY, ANCILLARY OR PILOT STUDY PURPOSE

This study has the following secondary, ancillary or pilot purposes:

- To explore subjects, diabetic and healthy controls, for ophthalmological facts, as best corrected visual acuity, intraocular pressure, biomicroscopy of the anterior segment, ocular fundus examination and imaging.
- To define vascular morphological changes identifiable on OCT images as possible markers of choroidopathy
- To investigate demographics, systemic and metabolic status.

- To collect data for both individual and global statistical analysis
- To provide biomedical translation of our results

CHAPTER 3 — MATERIAL AND METHODS

3 — MATERIAL AND METHODS

3.1. DESIGN OF THE STUDY AND SETTING

The whole study consisted in:

— A PILOT STUDY — A pilot study was performed with a small sample of patients that were analyzed for OCT images to define the morphological findings classification to be used in the whole and main study.

— An ANCILLARY STUDY — This study consisted of collecting a small sample of images obtained with the swept-source OCT in collaboration with another Ophthalmology Department (Instituto Gama Pinto, Lisboa, Portugal) in order to have representative images of superimposed retinal e choroidal maps obtained automatically by the OCT software.

— The MAIN STUDY — This consisted in the major data source for the analysis and results. The study was performed at the Ophthalmology Department of the Centro Hospitalar Entre o Douro e o Vouga (CHEDV), Santa Maria da Feira, Portugal, from May 2014 to 2018. It was a cohort, prospective, longitudinal and observational study, where diabetic and healthy controls subjects attending the Medical Retina and General Ophthalmology consultations were submitted to: complete ophthalmological exam; fundus imaging by photography, OCT and Fluorescein Angiography (the later when indicated); familiar/hereditary, systemic and metabolic review; blood pressure registration; and blood collection when required. The subjects were followed up in consecutive visits according to the guidelines for the clinical disease state and

directed to correct treatment whenever it was indicated. The follow up and evaluation period for the study was intended to be for 2 years.

3.2. MAIN STUDY SUBJECTS

The subjects participating on the study were divided in two groups: Group 1 of Diabetic patients and Group 2 of healthy control subjects.

3.2.1. GROUP 1 — INCLUSION CRITERIA

Subjects for this group were selected from the patients attending the Ophthalmology department visits, with the diagnosis of Diabetes, with none or any stage of diabetic retinopathy, aged 18 or more and who had given and signed voluntarily the consent to participate in this study.

3.2.2. GROUP 2 — INCLUSION CRITERIA

Subjects for this group were selected from non-diabetic patients attending the Ophthalmology department visits, aged 18 or more and who had given and signed voluntarily the consent to participate in the study.

3.2.3. EXCLUSION CRITERIA (BOTH GROUPS)

Subjects were excluded from the study when one of the following was present: unwillingness or inability to give the consent to participate in the study; previous treatment of any kind for diabetic retinopathy (laser, intravitreal injection of anti-VEGF or steroid, vitrectomy); previous or ongoing chorio-retinal disease; history of

intra-ocular inflammatory, infectious or oncologic disease; history of ocular surgery; media opacities affecting good visualization of the posterior segment; refractive errors greater than ± 6 Diopters; systemic oncologic disease; systemic chronic steroid or immunosuppressive medication; any serious and uncontrolled systemic condition.

3.2.4. DROP OUT or LOST TO FOLLOW UP (DO or LFU)

After subject inclusion in the study, if any of the exclusion criteria occurred the patient/subject was dropped out from the study. Patients submitted to anti-VEGF treatment during the study were dropped out for the natural course and subfoveal choroidal thickness progression analysis but were considered for the choroidal morphologic changes analysis. If the patient failed to attend any visit other than baseline during the study period for any reason, he/she was considered as loss to follow up.

3.3. MAIN STUDY CLINICAL EVALUATION

All clinical and exams data were collected and registered in the source document (the hospital file) and recorded for the study in the Case report forms (CRF).

The subjects were submitted to clinical history collection for ophthalmological, systemic and familiar anamnesis. All were submitted to complete ophthalmological exam including: Best corrected visual acuity using ETDRS equivalent charts; external ocular evaluation; complete slit-lamp biomicroscopic exam; Goldman tonometry; gonioscopy when indicated; dilated fundus exam with auxiliary fundus

lenses for posterior pole and periphery observation. Systemic evaluation consisted in registration of current medication, recent (within 3 month) blood analysis results including glycosylated hemoglobin for diabetics, performed by the family or assistant doctor. When not available, these exams were requested. Measurement of blood pressure and record of the time of measurement was performed.

Diabetic retinopathy stage was graded and recorded based on funduscopy and fundus photography observation according to the International Clinical Disease Severity Scale for Diabetic Retinopathy³⁸, as follows: No apparent diabetic retinopathy (NDR) — no findings found; Mild non-proliferative diabetic retinopathy (Mild NPDR) — only microaneurysms (Ma); Moderate non-proliferative diabetic retinopathy (Moderate NPDR) — more than just Ma and less than severe NPDR; Severe non-proliferative diabetic retinopathy (Severe NPDR) — more than 20 intraretinal hemorrhages in the 4 quadrants and/ or venous beading in 2 or more quadrants and/or prominent intraretinal microvascular abnormalities (IRMA) in 1 or more quadrant with no signs of proliferative DR; Proliferative diabetic retinopathy (PDR) — neovascularization of the disc or elsewhere and/or vitreous/preretinal hemorrhage. Macular edema classification was based on OCT findings.

These evaluations were performed in all subject visits.

3.4. IMAGING ACQUISITION AND ANALYSIS

Imaging exams consisted of Fundus photography, Optical Coherence Tomography and Fluorescein Angiography. All exams were performed by experienced Imaging Technician/Orthoptist.

3.4.1 FUNDUS PHOTOGRAPHY

In all visits the subjects of the study were submitted to dilated posterior pole photography performed with the Non-midriatic Retinograph TRC NW8® from Topcon Corporation. When Fluorescein Angiography was done, fundus photography was performed using the Angiograph (see below).

3.4.2. FLUORESCHEIN ANGIOGRAPHY

Whenever it was clinically indicated, fluorescein angiography was performed according to normal procedures for the exam¹⁴⁷, using the Digital Angiograph FF 450 plus® from Carl Zeiss Meditec. Image analysis and report was done always by an Experienced Retina Specialist.

3.4.3. OPTICAL COHERENCE TOMOGRAPHY (OCT)

3.4.3.1. OCT DEVICES

Most of the main study's OCT image acquisitions were performed using the OCT CIRRUS HD-OCT® 4000 from Carl Zeiss Meditec. It is a spectral domain OCT using a super luminescent diode (SLD) at 840nm, with a scan speed of 27000 A-scans/s, an A-scan depth of 20 μ , an axial resolution of 5 μ and transverse resolution of 15 μ . The device had an upgraded software with EDI and Fast-track.

Pilot study's OCT image acquisitions were performed using the:

- OCT RS-3000 Advance® from NIDEK Corporation, Ltd. It is a spectral-domain OCT using a SLD at 880 nm, with a scan speed of 53 000 A-scans/s, with enhanced retinal and choroidal acquisition protocols and a tracking software.
- Spectralis OCT2 ® from Heidelberg Engineering. It is a spectral-domain OCT using a SLD at 870 nm, with a scan speed of 85 000 A-scans/s, with eye-tracking software, increased depth resolution and automated retinal layer segmentation.
- DRI OCT-1 Triton plus® from Topcon corporation. It is a swept-source OCT using a light source of 1050 nm, with a scan speed of 100 000A-scans/s. Its software has the particularity to have an automated layer segmentation function including the choroid with the ability to provide topographic maps.

3.4.3.2. ACQUISITION PROTOCOLS

OCT image acquisition was made for all study subjects in all visits.

Image acquisition protocols were defined to have 3 dimensional or cube/volume information for retinal thickness maps and macular edema location, and line scans with best resolution for retina and choroid morphologic evaluation and depth penetration for good sclero-choroidal interface identification.

For the CIRRUS OCT, we performed to all patients the Macular CUBE 512x128 acquisition protocol centered in the central fovea to obtain the macular thickness map. Then a HD line scan with EDI and the maximum averaging of 20 was obtained passing through the fovea and in the presence of extra-foveal macular edema through the maximum retinal thickness zone. The best line scan for posterior choroid limit was selected for analysis.

For the RS-3000 OCT we used the Macular CUBE 512x128 acquisition protocol centered in the central fovea to obtain the macular thickness map. Then a Macula cross scan in the choroidal mode with an averaging of 30 was obtained passing through the fovea and, in the presence of extra-foveal macular edema, a line scan was obtained passing through the maximum retinal thickness zone. The best line scan for posterior choroid limit was selected for analysis.

For the Spectralis OCT we performed also a macular cube and a line scan with an averaging of 20 to 30 following the same guidelines for the other devices.

The DRI OCT-1 Triton image acquisitions were performed in another Ophthalmology department from the Instituto Gama Pinto, Lisboa, Portugal, included in a sub-study. Acquisitions were performed to obtain macular thickness maps, line scans with choroidal definition in the foveal and macular edema zones, and automated choroidal thickness maps.

3.4.3.3. IMAGE ANALYSIS

Retinal and choroidal image analyses were made by one of two graders (Lilianne Duarte and Miguel Ruão).

Retinal analysis was carried out to evaluate findings correlated with diabetic retinopathy and to identify and locate macular edema. Morphological findings were changes in the normal anatomy of the retinal layers (hyper/hyporeflectivity, atrophy, cysts, disorganization of retinal inner layers (DRIL), photoreceptors layer integrity, new-vessels, subretinal fluid and others). Retinal thickness maps were evaluated to

identify Macular edema and classify it as central (foveal involvement) or extra-foveal (no foveal involvement). Central foveal retinal thickness (CFRT) value was registered. Any other abnormality found was also registered.

Choroidal analysis was made separately for thickness measurements and morphological evaluation. Only sub-foveal choroidal thickness (SFCT) measurement was recorded. The measurement was made manually, and boundaries were defined as going from the posterior limit of the RPE-Bruch Membrane complex to the outer limit of the great choroidal vessels before the hyperreflective layer (figure 1). The measurement was made always by the same grader for each eye. SFCT measurements were used for the statistical analysis. Images with low resolution or quality, hindering the identification of morphological features of choroidal posterior boundaries were excluded from the study (figure 2).

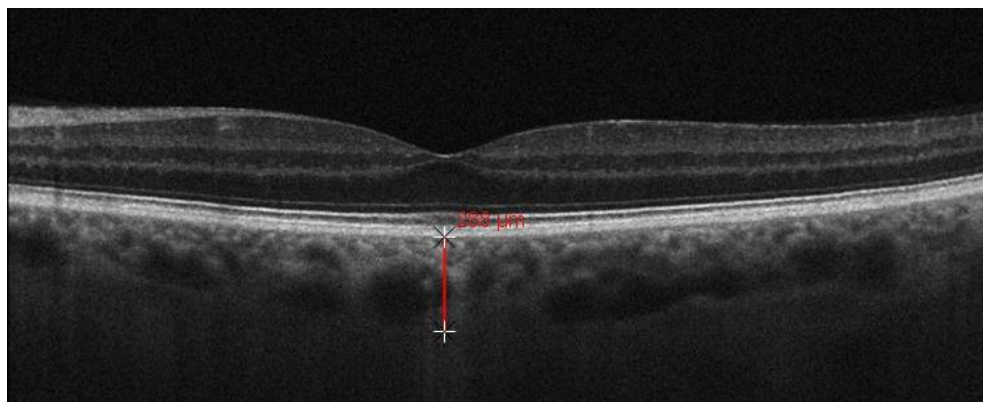


Figure 1 — Example of boundaries for the measurement of SFCT.

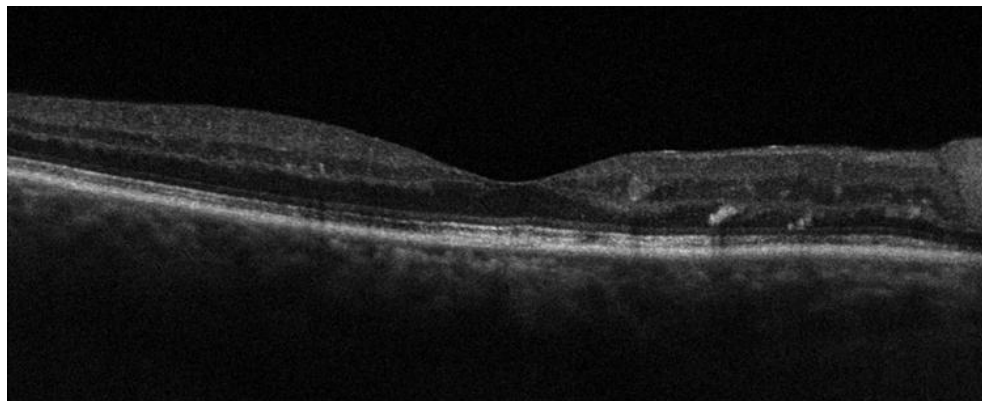


Figure 2 — Example of an image with inability to visualize the sclero-choroidal limit.

All OCT scans were made using the device tracking software and follow up images were obtained at the same location marked as baseline reference.

Choroidal morphological analysis was made based on the findings described by Branchini et al¹⁴⁸ for normal choroid: 1- choroid is thicker in subfoveal zone; 2- the posterior boundary or choroid-scleral border has a convex or “bowl” shape and is clearly identifiable; 3- there is no focal thinning ; 4- the continuum in size of choroidal vessels axially with “even”, i.e., that larger vessels lie closer to the choroid-sclera junction and smaller vessels closer to the Bruch’s membrane; 5- and the large vessels are uniformly spaced (Figure 3). Additionally, we performed a pilot study to characterize abnormal findings in diabetics and establish a classification to use in this study. Morphological findings were analyzed and correlated with superjacent retina to evaluate any existing anatomical correlation.

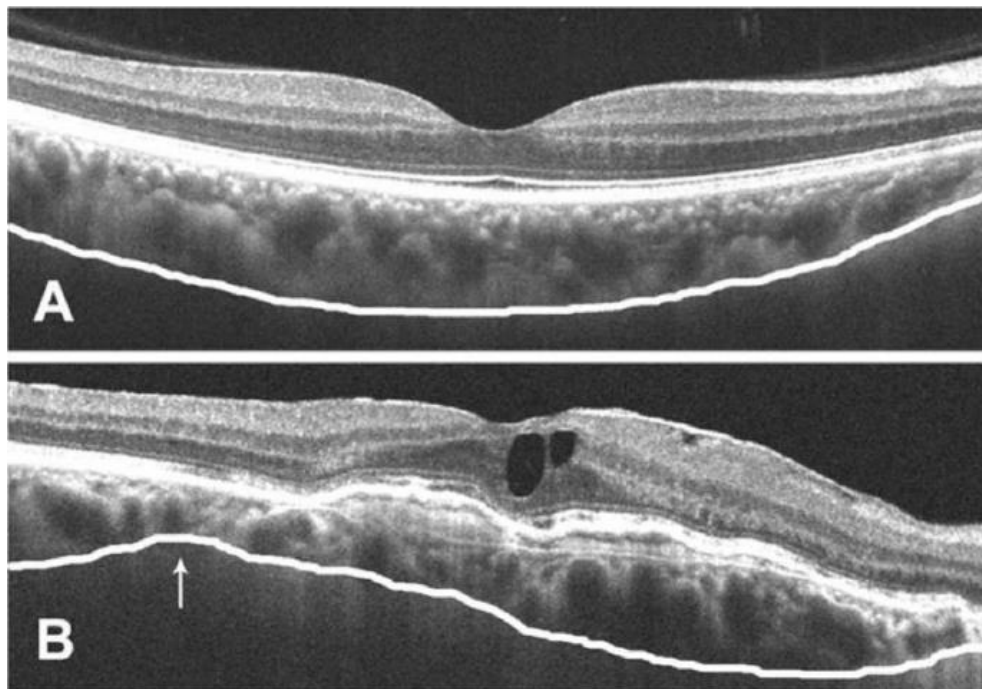


Figure 3 — Choroidal morphological analysis from Branchini et al.

From “Analysis of Choroidal Morphology and Vasculature in Healthy Eyes Using Spectral-Domain Optical Coherence Tomography”. *Ophthalmology*, 2013¹⁴⁸. Reproduced with permission. A — SD-OCT image of a healthy subject with the bowl shape of the sclero-choroidal limit (white line), even distribution of large choroidal vessels in the nasal-temporal plane, even continuum of choroidal vessels size with larger vessels located outest in the choroid and smaller in the inner choroid. B — SD-OCT image of a diseased eye with an irregular “S” shaped sclero-choroidal border (white line), a focal thinning of the choroid (white arrow), dislocation of the sub-foveal thickest choroid point and proximity of large choroidal vessels of the EPR/Bruch’s membrane posterior border.

Choroidal automated thickness maps (from SS-OCT images) were compared and correlated to superimposed retinal thickness maps and morphologic retina and choroid line scans.

3.5. STATISTICAL ANALYSIS

Statistical analysis was performed by an external statistician, accessing only the coded database and using Stata / SE statistical software version 12.0 (StataCorp LLC).

The normality of the variables was first tested to select the appropriate statistical tests. The normality was tested in general and by groups (control and diabetic) using the Shapiro-Wilk test. Since most of the distribution of variables were not normally distributed, non-parametric tests were selected

For continuous variables, the Mann-Whitney test was used to compare two independent groups (such as control and diabetic groups). For the comparison between more independent groups, such as DR grade, the Kruskal-Wallis test was used. For categorical variables the Fisher's test was used. The differences between two dependent variables (e.g. between visits), as well as between OD and OS, were performed using the Wilcoxon test for continuous variables. For categorical variables the McNemar test (for 2x2 tables, e.g., ME) or Stuart-Maxwell (for tables with more categories, e.g. DR grade) were used. Correlations between variables were obtained with the Spearman correlation coefficient.

In order to identify predictive variables for one continuous variable, and to study the impact these independent variables on a dependent variable (e.g. SFCT), a multivariate linear regression model was performed.

Statistical significance was considered for p -values lower or equal to 0.050.

3.6. ETHICS AND CONFIDENTIALITY COMPLAINE

The protocol of the study with the internal number CHEDV-OFT-01-14 and patient informed consent form was submitted to the Ethics Committee and Administration

Board of the CHEDV and approval was given on May 15th, 2014 (copy of the documents in Appendix 2 and 3).

The study was conducted following the tenets of the Declaration of Helsinki.

Data confidentiality was assured by coding patient identification on the database for analysis.

CHAPTER 4 — RESULTS

4 — RESULTS

4.1. PILOT STUDIES

A pilot study was performed to identify markers or morphological findings to differentiate normal from abnormal choroid and create a classification system for the study. The evaluation was first based on the classification made by Branchini et al¹⁴⁸ and then modified according to our findings. The results of this pilot study were presented at two congresses:

1. At the 15th EURETINA Congress, in September 2015, the results of this pilot study were presented with the poster entitled, **“Looking beyond thickness: choroidal findings with the Nidek OCT RS-3000 Advance”**.

Thirty eyes of thirty patients were included; 12 of which were from healthy controls and 18 from diabetic patients. In the diabetic group, 7 eyes had no DR, 5 eyes had mild NPDR and 6 eyes had ME and/or PDR.

OCT images were evaluated for choroidal morphological changes choroidal findings were classified as:

— Normal (figure 4) — when the sclero-choroidal border had an “inverted dome shape” (the bowl shape from Branchini) with the thickest choroidal point sub-foveal, and the “mottled” vascular layer of the choroid (corresponding to the choriocapillaris and Sattler’s smaller vessels layers) had an imaginary line limit to the great vessels layer that lays parallel to the Bruch’s membrane and/or the sclero-choroidal limit.

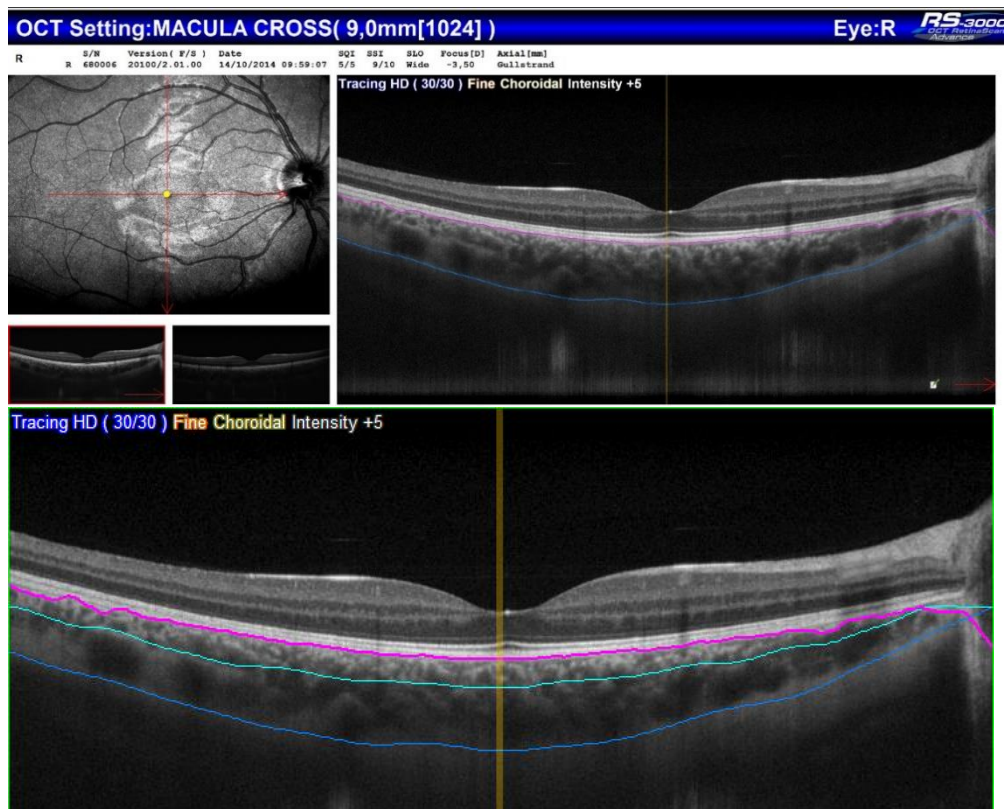


Figure 4 — Normal choroid morphology classification — pilot study.

Upper image showing the normal fundus and the choroid vascular feature. On the bottom the same image with the delineation limits: the Bruch's/RPE posterior border (purple line), the imaginary parallel line separating the mottled choriocapillaris/Sattler's layer and the great vessels layer (turquoise line) and the sclero-choroidal border (blue line).

— Abnormal (figures 5-7) — when one or more of the following changes were found: a loss of the “inverted dome shape” of the sclero-choroidal border; the vascular layers with absence or atrophy of great vessels layer; the choriocapillaris/Sattler's layer with focal or diffuse atrophy; irregularity of the parallel layers delineating line; and hyperreflective focal zones instead of the vascular hyporreflective images.

CHOROIDAL THICKNESS AND MORPHOLOGY ANALYSED BY OPTICAL COHERENCE TOMOGRAPHY AS A METHOD TO APPROACH DIABETIC OCULAR DISEASE PROGNOSIS AND PROGRESSION

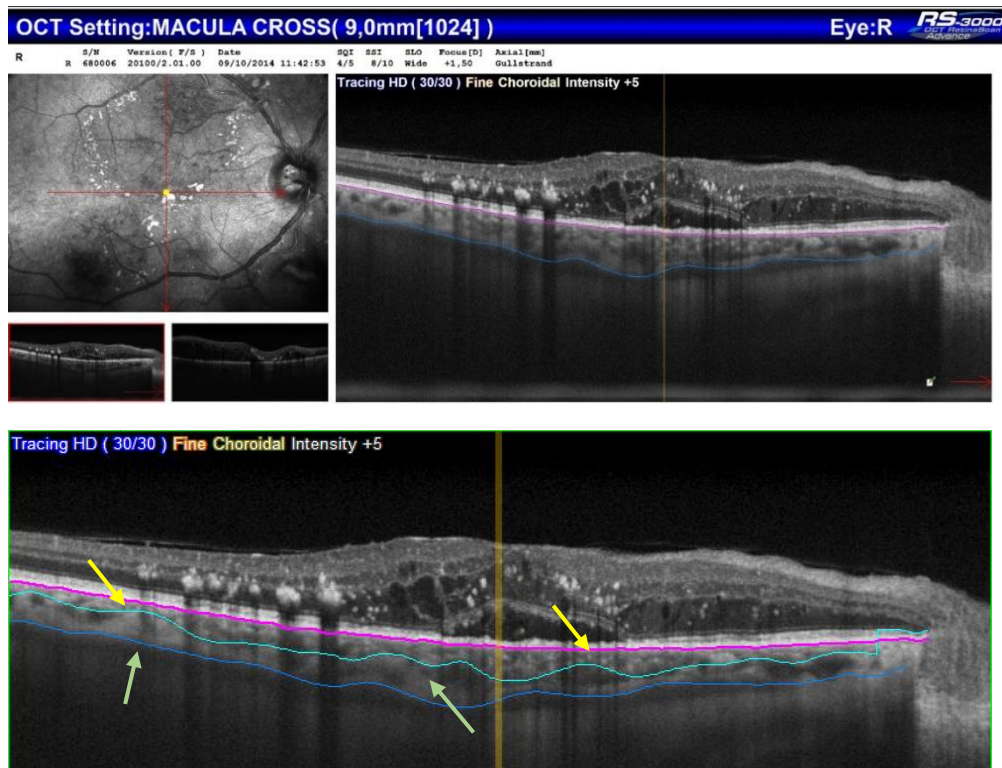


Figure 5 — Abnormal choroid morphology in Diabetic Macular Edema — pilot study. Upper image showing the fundus image with CSME and the choroid vascular feature. On the bottom the same image with the delineation limits: the Bruch's/RPE posterior border (purple line), the imaginary line separating the mottled choriocapillaris/Sattler's layer and the great vessels layer (turquoise line) irregular/non- parallel due to focal zones with atrophy or thinning (yellow arrows), focal lack of great vessels with hyperreflective space (green arrows), and the sclero-choroidal border (blue line) slightly irregular.

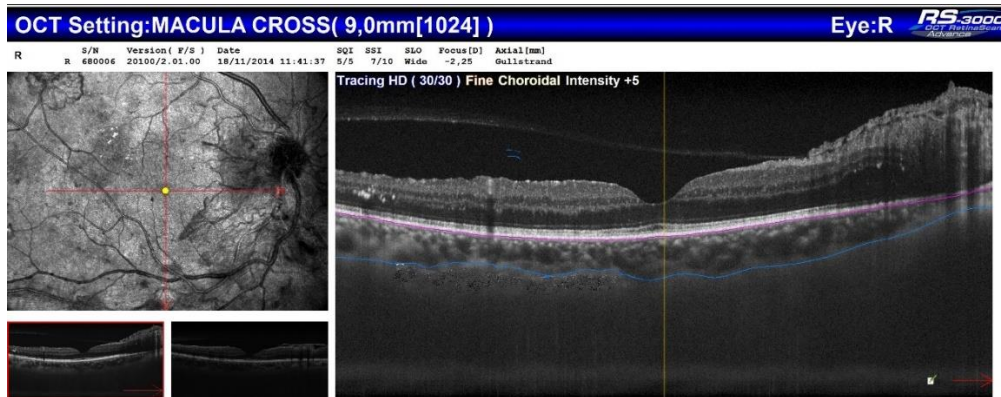


Figure 6 — Abnormal choroid morphology in PDR — pilot study.

On the fundus image large new vessels of the disc (NVD) and elsewhere (NVE) on the superior temporal arcade are seen. On the OCT line image: the Bruch's/RPE posterior border (purple line), an apparent preserved mottled choriocapillaris/Sattler's layer, the great vessels layer with a focal zone with atrophy and hyperreflective space temporally, and the sclero-choroidal border (blue line) slightly irregular with apparent moderate thinning of choroidal thickness.

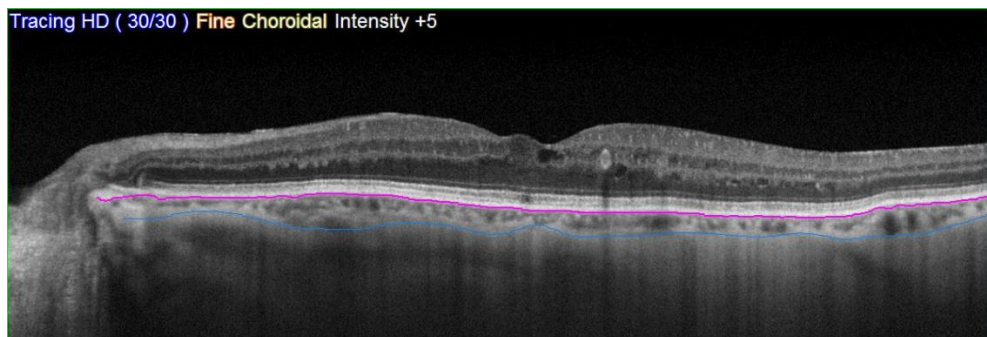


Figure 7 — Abnormal choroid morphology in PDR — pilot study.

This patient had new vessels on the retinal periphery. On the OCT line image: the Bruch's/RPE posterior border (purple line), but a very thin/atrophic choroid with atrophy of all layers and the inability to draw a limit between them. Loss of the "inverted dome shape" of the sclero-choroidal border (blue line).

When choroidal morphological changes were analyzed for the different groups, we found that, with the advance of the disease, there was a progressive loss of the normal "inverted dome shape" of the sclero-choroidal border and, with macular edema, focal changes in the vascular layers were noticed suggesting a vascular/blood recruitment of focal retinal suffering zones (figure 8).

CHOROIDAL THICKNESS AND MORPHOLOGY ANALYSED BY OPTICAL COHERENCE TOMOGRAPHY AS A METHOD TO APPROACH DIABETIC OCULAR DISEASE PROGNOSIS AND PROGRESSION

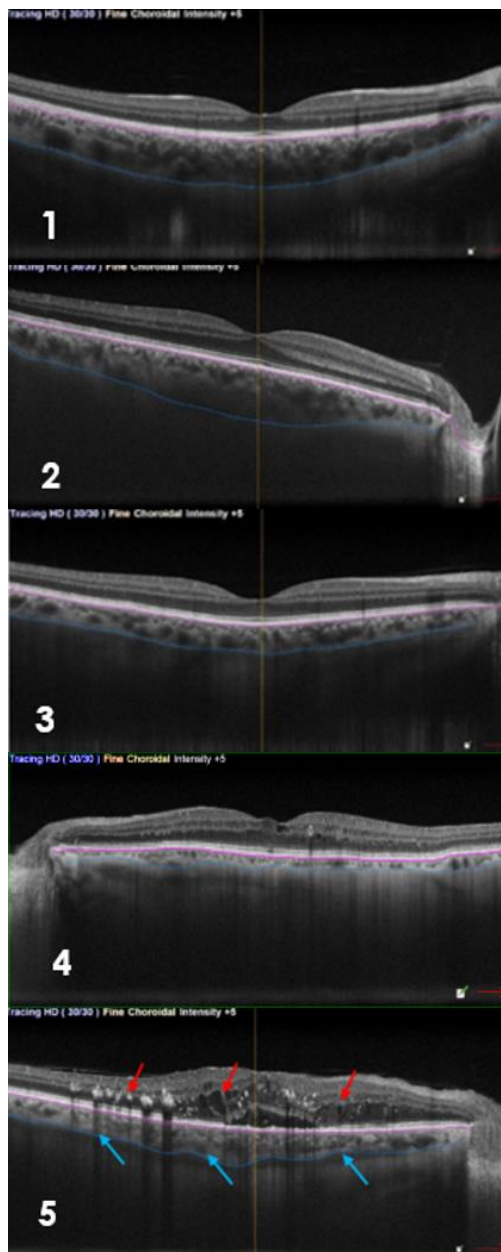


Figure 8 — Progressive change in choroid morphology in the different DR stages. Legend: 1 — Healthy control. 2 — Diabetic with no DR. 3 — NPDR. 4 — PDR. 5 — CSME.

2. At the EVER Congress on October 2015 the results of the pilot study were presented with the poster “**Focal Choroidal Changes on Diabetic Macular Edema**” (published abstract on the Acta Ophthalmologica¹⁴⁹).

Fifty-four eyes were included in this study: 8 with macular edema, 12 with non-proliferative diabetic retinopathy, 22 with no retinopathy and 12 controls. Age ranged from 22 to 80. Choroidal thickness varied from 61µm to 495µm. No correlation was found between SCFT and age, blood pressure or diabetic stage. Choroidal thickness showed high standard deviations values (Table 3).

	n	AGE	SFCT	SBP	DBP	DURATION DIABETES	HA1c
TOTAL	44	56.56±13.45	301.65±88.56	138.18±18.57	71.02±8.11		
CONTROL	12	50.58±12.59	312.08±41.85	132.17±20.14	74.75±19.52		
NDR	22	53.5±12.59	341.64±87.34	136.95±18.07	77.99±12.53	9.96±6.64	7.18±1.12
NPDR	12	62.67±9.71	265.42±75.79	137.33±18.44	75.33±8.56	13.42±5.55	7.76±2.05
ME/PDR	8	64.75±12.01	230.38±107.00	150.63±14.68	74±8.8	14.75±5.42	9.23±1.45

Table 3 — Demographics and Mean values of SFCT — pilot study

Legend: n — number; SFCT — subfoveal choroidal thickness; SBP — systolic blood pressure; DBP — diastolic blood pressure; HA1c — glycosylated hemoglobin; NDR — no diabetic retinopathy; NPDR — non-proliferative diabetic retinopathy; PDR - proliferative diabetic retinopathy; ME — macular edema.

In this study we found that, for advanced stages of retinopathy and macular edema, the changes in the architecture of the choroidal vessels with a tendency of vanishing of the large vessels in favor of the smaller and choriocapillaris and the changes in the sclero-choroidal border shape, were well correlated to the superjacent area of retinal active disease and edema.

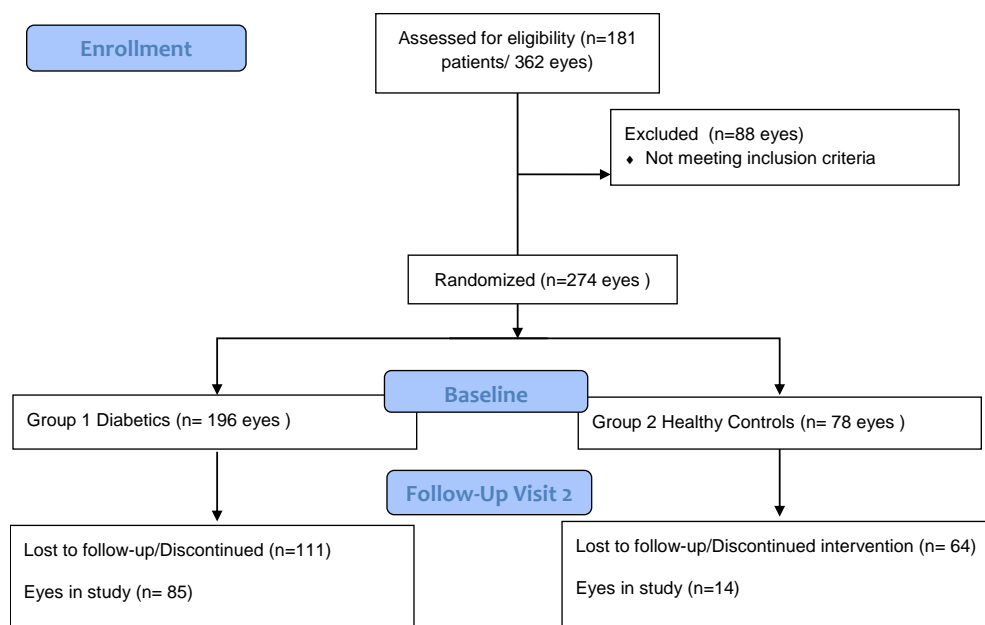
4.2. MAIN STUDY

The patient's study data collection was from May 2014 to February 2018.

One hundred and eighty-one patients (362 eyes) were selected for this study, where 129 (258 eyes) were diabetic patients (13 with type 1 Diabetes and 116 type 2 Diabetes) and 52 (104 eyes) were controls non-diabetic patients. Eighty-one (88) eyes were excluded from the study due to the following: 75 eyes — inability to identify the posterior limit of the choroid on the OCT image; 6 eyes — previous cataract surgery; 2 eyes — epiretinal membrane with traction; 2 eyes — previous focal macular laser; 1 eye — foveal atrophy from other causes; 2 eyes — drusen and foveal vitelliform lesion.

From the 274 eyes included in the study, 36,1% (99) had a second visit, 8.8% had 3 visits and only 3.9% had 4 visits during the study period. The eyes needing any kind of treatment considered as exclusion criteria were directed to do the treatment and were considered as drop-out of the study. Subjects with eyes with no disease or no need for treatment were counseled to perform a regular visit (6 months or 1 year later). Since it is an observational study, the scheduling of the visits was dependent on the family doctor and/or patient. Therefore, 36 eyes were dropped-out from the study: 4 had to be submitted to cataract surgery, 14 were directed to a loading dose of intravitreal anti-VEGF, 16 were directed to perform macular laser treatment and 2 eyes due to ocular hyperpressure, started medication with Latanoprost drops. 80 patients (160 eyes) did not have any other visit during the study period for unknown reasons, so they were considered as loss to follow up (LFU). Due to the small sample

of eyes with more than 2 visits, data were not considered for statistical analysis. The interval of time between the baseline visit and the second visit was of mean \pm SD: 424 days \pm 238 (mean 14 months: minimum 61 days maximum 1012 days) for diabetic patients and mean \pm SD: 391 \pm 276 (mean 13 months: minimum 105 days maximum 854 days) for healthy controls.



The analysis was made for morphological changes and for statistical results.

4.2.1 MORPHOLOGICAL ANALYSIS

For the morphological analysis all OCT images were observed and classified according to the retinal and choroidal macular anatomical/ morphological features.

Retinal analysis consisted in evaluating and classifying images as normal (with no abnormalities) or abnormal with diabetic retinopathy findings. The DR findings could be: evidence of increased thickness (focal or diffuse) in the retinal thickness map, cysts, hyperreflective spots (hemorrhages/exudates), disorganization of the layers, atrophy, fibrosis, new vessels, fibro-vascular proliferation, or others.

Choroidal analysis was based on the classification from the findings of the pilot studies as follows: normal sclero-choroidal border — with the “inverted dome shape” and the thickest point below the fovea; normal layers — with integrity of the mottled choriocapillaris/Sattler’s (ChS) and parallel to the Bruch’s membrane, homogeneity of the great vessels distribution; abnormal sclero-choroidal border — with loss of the “inverted dome shape” and irregular delineation; abnormal layers — with loss of the integrity of the mottled choriocapillaris/Sattler’s and parallel to the Bruch’s membrane, focal atrophy or increase thickness of vascular layers, loss of even distribution, hyperreflective spaces on the vascular zone.

The choroidal findings were correlated with the retina above.

For the 196 diabetic and 78 healthy eyes included at baseline the choroidal morphologic features are summarized by groups as shown in table 4.

Choroidal morphologic features	Healthy eyes n (%)	Diabetic eyes n (%)
N-N SCI — CL	61 (78.2)	106 (54.1)
N-AN SCI - CL	8 (10.3)	34 (17.3)
AN-N SCI - CL	2 (2.6)	8 (4.1)
AN-AN SCI - CL	4 (5.1)	48 (24.5)
AN- Imp SCI - CL	1 (1.3)	-
N- Imp SCI - CL	2 (2.6)	-
Total eyes (n)	78	196

Table 4 — Main study - choroidal morphologic features by group.

Legend: N — normal; AN — abnormal; SCI — sclero-choroid interface; CL — choroidal layers; Imp — impossible to evaluate.

About 78% of the healthy ones had all choroidal morphological features classified as normal. When analyzed individually the greater cause of some abnormalities was due to vascular layer abnormalities (12 eyes — 15.4%) and we observed that it was always due to some irregularities in the great vessels layer, being the choriocapillaris/Sattler's layer always preserved. The irregularity of the SCI was a consequence of localized thinning of the great vessels layer. The 3 cases where it was impossible to classify CL were due to the extreme thinness of the choroid in the oldest patients (all 79 years old). Examples are shown in figures 9 to 11 below.

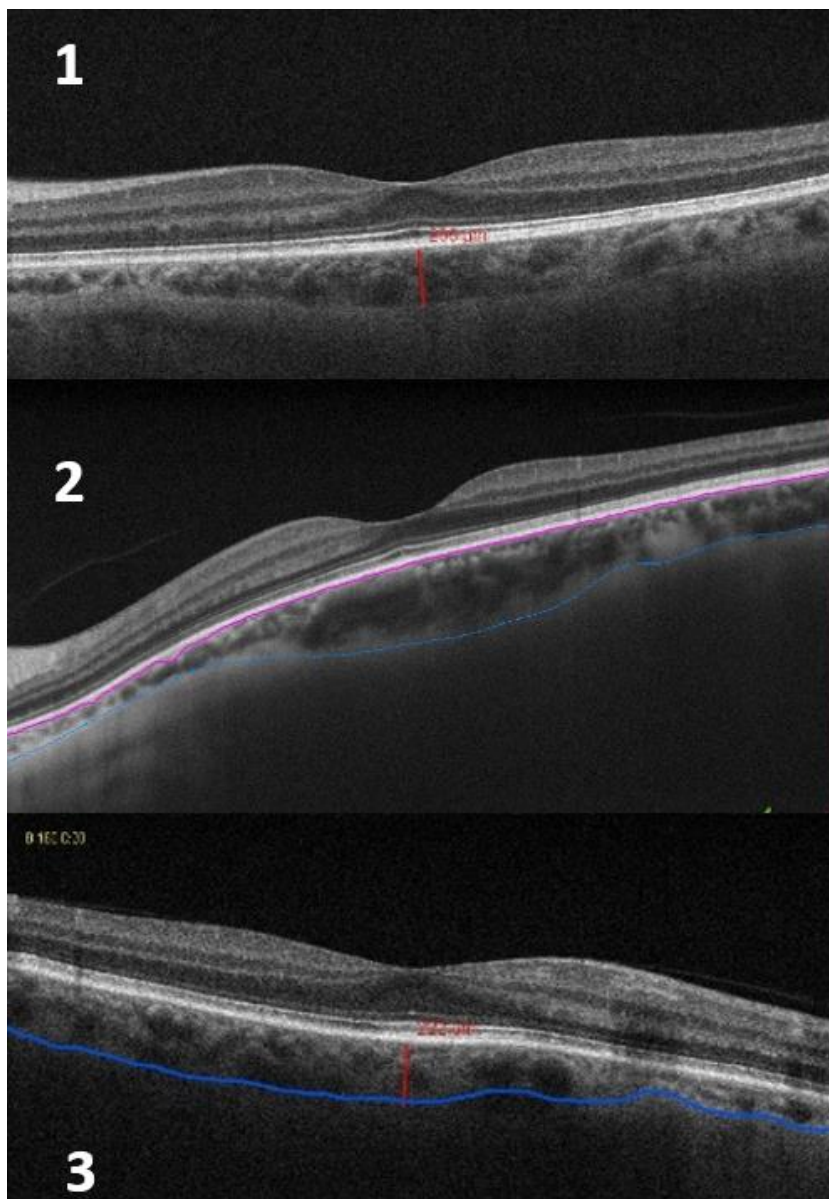


Figure 9 — Choroidal morphologic changes in Control.

Three examples of irregularity of the SCI due to localized atrophy of the great vessels layer (most frequently nasally located) or loss of great vessels with hyperreflective zone (temporally on the OCT image 2).

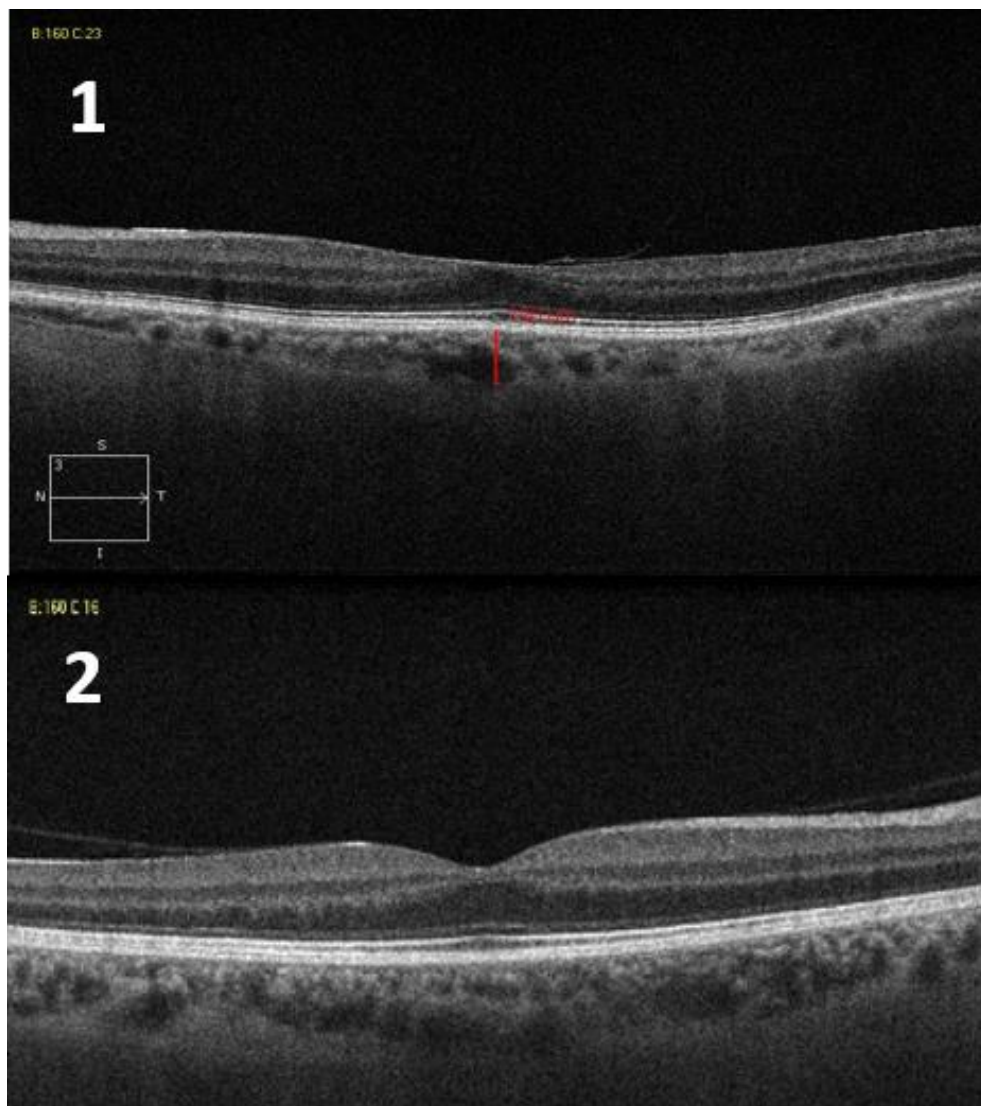


Figure 10 — Choroidal morphologic changes in Control.

Two examples of normal contour of the SCI with abnormal CL due to localized atrophy of the great vessels layer and/or loss of great vessels with hyperreflective zone, but with preservation of the choriocapillaris/Sattler's layer.

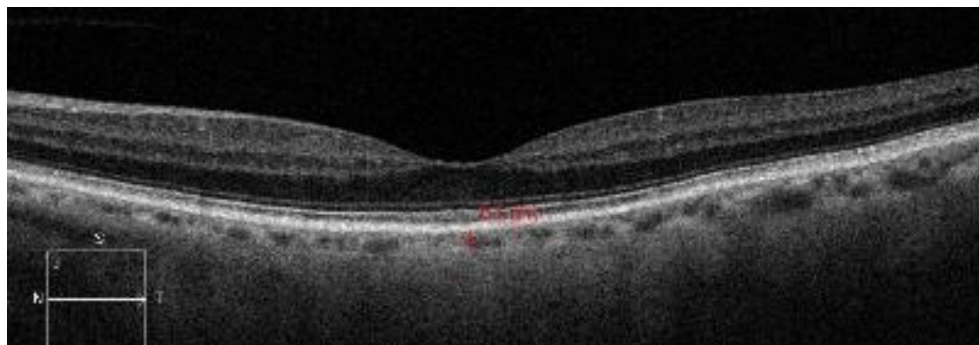


Figure 11 — Choroidal morphologic changes in Control.
Example of a very thin choroid where it is impossible to differentiate the layers boundaries.

In the diabetic group, 54.1% of the eyes had no choroidal morphologic abnormalities. Most eyes with choroidal abnormalities had vascular changes (41.8%) compared with those with just sclero-choroidal irregularities (4.1%). The sclero-choroidal border was always correlated with or due to changes in the normal distribution of the great vessels (enlargement, atrophy or loss), except in one case where we found an anatomical variation with a triangular shape sub-foveal (figure16).

SCI-CL	NDR	MildNPDR	ModNPDR	Sev/PDR	Maculopathy
N-N (n= 106)	71.7%	19.8%	8.5%	0	18.5% (5)
N-NA (n= 34)	50%	29.4%	20.6%	0	29.6% (8)
AN-N (n=8)	75%	25%	0	0	0
AN-NA (n=48)	56.3%	16.7%	18.7%	8.3%	51.9% (14)

Table 5 — Correlation of choroidal morphologic findings with the retinopathy grade.
Legend: SCI — sclero-choroidal interface; CL- choroidal layers; N- normal; AN — abnormal; NDR — no diabetic retinopathy; MildNPDR- mild non-proliferative diabetic retinopathy; ModNPDR- moderate non-proliferative diabetic retinopathy Sev/PDR- severe or proliferative diabetic retinopathy.

When correlating choroidal morphological findings with the retinopathy grade and the presence of maculopathy, we found that most of the diabetic eyes with no choroidal abnormalities had no DR or only initial stages of DR (table 5). Five of these

had extra-foveal focal macular edema, and only in those focal locations choroidal changes were evident (figure 22). Choroidal vascular abnormalities were more prominent in the presence of macular edema or diabetic retinopathy. More advanced choroidal morphological changes with both SCI and Vascular layers affected were associated to more advanced retinal disease.

From individual OCT image observation, we found that:

— Changes in the great vessel layers are the major responsible for the irregular sclero-choroidal border, usually due to focal atrophy or thinning, loss of vessels with hyperreflective spaces occupying the vessels space or hypertrophy.

— In the absence of evident retinal disease and changes in the choriocapillaris/Sattler's layer, great vessels layer abnormalities are usually caused by focal loss or atrophy (more frequently located nasally to the fovea), or loss of even distribution.

— Changes on the choriocapillaris/Sattler's layer such as focal atrophy/loss with the approach of the great vessels to the Bruch's membrane, hypertrophy associated with focal thinning or loss of subjacent great vessels, are correlated with changes in the retinal anatomy above. It becomes more evident in the presence of macular edema especially if the photoreceptor layer is affected.

— With maculopathy, we can find focal thinning of the choriocapillaris/Sattler's layer below the affected retina (ex- initial Cystoid macular edema with mild lesion of the retinal layers) with prominent choroidal great vessels, or more frequently associated

to the presence of hard exudates, disorganization of retinal layers, lesion/atrophy of photoreceptors, we can find a focal enlargement of the choriocapillaris/Sattler's layer below the affected retina with thinning or loss of the great vessels layer.

— Independent of the retinal stage, if there is a severe choroidal thinning, it becomes difficult to analyze and classify choroidal morphological changes.

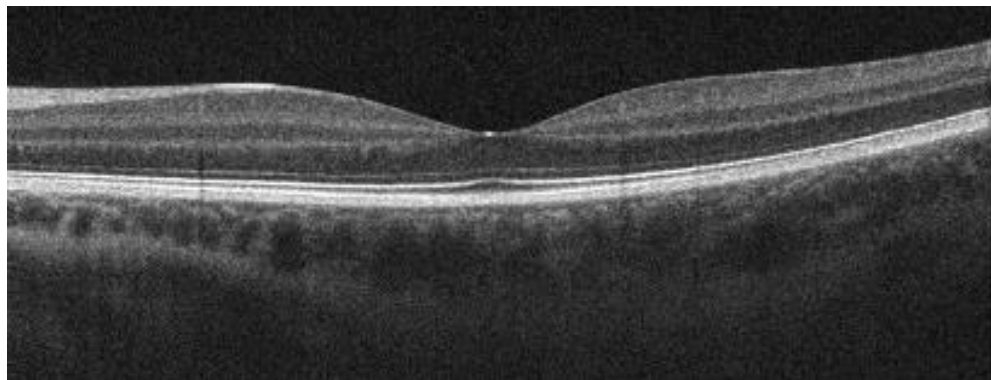


Figure 12 — Choroidal morphologic changes in a Diabetic with no retinopathy. An NDR eye with integrity of the choriocapillaris/Sattler's layer but with a nasal thinning of the great vessels leading to a nasal thinning of choroidal thickness and irregular SCI.

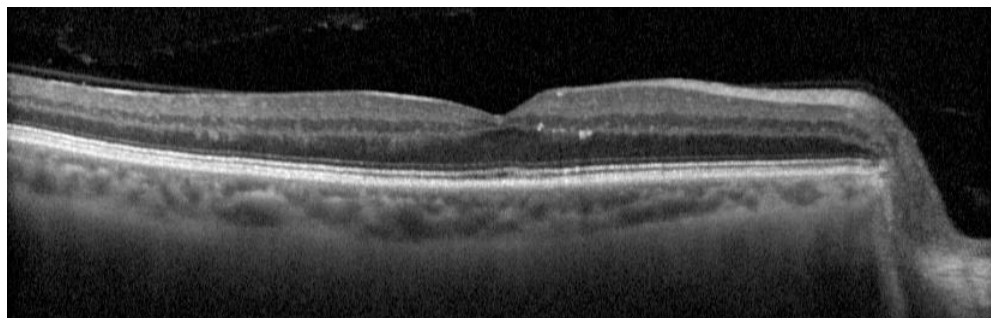


Figure 13 — Choroidal morphologic changes in a Mild non-proliferative retinopathy. Mild NPDR eye with small retinal lesions foveal and nasal to fovea with subjacent loss of great vessels and hypertrophy of the choriocapillaris/Sattler's layer, and temporally to the fovea some irregularities of the retinal outer plexiform layer with subjacent slight thinning of the choriocapillaris/Sattler's layer with an enlargement of the great vessel.

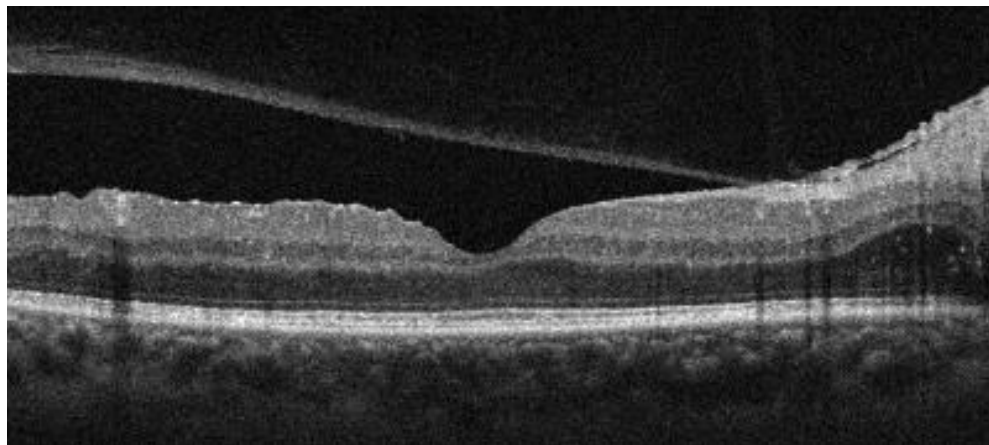


Figure 14 — Proliferative diabetic retinopathy with normal choroidal morphology. PDR where the most affected retina is in the internal layers with integrity of the outer retina. Note the regular choroid with no morphologic changes.

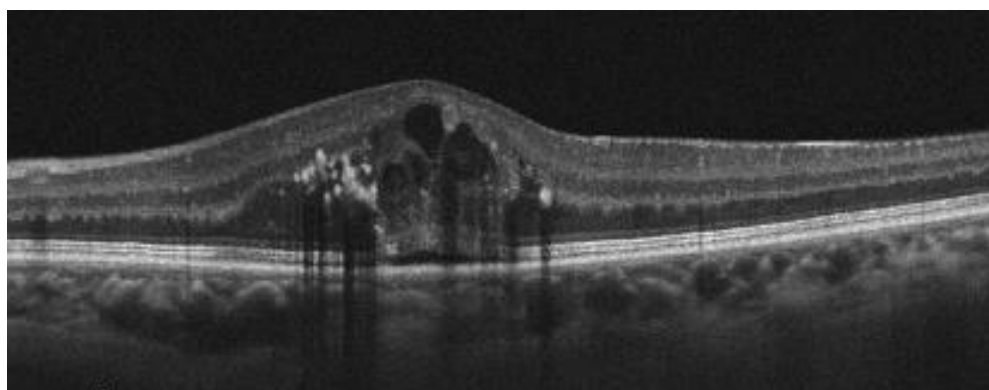


Figure 15 — Choroidal morphologic changes in Macular edema. A Macular edema with slight neurosensorial detachment (NSD) and some chronicity signs. Note the lack of great vessels below the NSD and nasally below the hyperreflective lesions in the retina a slight atrophy of the choriocapillaris and great vessels enlargement.

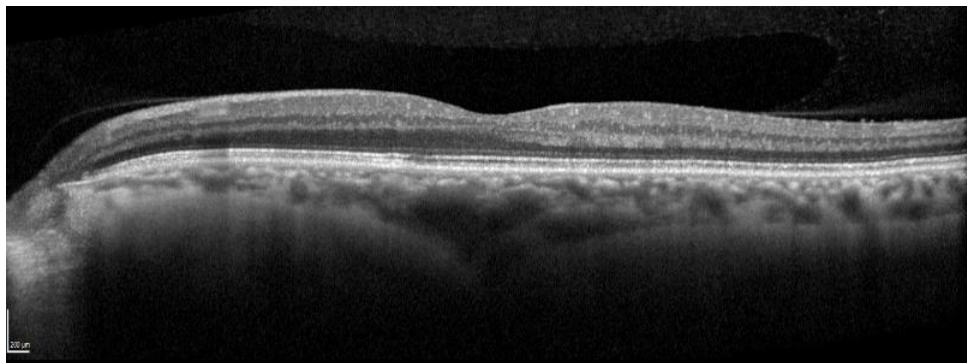


Figure 16 — Variation of normal choroidal vessels morphology.
The case of the anatomical variation with a triangular shape of the SCI, probably corresponding to a posterior ciliary artery choroidal penetration.

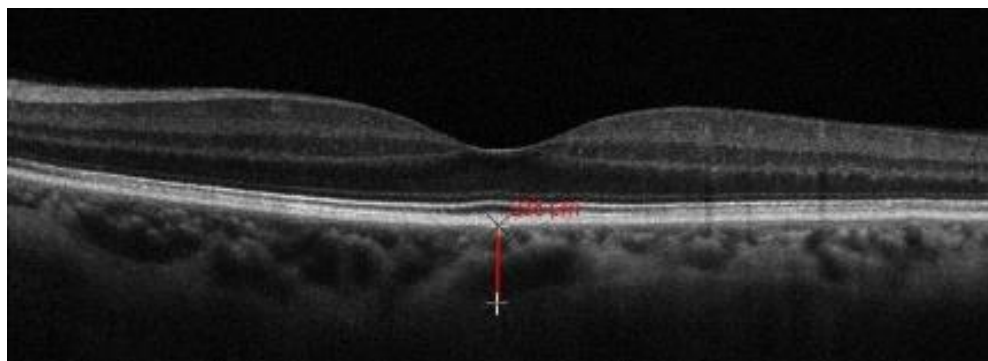


Figure 17 — Choroidal morphologic changes in a Mild non-proliferative retinopathy.
Mild NPDR with temporal macular Microaneurysms and small hemorrhages on funduscopy, and the OCT image showed an irregular SCI with loss of the inverted dome shape due to a temporal thinning related to loss/atrophy of temporal great vessels.

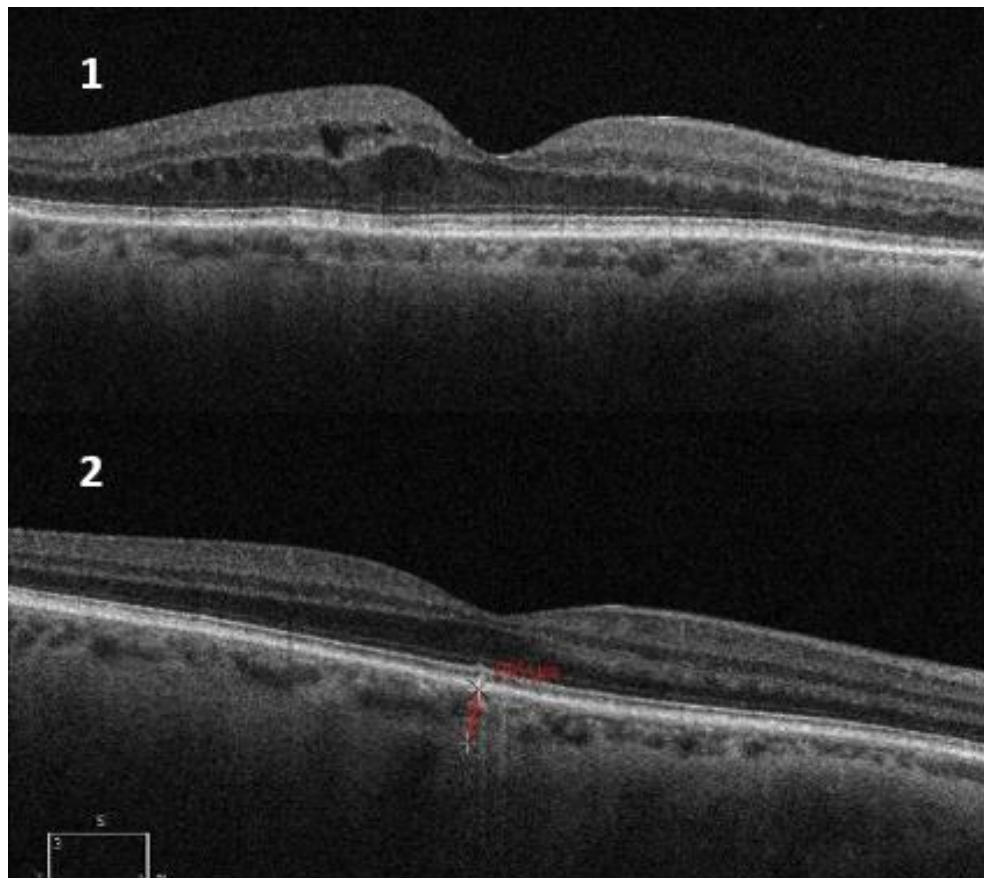


Figure 18 — Choroidal thinning with age.
Two examples of older patients with very thin choroid where morphological classification is difficult.

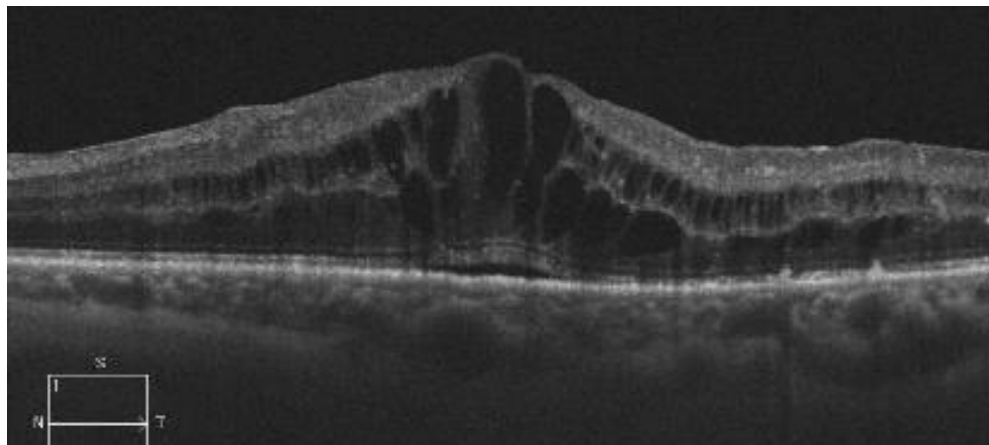


Figure 19 — Choroidal morphologic changes in Macular edema.

An exuberant cystoid macular edema with greater cysts centrally, with a small NSD, slight inner retinal layers edema, and temporally to the fovea focal zones of atrophy of the photoreceptors layer. Under the nasal retina where the outer retina (from the outer nuclear layer to the EPR) has no relevant changes, the choroid is thinner with lack of great vessels and hypertrophy of the choriocapillaris/Sattler's layer. Under the NSD there is an enlargement of the great vessels. Under the focal zones temporally with atrophy of the photoreceptors there is a focal atrophy of the choriocapillaris/Sattler's layer immediately below with invasion of a great vessel.

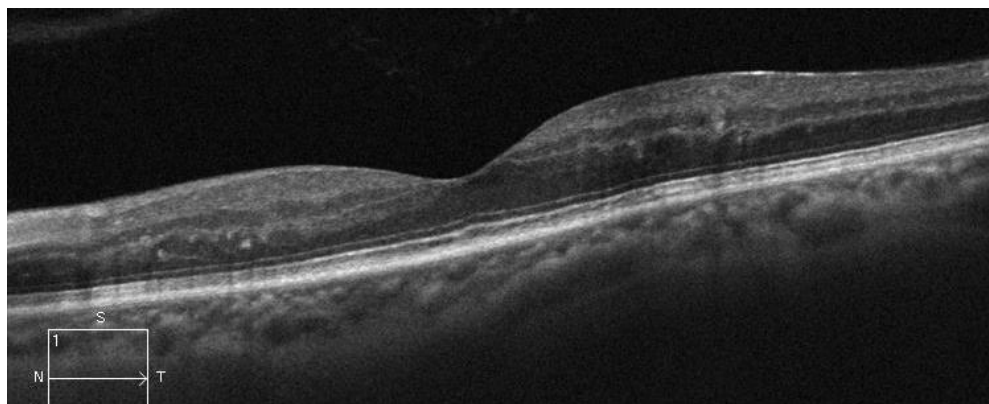


Figure 20 — Focal retinal and subjacent choroidal morphologic changes.

Focal retinal DR changes with corresponding focal thinning of the choroid right below associated with loss/atrophy of great vessels.

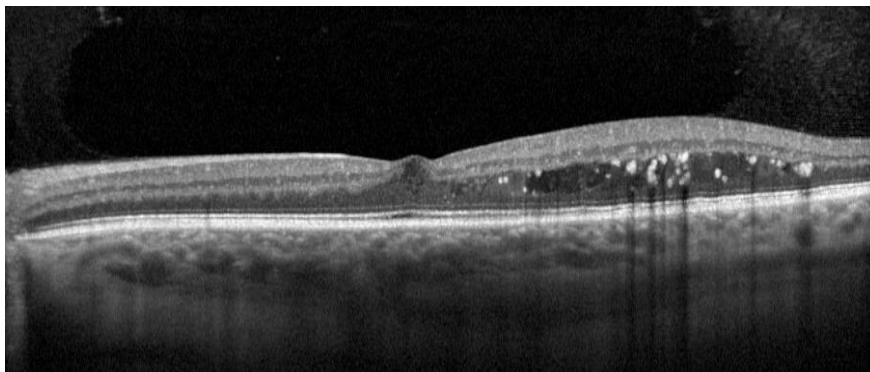


Figure 21 — Focal retinal and subadjacent choroidal morphologic changes.

A temporal macular edema with some exudates and cysts. Below the more fluidic cysts (hyporreflective content) no relevant choroidal morphologic features are noted, but below the more chronic/ organized retinal lesions (exudates and cysts with lightly hyperreflective content) there is a lack of great vessels and thickening of the choriocapillaris/Sattler's layer.

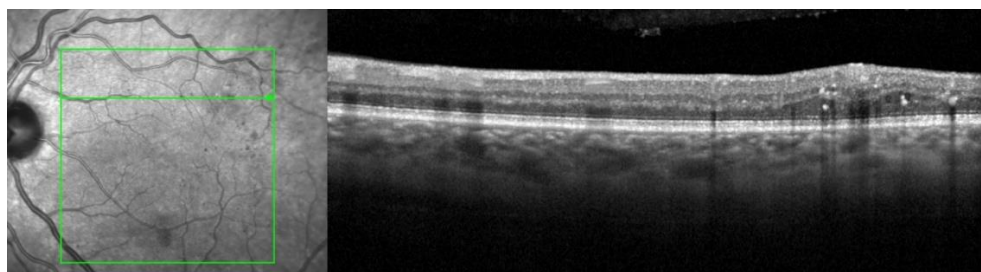


Figure 22 — Focal retinal and subadjacent choroidal morphologic changes.

An example of focal extra-foveal retinal thickening (sparing fovea) where in the same scan we can see the choroid below the retinal focal thickening with the lack of great vessels replaced by hyperreflective space, comparing to the choroid beside (nasal) with some great vessels visible.

We looked for progression changes on diabetic eyes. Eighty-five eyes were analyzed looking for CT increase or decrease from baseline to the second visit. The CT change was correlated with the RT changes and morphological findings.

CT	RT	RT	RT
From BL to V2	no change	increase	decrease
Increase	67.7%	19.4%	12.9%
Decrease	50%	15.4%	36.6%
No change	81%	9.5%	9.5%

Table 6 — Correlation of choroidal thickness changes with retinal thickness progression

RT	CT	CT	CT
From BL to V2	no change	increase	decrease
Increase	21.4%	43.8%	34.8%
Decrease	16.9%	21.1%	62%
No change	33.3%	41.2%	25.5%

Table 7 — Correlation of retinal thickness changes with choroidal thickness progression.

As can be seen in table 6, more than half of the eyes having a change in choroidal thickness from baseline to visit 2 had no retinal thickness changes. But one third of the eyes with choroidal thickness decrease had also a retinal thickness decrease. However, when inverting the analysis (table 7), we found that more than half of the eyes with decreased Retinal thickness had also a decrease in CT, while the distribution was more equitable when a RT increase, or no change was found.

Just a few eyes had moderate thickness changes and even fewer had huge thickness changes. No pattern stands out from these results.

In figures 23 to 33 below, we show some examples of progression of retinal disease and/or choroidal disease.

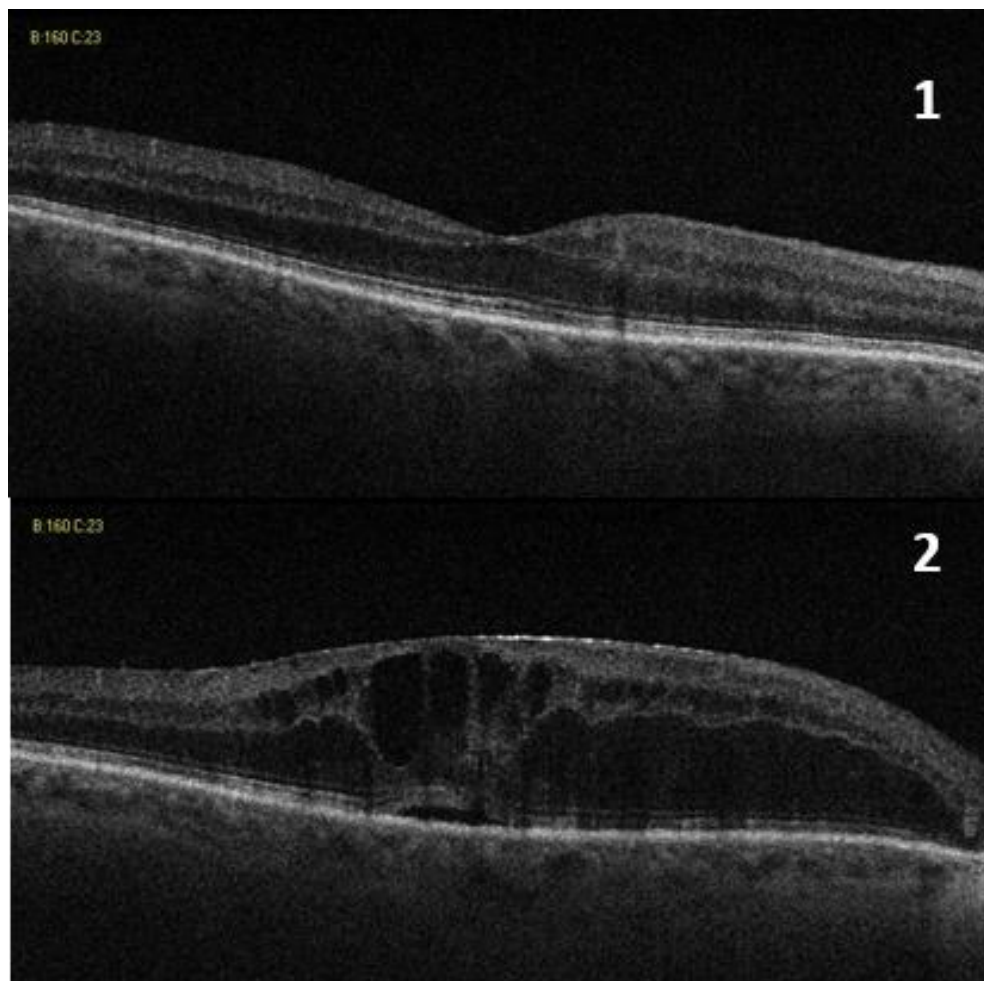


Figure 23 — Example in Macular edema progression.

Image 1 — baseline visit; image 2 - visit 2 (about 1 year later). There was a mild CT increase ($<30 \mu$) and a severe RT increase ($+256 \mu$). Beside the thin choroid that limits the morphologic evaluation we can observe on V2 less vessels with larger caliber, particularly under the central zone of the macular edema.

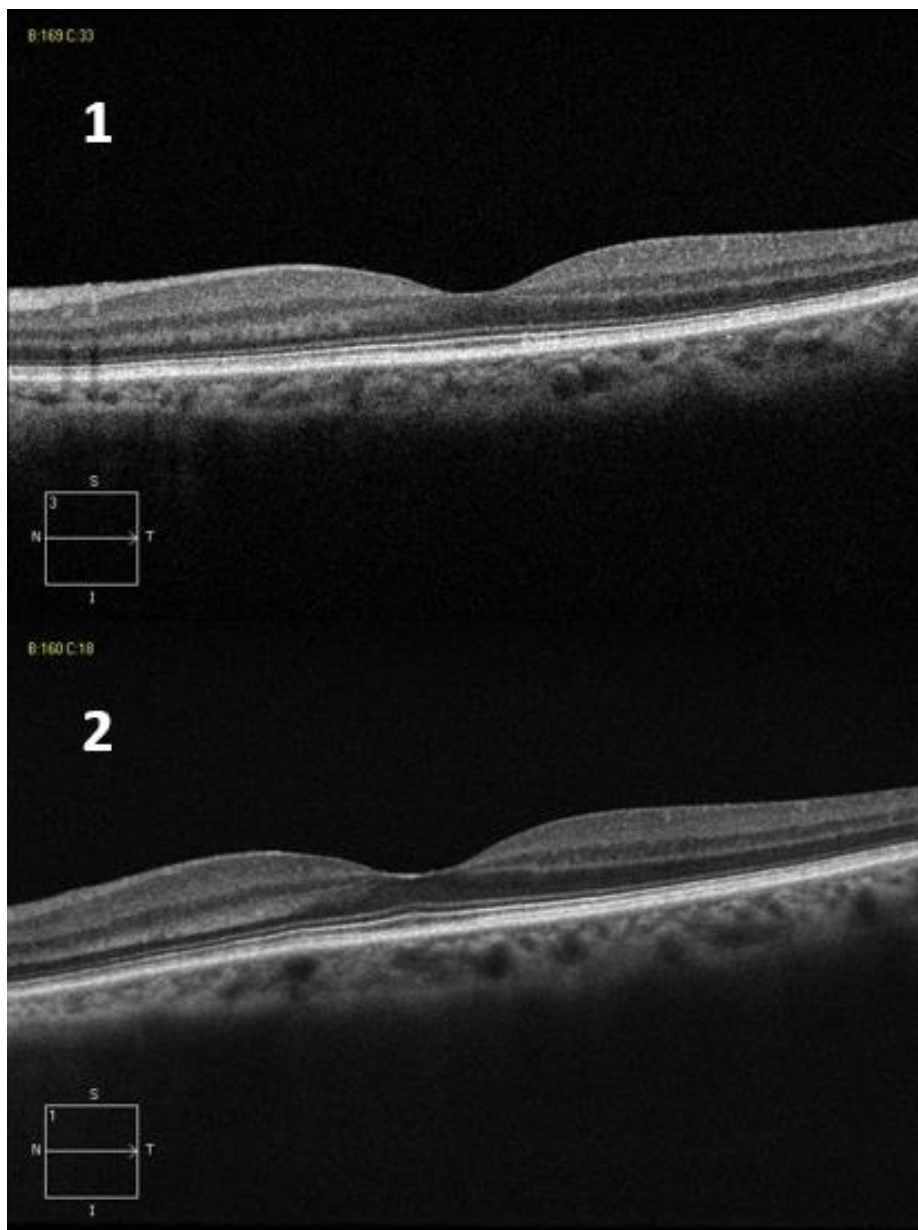


Figure 24 — Example of CT increase with no retinal changes.
From baseline (image 1) to V2 (image 2) there was slight increase in CT with no changes in RT. We can observe that there is a slight enlargement in great vessels that can explain the increase in CT.

CHOROIDAL THICKNESS AND MORPHOLOGY ANALYSED BY OPTICAL COHERENCE TOMOGRAPHY AS A METHOD TO APPROACH DIABETIC OCULAR DISEASE PROGNOSIS AND PROGRESSION

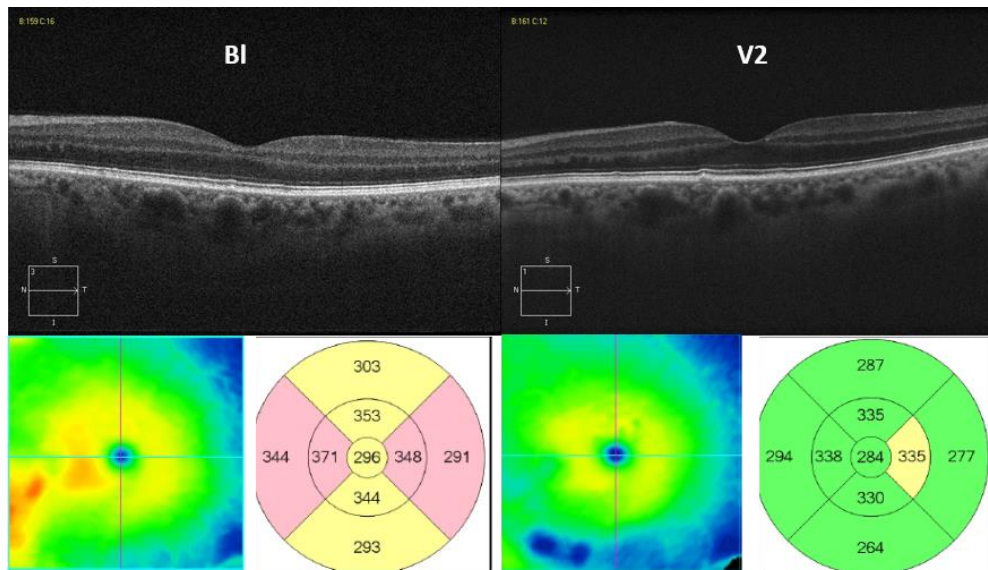


Figure 25 — Choroidal morphologic changes in Retinal improved progression. From baseline (left) to V2 (right) there was a moderate increase in CT (+ 42 μ) and focal decrease in RT (Retinal thickness maps below the line scan images). We can observe on BL two focal zones where there is a hypertrophy of the choriocapillaris/Staller's layer (temporal and nasal of the center) that on the nasal one corresponds to some irregularities of retinal layers (Outer plexiform). On V2 there is a recovery with great vessels on the temporal focal zone, but not on the nasal zone where persists the retinal irregularities.

CHOROIDAL THICKNESS AND MORPHOLOGY ANALYSED BY OPTICAL COHERENCE TOMOGRAPHY AS A METHOD TO APPROACH DIABETIC OCULAR DISEASE PROGNOSIS AND PROGRESSION

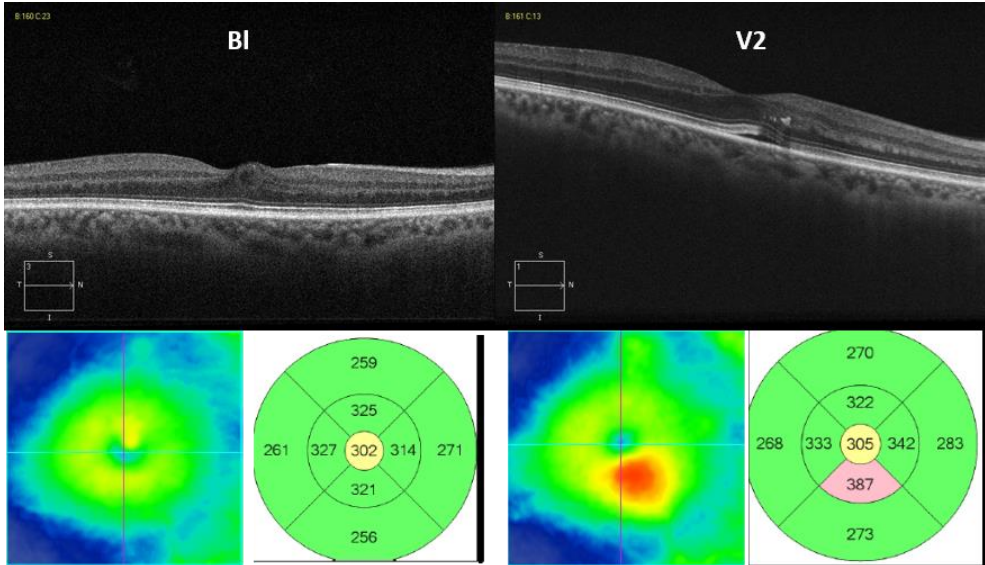


Figure 26 — Choroidal morphologic changes in Retinal worsening progression. From baseline (left) to V2 (right) there was a moderate focal increase in RT (Retinal thickness maps below the line scan images). Choroidal changes are subtle, but we can observe on BL temporal to the central zone a horizontal great vessel that is replaced on V2 by hypertrophic choriocapillaris/Sattler's layer and hyperreflective space. Under the NSD and exudate zone there is an atrophy of the choriocapillaris/Sattler's layer losing the mottled aspect and being plainer hyperreflective.

CHOROIDAL THICKNESS AND MORPHOLOGY ANALYSED BY OPTICAL COHERENCE TOMOGRAPHY AS A METHOD TO APPROACH DIABETIC OCULAR DISEASE PROGNOSIS AND PROGRESSION

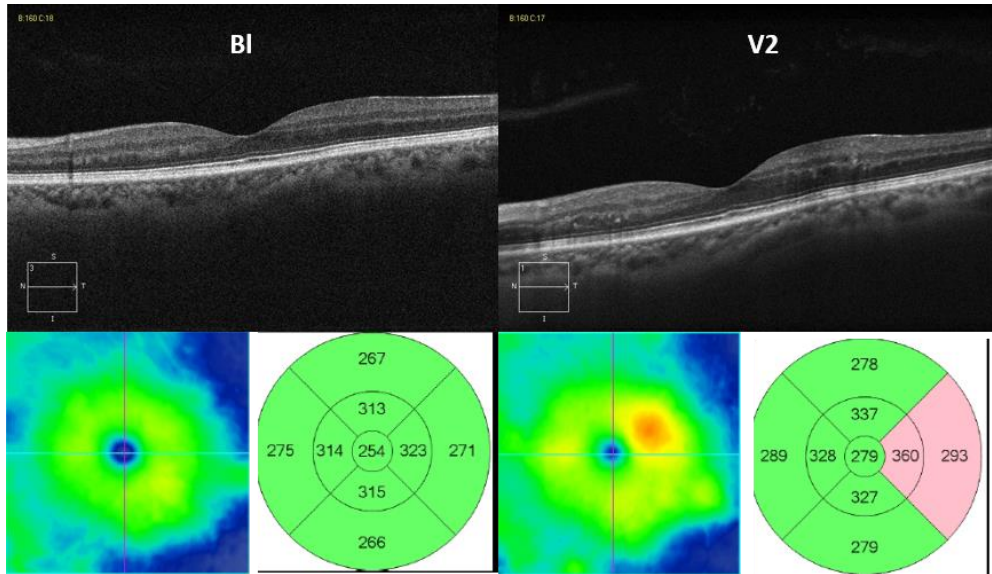


Figure 27 — Choroidal morphologic changes in Retinal worsening progression. On baseline image (left) we can observe the loss of the inverted dome shape of SCI, with scarce great vessels with focal loss (nasally and just temporally to the center). One year later, in V2 (right) there was a moderate focal increase in RT (Retinal thickness maps below the line scan images) and outer retinal layers changes nasally. These changes are above the choroidal changes observed on BL, which persist and are more evident. The CT increase from 243μ to 252μ .

CHOROIDAL THICKNESS AND MORPHOLOGY ANALYSED BY OPTICAL COHERENCE TOMOGRAPHY AS A METHOD TO APPROACH DIABETIC OCULAR DISEASE PROGNOSIS AND PROGRESSION

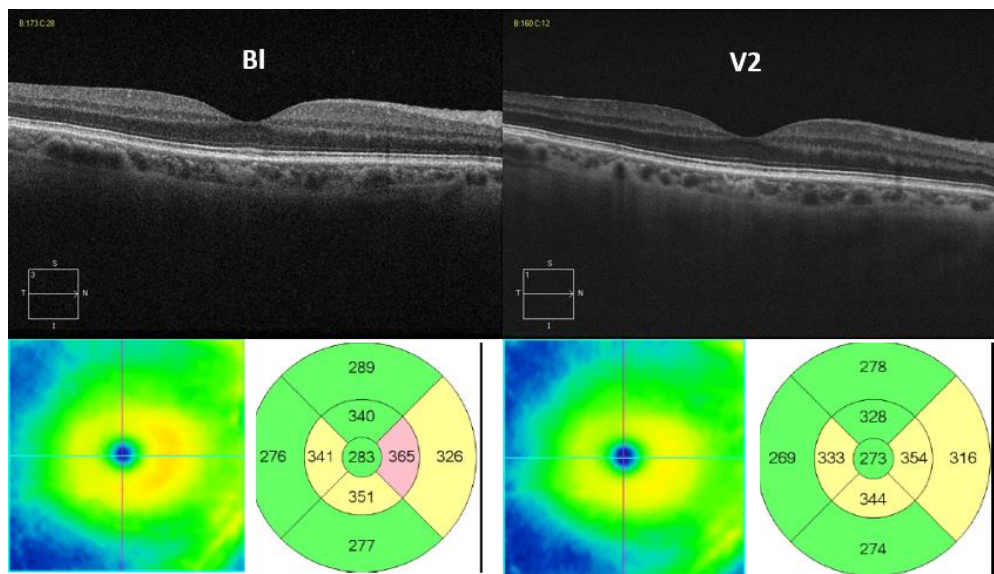


Figure 28 — Progression in a Diabetic with no retinopathy.

A case of an eye with non-visible diabetic retinopathy with 2 years of interval between baseline (left) and V2 (right). There was a mild choroidal thinning with focal loss of great vessels temporally, replaced by a hypertrophic ChS layer and a hyperreflective space.

CHOROIDAL THICKNESS AND MORPHOLOGY ANALYSED BY OPTICAL COHERENCE TOMOGRAPHY AS A METHOD TO APPROACH DIABETIC OCULAR DISEASE PROGNOSIS AND PROGRESSION

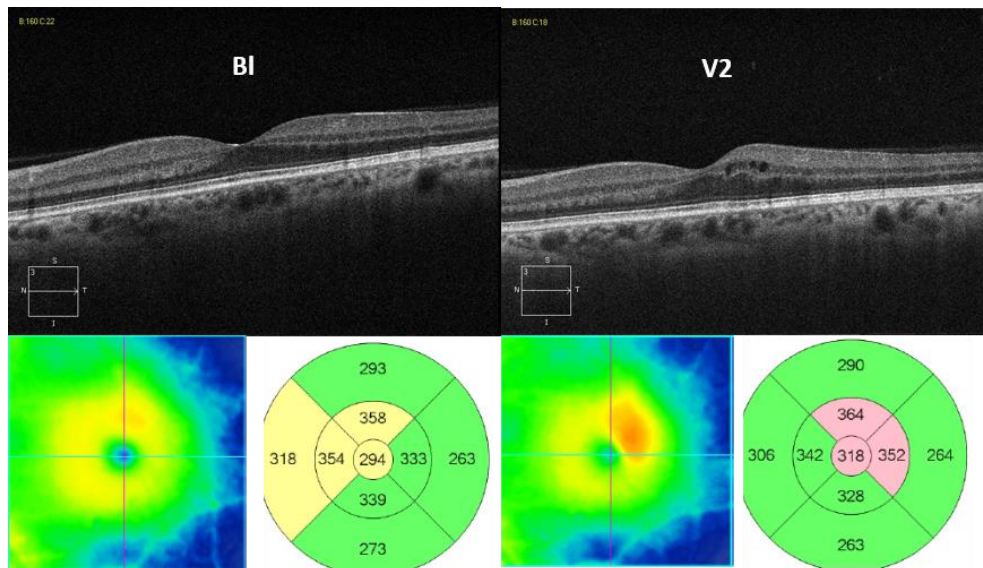


Figure 29 — Choroidal morphologic changes in a macular edema progression. On baseline image (left), of a mild NPDR eye, we can observe the loss of the inverted dome shape of SCI, irregular vessels layers with focal zones of loss of great vessels, atrophy or hypertrophy of ChS, but with no evident retinal changes. Six months later there was a CME with an increase in CT from 219 to 248 μ with a change in choroidal vessels with more larger vessels near the posterior border of Bruch's membrane.

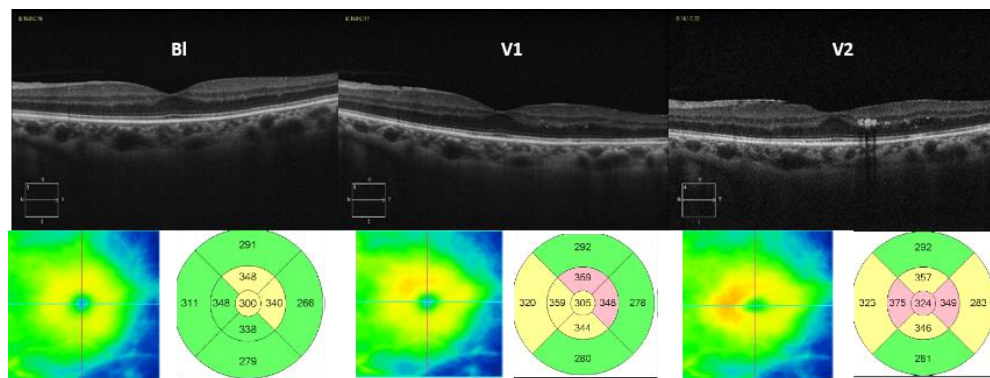


Figure 30 — Choroidal morphologic changes in retinopathy grade progression. An evolution with a 6-months interval between the visits. DR evolved from NDR to mild NPDR and moderate NPDR (from left to right). The retinal maps below the OCT line images show the RT progression. In the line scans, we can observe on BL focal zones with hypertrophy of the ChS and loss of great vessels, and progression of retinal diabetic changes occur above those focal choroidal zones.

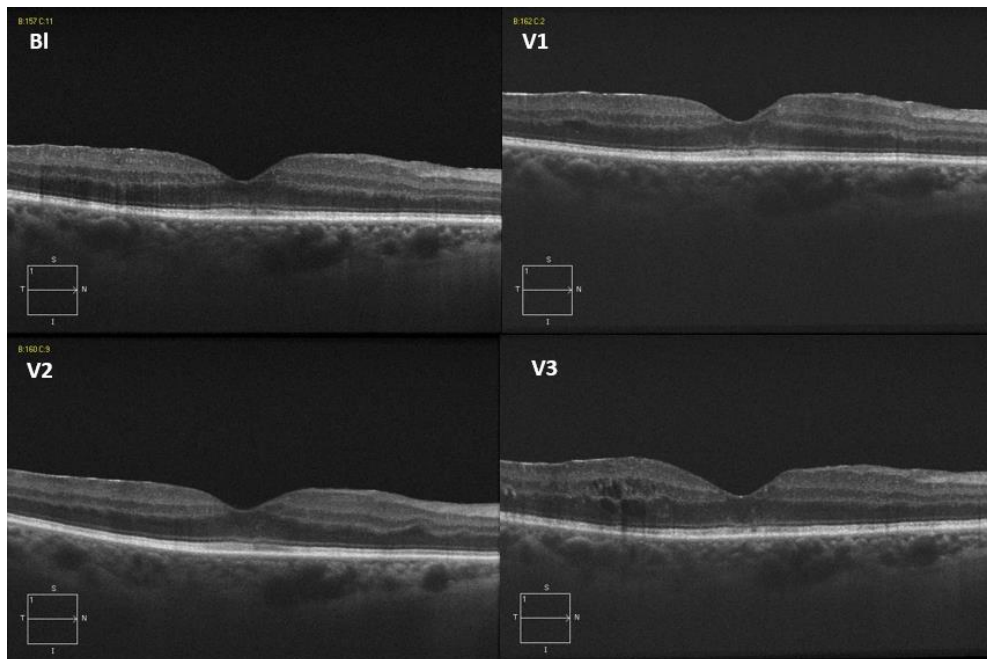


Figure 31 — Choroidal morphologic changes in a macular edema progression.

Evolution during one year of an eye with mild to moderate NPDR evolving to ME. CT was from the first to the last visit of 344μ , 324μ , 326μ and 325μ . The retinal changes are a progression to temporal CME, and some irregularities on nasal retinal layers that regress on the latest visits. Choroidal vascular changes are a focal increase of the ChS both below nasal and temporal changes zones, but while nasally it remains with the regression of retinal changes, temporally with the progression to CME the great vessels enlarge and approach to the Bruch's side.

We evaluated some eyes that had been dropped out from the natural course study because they had been directed to treatment of macular edema. The purpose was to observe what changes occur in the choroid after resolution or recovery of the ME. Below are the examples.

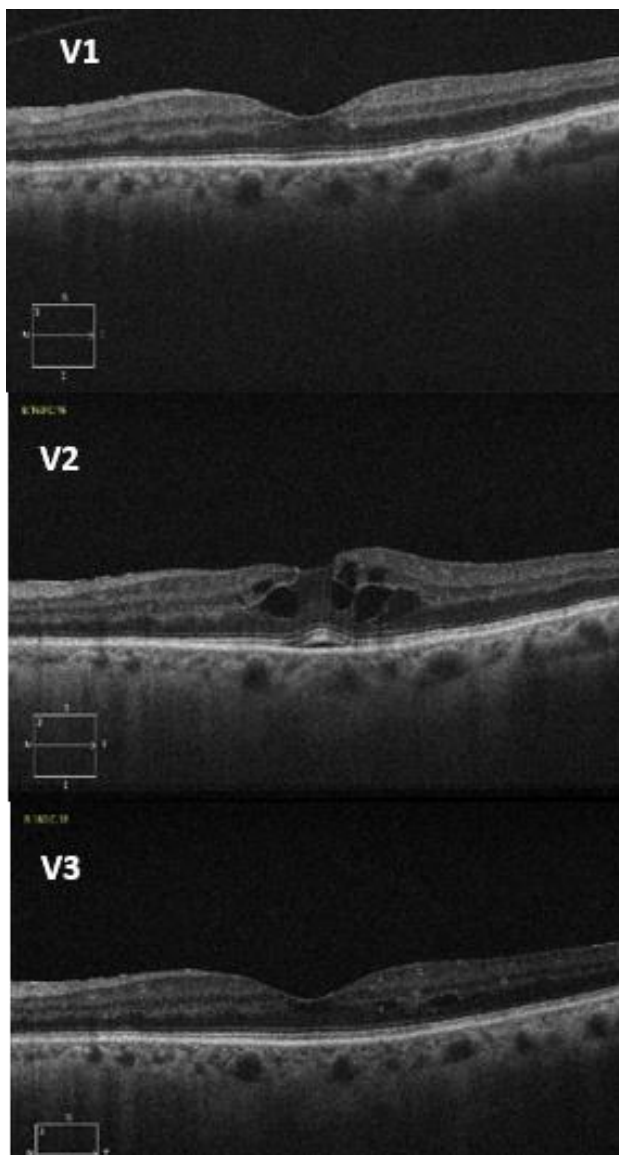


Figure 32 — Choroidal morphologic changes after macular edema resolution.

An eye that evolved to CME with mild NSD that was resolved with intravitreal anti-VEGF. On V1 there is a thin choroid with 3 central great vessels pushing up to the Bruch's the ChS, corresponding to the zone below of where the CME appeared (affected retina). With the progression to V3 the changes that we can observe are a moderate decrease in CT (245μ - 240μ - 189μ) which we can correlate with the decrease in great vessels caliber.

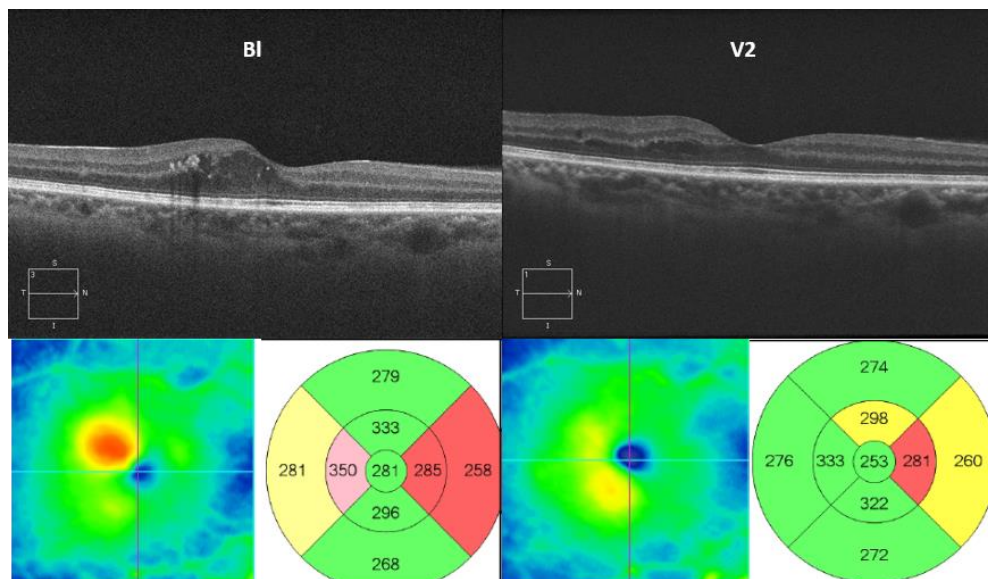


Figure 33 — Choroidal morphologic changes after macular edema resolution. Baseline with ME and two years after ME treatment. There was an almost complete regression of ME with residual cysts and irregular layers. The initial choroid with loss of great vessels under the CME, recovered some great vessels, but thickness decreased from 289 μ to 222 μ . Note that there is a slight retinal thinning temporally although no layers/morphology changes observed, with a corresponding enlargement of a choroidal great vessel pushing ChS to the Bruch's border.

4.2.2. ANCILARY MORPHOLOGICAL STUDY

We evaluated automated retinal and choroidal thickness maps acquired with the Swept-source DRI OCT-1 Triton to correlate localized retinal changes with superimposed choroidal changes (unpublished data).

The results are shown in the figures below.

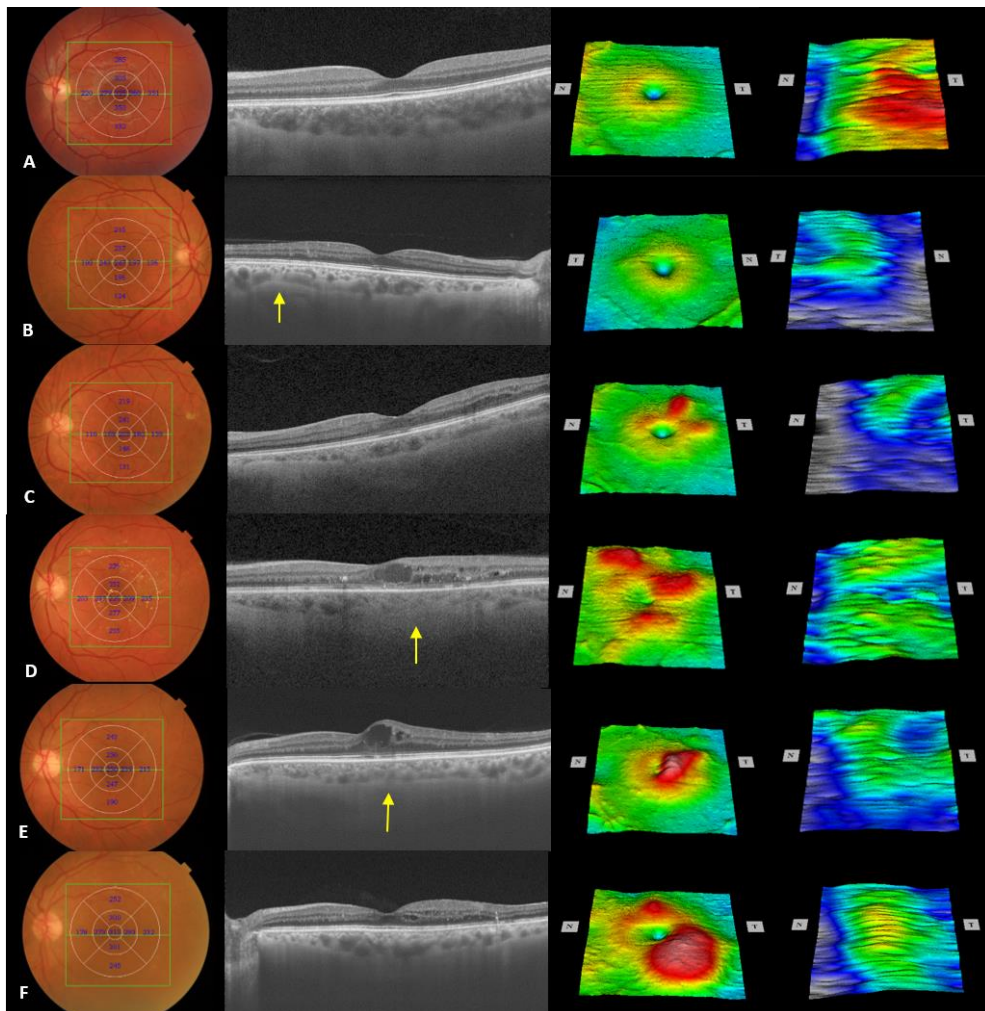


Figure 34 — Choroidal thickness maps in healthy and different retinopathy stages. 1st column — fundus photography. 2nd column — central line OCT scan. 3rd column — retinal thickness map. 4th column — choroidal thickness map. A — healthy subject. B to F — diabetic patients in different stages. Yellow arrows — abnormalities of the choroidal vessels. Detailed description in the text.

Six eyes were analyzed using the SS-OCT retinal and choroidal automated thickness maps. One healthy and five with different types of diabetic retinopathy.

Case A — A healthy 21-year-old (y.o.) man.

On the line scan we can observe the normal morphology as described previously (figure 4) with the “inverted dome shape” sclero-choroidal border, integrity and parallelism of the choriocapillaris/Sattler's layer and uniformity of the great vessels layer. The retinal thickness map is normal according to the well-described features, with the foveal depression, the slightly thickest circle surrounding the fovea with a progressive thinning to the periphery. The choroidal thickness map with thickest zone centrally, superiorly, temporally and inferior to the fovea in a continuous or uniform distribution.

Cases B and C — Right and left eye of a 63 y.o. male diabetic subject with mild non-proliferative diabetic retinopathy.

On the right eye (B), with microaneurysm only mostly located temporally and superiorly in the macula, the retinal thickness map is normal, but the choroidal thickness map shows a decreased thickness primarily temporal and inferior comparing to the healthy case. On the line scan there is a focal thinning of the choroid (yellow arrow) corresponding to a zone with fewer great vessels and minor abnormalities of the retina above. On the left eye (C), microaneurysms are throughout the macula, with a small exudate temporal in the macula. The line scan shows small cysts temporal to the fovea and general decreased thickness of the choroid with atrophy of both group of vascular layers. The retinal map evidences focal increased thickness superior to the fovea. The choroidal thickness map shows a slightly higher decrease in thickness compared with the right eye, but the location

with higher thickness corresponds to the retina above with higher thickness.

Case D — A 51 y.o. diabetic male subject, with moderate diabetic retinopathy.

Fundus image shows microaneurysms, hemorrhages and little macular exudates. The line scan shows some diabetic lesions in the retina with a cystoid macular edema involving the fovea with some loss of integrity of the central photoreceptor layer, and complete vanishing of the choroidal great vessels below this affected photoreceptor zone (yellow arrow). The retinal thickness map shows focal zones with increased thickness, but the choroidal thickness map, despite being abnormal as compared with the healthy case, does not have a logical thickness distribution correlated with the retinal map. It seems that the thinnest zone corresponds to the retinal zone with more exudates (temporal).

Case E — A 67 y.o. diabetic woman, with mild NPDR and a CME.

The line scan shows a foveal important cyst with almost no apparent lesion of the photoreceptors layer, and integrity of the choriocapillaris/Slater's layer with loss of the inverted dome shape and the subfoveal thickest choroidal point. Retinal map shows the central edema and the choroidal map a general slight thickness decrease.

Case F — A 70 y.o. diabetic man, with mild to moderate NPDR with ME non-involving the fovea.

The foveal line scan shows integrity of the fovea and photoreceptors layers with small cysts and slight disorganization of the layers temporal to the fovea. The choroid

has the normal inverted dome shape, and the choriocapillaris/Slater's layer is almost normal with only a slight increased thickness on the temporal side (below the affected retina). The retinal thickness map shows the ME, and the choroidal map shows the normal thickest point centrally but with a slight decrease in thickness temporally and inferiorly when comparing with the healthy case.

4.2.3. STATISTICAL RESULTS

For the analysis, both eyes were included, if eligible by the inclusion criteria, since the variables to be studied for the principal purpose were specific for each eye and independent of the contralateral eye. Thus, non-ocular variables are presented demographically by patient (age, sex, systolic blood pressure, diastolic blood pressure, HbA1c, duration of Diabetes) while eye variables are presented by eye (best corrected visual acuity, refractive error, ocular pressure, subfoveal choroidal thickness, central foveal retinal thickness, choroidoscleral interface contour, choroidal vascular layers, stage of diabetic retinopathy). In order to facilitate the statistical analysis, choroidal morphologic features were divided in contour (Sclero-choroidal border delineation) and layers (vascular layers — great vessels and ChS layer). Both variables could be normal or abnormal.

Visual acuity was recorded on a 20/20 ETDRS chart. For analysis, the denominator was registered (example: 20/40 VA was recorded as 40). The refractive error was recorded as spherical equivalent.

4.2.3.1 BASELINE

Group 1 — Diabetics

Baseline demographics for generic, systemic and non-retinal or choroidal variables are show in tables 8 and 9.

Variable	n (eye)	Mean	Std. Dev.	Min	Max
Age	196	57.8	12.8	18	81
Gender (F/M)	196	88 (44.9%) / 108 (55.1%)			
VA	196	23.0	9.1	20	100
RE	196	0.1	2.2	-2.5	3.5
SBP	165	140.5	20.0	105	197
DBP	165	76.4	13.6	45	132
OP	174	15.5	3.3	10	27

Table 8 — Demographics of Diabetic group (analysis per eye).

Gender — F- female, M- male; VA — visual acuity; RE — refractive error; SBP — systolic blood pressure(mmHg); DBP — diastolic blood pressure(mmHg); OP- ocular pressure (mmHg).

Variable	N Subjects	Mean	Std. Dev.	Min	Max
Age	78	57.8	12.8	18	81
Gender (F/M) n	78	44 / 56			
SBP	74	141.5	20.2	105	197
DBP	74	76.5	13.5	45	132

Table 9 — Demographics of Diabetic group (analysis per subject).

For group 1, diabetic subjects, data regarding SFCT, CFRT, HbA1c and duration of Diabetes are summarized on table 10 and SFCT mean values for each diabetic retinopathy sub-group are in table 11.

Variable	n	Mean (μ)	\pm SD	Min (μ)	Max (μ)
SFCT	196	273.4	80.9	96.0	495.0
CFRT	196	271.3	45.3	209.0	517.0
HbA1c	183	7.4	1.8	5.1	13.6
Diabetes (years)	196	12.6	8.3	0.5	40.0

Table 10 — Diabetic group — Choroidal and retinal thickness and metabolic status. Legend: SFCT (subfoveal choroidal thickness), CFRT (central foveal choroidal thickness), HbA1c (serum glycosylated hemoglobin) and duration of Diabetes

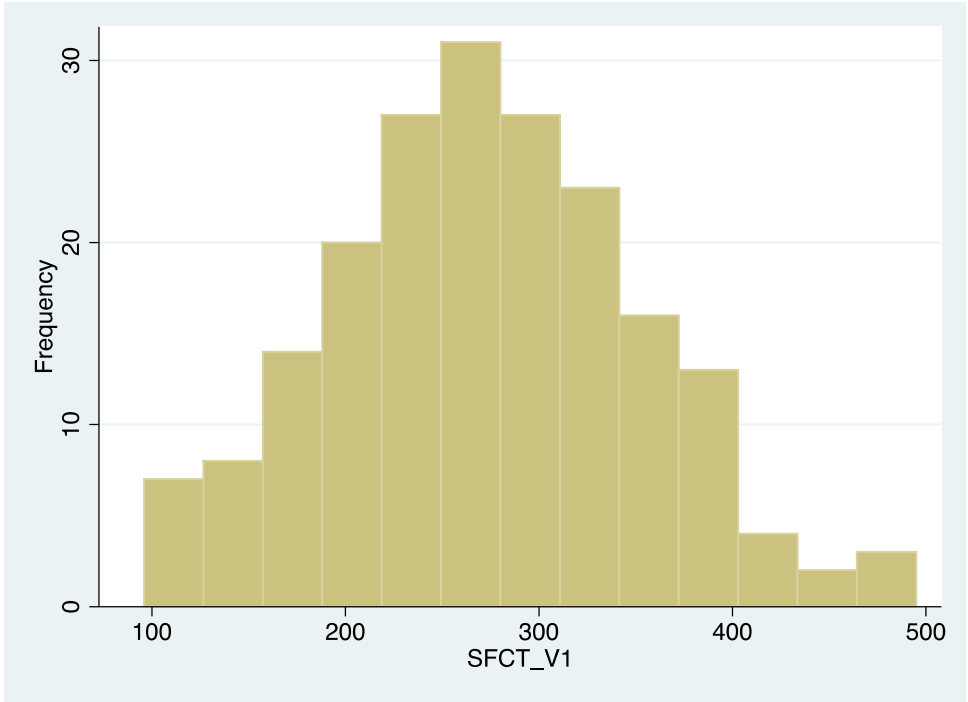
DR stage	n (eyes)	Mean SFCT (μ)	\pm SD	Min	Max
NDR	125	264.32	81.08	96	495
MildNPDR	42	262	65.60	113	391
ModNPDR	25	265.64	85.46	100	423
SevNPDR/PDR	4	336.75	55.57	268	404
Maculopathy	27	262.81	85.10	100	461

Table 11 — Diabetic group — Choroidal thickness for each Diabetic retinopathy (DR) stage.

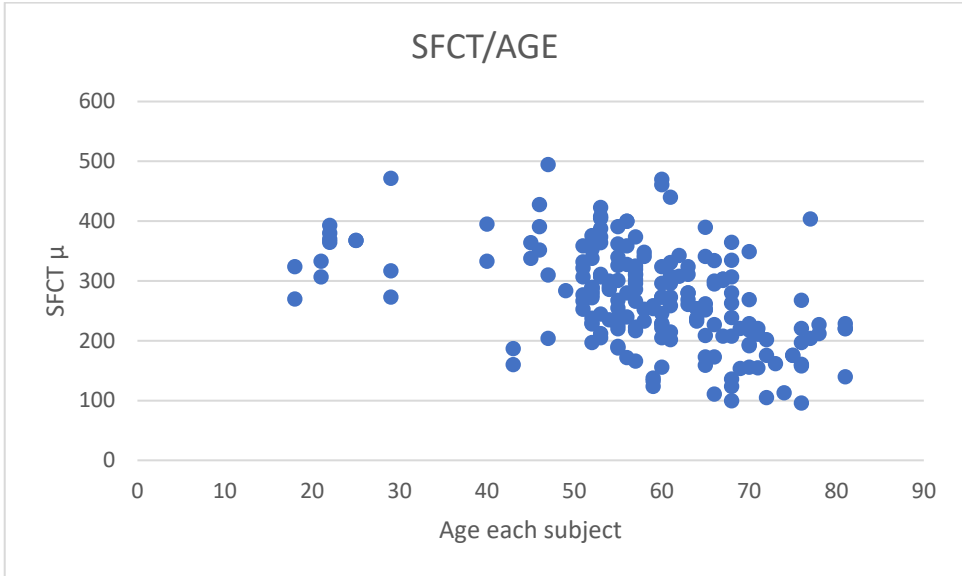
Legend: SFCT — subfoveal choroidal thickness; NPDR — nonproliferative diabetic retinopathy; Mod — moderate; Sev — severe; PDR — proliferative diabetic retinopathy

On thirteen patients, the HbA1c failed to be registered for other reasons (e.g., failure to do the analysis with the family doctor). Patients were in global relatively well controlled for Diabetes and blood pressure. Most eyes had no evident diabetic retinopathy or mild NPDR. Only 27 eyes had macular edema (central or focal extra-foveal).

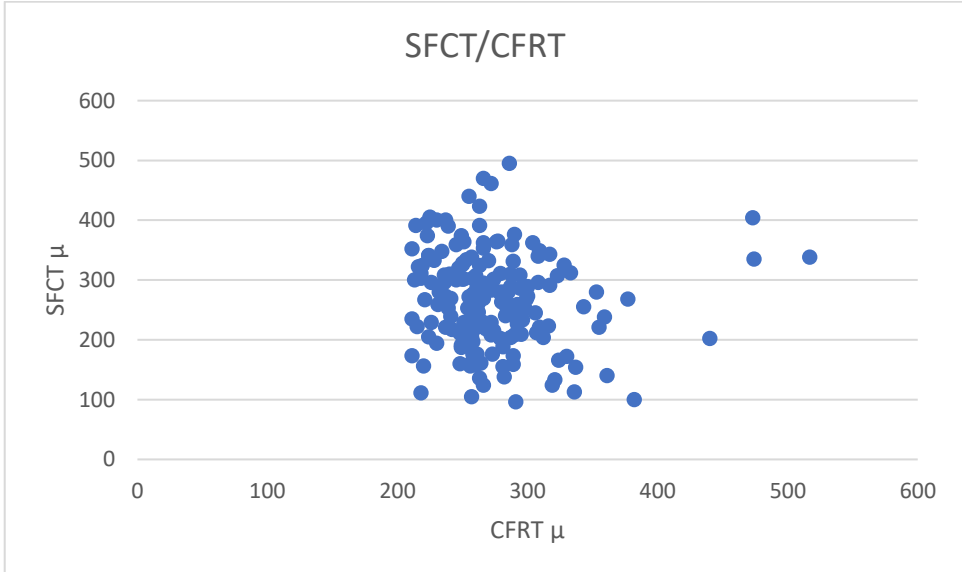
SFCT had a huge range of measurements varying from 96 to 495 μ as shown in graphic 1. When analysing SFCT distribution by age for all eyes we found that there is a great variability and dispersion (graphic 2). When analysis was done regarding the CFRT, we found that, although the majority of CFRT did not vary much, there was a great SFCT variability (graphic 3).



Graphic 1 — Diabetic group — Distribution of SFCT



Graphic 2 — Diabetic group — Distribution/dispersion of SFCT for each included eye by age



Graphic 3 — Diabetic group — Distribution/dispersion of SFCT for each subject by CFRT

Group 2 — Control

Baseline demographics for generic, systemic and non-retinal or choroidal variables are shown in tables 12 and 13.

Variable	n (eyes)	Mean	Std. Dev.	Min	Max
age	78	58.5	14.0	21	85
Gender (F/M)	78	44 (56.4%) / 34 (43.6%)			
VA	78	21.5	4.6	20	40
RE	78	0.7	1.1	-2	3.75
SBP	62	135.3	20.1	102	199
DBP	62	78.4	12.9	52	114
OP	78	14.7	2.9	10	24

Table 12 — Demographics of Control group (analysis per eye).

Legend: Gender — F- female, M- male; VA — visual acuity; RE — refractive error; SBP — systolic blood pressure; DBP — diastolic blood pressure; OP- ocular pressure

Variable	n (subjects)	Mean	Std. Dev.	Min	Max
age	39	58.1	14.0	21	85
Gender (F/M)	39	24 (61.5%) / 15 (38.5%)			
SBP	31	133.6	18.4	102	191
DBP	31	76.9	12.1	52	111

Table 13 — Demographic of Control group (analysis per subject)

There was a failure to register blood pressure for 8 patients. The patients with a visual acuity lower than 20/20 was due to mild cataract not interfering with imaging acquisition and enough quality for analysis.

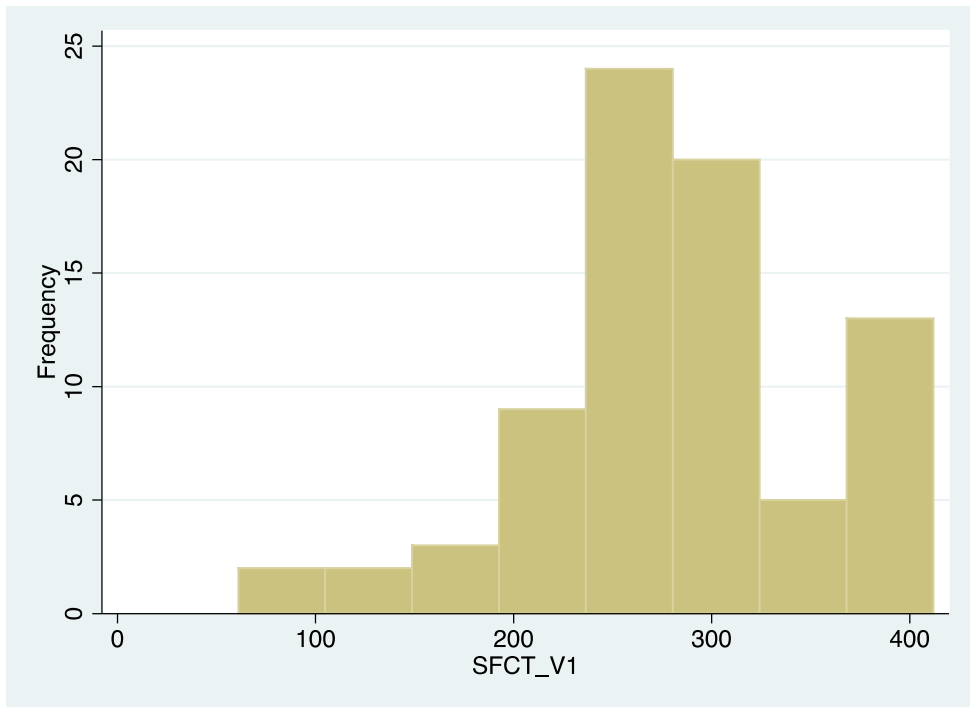
Data regarding SFCT and CFRT is summarized in table 14.

Variable	Obs	Mean	Std. Dev.	Min	Max
SFCT_V1	78	281.8	74.1	61.0	412.0
CFRT_V1	78	258.3	26.7	173	309.0

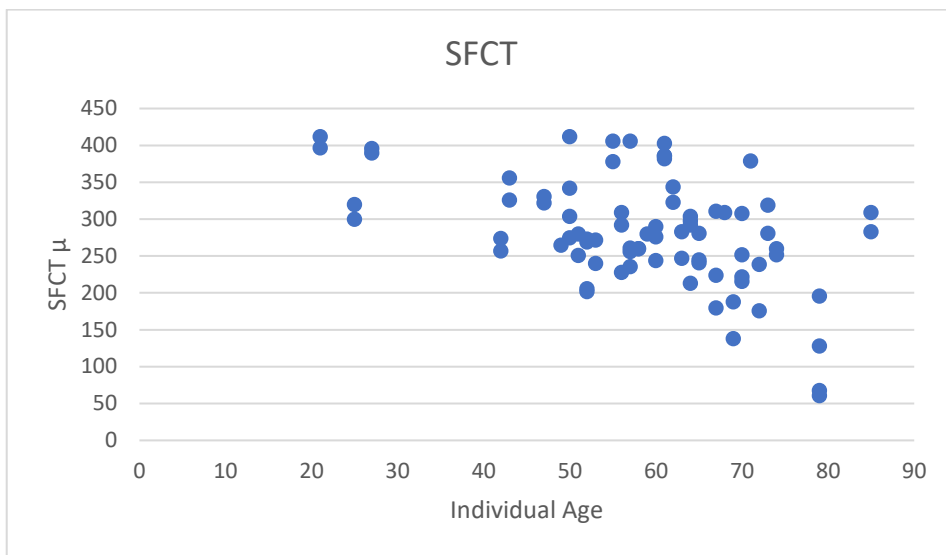
Table 14 — Control group — Choroidal and retinal thickness.

Legend: SFCT - subfoveal choroidal thickness; CFRT - central foveal choroidal thickness.

SFCT had a huge range of measurements varying from 61 to 412 μ with a wide dispersion of values by age (graphics 4 and 5). We can observe that youngest ages had the higher SFCT values and that the lowest SFCT values were related to the oldest ages. Great variability was found primarily in the intermediate ages (40-70).



Graphic 4 — Control group — Distribution of SFCT



Graphic 5 — Control group — Distribution/dispersion of SFCT for each included eye by age

Baseline Analysis

No statistically significant difference was found between OD and OS in both groups (diabetic and healthy) for ocular variables excluding retinal and choroidal features (tables 15 and 16).

Variable	n (eyes)	Mean	Std. Dev.	Min	Max	p (Wilcoxon)
VA — OD	100	22.3	5.2	20	60	0.431
VA — OS	96	23.9	11.9	20	100	
RE — OD	100	0.30	1.24	-3.75	3.25	0.334
RE — OS	96	-0.13	2.9	-2.5	3.5	
OP — OD	88	15.4	3.2	10	24	0.249
OP — OS	86	15.5	3.5	10	27	

Table 15 — Diabetic group — Differences between eyes

There were no statistically significant differences between OD and OS. VA- visual acuity; RE — refractive error; OP — ocular pressure; OD — right eye; OS — left eye

Variable	n (eyes)	Mean	Std. Dev.	Min	Max	p (Wilcoxon)
VA OD	39	21.7	4.6	20	40	0.317
VA – OS	39	21.4	4.8	20	40	
RE – OD	39	0.61	1.08	-2	3.25	0.254
RE – OS	39	0.72	1.18	-1.75	3.75	
OP – OD	39	14.7	2.7	10	21	0.611
OP – OS	39	14.8	3.2	10	24	

Table 16 — Control group — Differences between eyes

There were no statistically significant differences between OD and OS. VA- visual acuity; RE — refractive error; OP — ocular pressure; OD — right eye; OS — left eye

Using the Shapiro-Wilk normality test, no normality was found for the variables in general and by group. Thus, non-parametric test was used to evaluate if there were statistically significant difference between the two groups. Statistically significant difference was found between control and diabetic group for visual acuity (mean \pm SD: 21.5 \pm 4.6 versus 23.3 \pm 9.5: p=0.010), systolic blood pressure (mean \pm SD: 135.3 \pm 20.1 versus 142.3 \pm 19.8: p=0.010), ocular pressure (mean \pm SD: 14.7 \pm 2.9 versus 15.6 \pm 3.3: p=0.018), and refractive error (mean \pm SD: 0.1 \pm 2.2) - table 17.

Variable	P (control/diabetic)	Test	
age	0.612	Mann-Whitney	
Gender	0.092	Fisher Chi-Square	
VA	0.0222	Mann-Whitney	
RE	0.0174	Mann-Whitney	
SBP	0.0461	Mann-Whitney	
DBP	0.2861	Mann-Whitney	
OP	0.0367	Mann-Whitney	

Table 17 — Statistical results comparing the 2 groups for statistical difference

When comparing SFCT and CFRT between controls and diabetic no statistically significant differences were found ($p > 0.05$) — table 18.

Variable	p	Test
SFCT	0.2978	Mann-Whitney
CFRT	0.1631	Mann-Whitney

Table 18 — Comparison of SFCT and CFRT between the two groups.

For group 1 of diabetic subjects there was no significant statistical difference regarding SFCT between the different stages of DR (Kruskal-Wallis; $p=0.3459$) and between the stage with or without ME (Mann-Whitney; $p= 0.5184$) - tables 19 and 20.

	Mean	SD	Min	Max
DR = 0	264.32	81.08	96	495
DR = 1	262	65.60	113	391
DR = 2	265.64	85.46	100	423
DR = 3	336.75	55.57	268	404

Table 19 — SFCT mean values by diabetic retinopathy (DR) stage.

Legend: 0= No DR; 1= mild non-proliferative DR; 2= moderate non-proliferative DR; 3= severe or proliferative DR.

	Mean	Std. Dev.	Min	Max
ME = 0	266.26	77.27	96	495
ME = 1	262.81	85.10	100	461

Table 20 — SFCT mean values by presence of macular edema (ME)

Legend: 0= no ME; 1= with ME.

In order to study the impact in Group 1 of the variables CFRT, contour, layers, HbA1c, duration of Diabetes, SBP, DBP, BP medicated, refractive error, VA, DR stage, age, and OP with the variable SFCT, a linear regression model was performed with the variable SFCT as a dependent variable and the remaining variables as independent variables (table 21).

The model obtained is statistically significant ($p < 0.001$) and explains about 40% of the variance of SFCT ($R^2 = 0.402$).

SFCT	Coef.	Std. Err.	t	P>t	[95% Conf.	Interval]
CFRT	-0,11	0.17	-0.65	0.519	-0.44	0.22
contour	-13.21	13.83	-0.96	0.341	-40.59	14.17
Layers	-28.76	13.32	-2.16	0.033	-55.15	-2.37
HbA1c	-5.32	4.08	-1.3	0.195	-13.41	2.77
Diabetes duration	0.42	0.73	0.57	0.569	-1.03	1.87
SBP	0.01	0.38	0.01	0.989	-0.74	0.76
DBP	0.31	0.54	0.57	0.569	-0.77	1.39
BP med	25.28	15.02	1.68	0.095	-4.46	55.01
RE	-1.02	2.35	-0.43	0.666	-5.67	3.63
VA	0.17	1.29	0.13	0.896	-2.38	2.72
DR stage	19.09	12.15	1.57	0.119	-4.97	43.16
ME	-32.99	27.68	-1.19	0.236	-87.83	21.84
Age	-3.74	0.62	-6.0	0.000	-4.97	-2.51
OP	0.29	1.82	0.16	0.874	-3.32	3.90
_cons	511.26	70.94	7.21	0.000	370.75	651.77

Table 21 — Multivariate analysis with SFCT as the dependent variable — Diabetic group

Legend: Contour — sclero-choroidal border morphology (normal or abnormal); layers — choroidal layers (normal or abnormal); HbA1c — serum glycosylated hemoglobin; SBP — systolic blood pressure; DBP — diastolic blood pressure; BP med —medicated blood pressure; RE — refractive error; VA — visual acuity; DR stage — diabetic retinopathy stage; ME — presence of macular edema; OP — ocular pressure.

A higher value of SFCT is significantly associated with abnormal layer morphology ($p = 0.033$).

Considering the association found with age, the correlation obtained between SFCT and age (Spearman coefficient) is negative and moderate ($r = -0.4667$; $p < 0.001$).

For group 2, to study the impact of the variables CFRT, contour, layers, SBP, DBP, BP medicated, RE, VA, age, and OP with the variable SFCT, a linear regression model was performed with the variable SFCT as dependent variable and the remaining variables as independent ones (table 22).

The model obtained is statistically significant ($p < 0.001$) and explains about 44% of the variance of SFCT ($R^2 = 0.439$).

SFCT	Coef.	Std. Err.	t	P>t	[95% Conf.	Interval]
CFRT	0.51	0.4	1.2	0.246	-0.4	1.4
contour	9.85	24.1	0.4	0.685	-38.6	58.3
layers	-38.05	23.8	-1.6	0.116	-85.9	9.8
SBP	2.24	0.8	2.8	0.007	0.6	3.8
DBP	-3.41	1.4	-2.5	0.017	-6.2	-0.6
BPmed	22.12	17.7	1.3	0.218	-13.5	57.7
RE	-1.62	8.4	-0.2	0.847	-18.4	15.2
ME	1.47	1.8	0.8	0.429	-2.2	5.2
Age	-2.38	0.8	-3.1	0.003	-3.9	-0.8
OP	-0.60	2.9	-0.2	0.838	-6.5	5.3
_cons	220.54	161.5	1.4	0.178	-103.8	544.9

Table 22 — Multivariate analysis with SFCT as the dependent variable — Control group.

Legend: Contour — sclero-choroidal border morphology (normal or abnormal); layers — choroidal layers (normal or abnormal); SBP — systolic blood pressure; DBP — diastolic blood pressure; BP med — medicated blood pressure; RE — refractive error; VA — visual acuity; DR stage — diabetic retinopathy stage; ME — presence of macular edema; OP — ocular pressure.

A higher value of SFCT is associated with a higher value of SBP ($p = 0.007$), lower value of DBP ($p = 0.017$) and at a younger age ($p = 0.003$).

Considering the association found with age, the correlation obtained between SFCT and age (Spearman coefficient) is negative and moderate ($r = -0.424$; $p < 0.001$).

4.2.3.2 PROGRESSION

Group 1, Diabetic

85 eyes were analyzed for V2.

The variables used for analysis of progression for the 2 consecutive visits were SFCT, CFRT, HbA1c, SBP, DBP, DR stage, and correlation with age and duration of Diabetes at baseline was looked for.

No significantly statistical difference was found between the 2 visits for SFCT, CFRT and blood pressure. Significance was found for glycosylated hemoglobin, but it is not clinically significant (table 23).

Variable	Obs	Mean	Std. Dev.	Min	Max	P (Wilcoxon)
SFCT_V1	196	273.37	80.94	96.00	495.00	0.1012
SFCT_V2	85	267.15	78.42	82.00	430.00	
CFRT_V1	196	270.55	45.94	209.00	517.00	0.4828
CFRT_V2	85	272.31	50.24	197.00	568.00	
HbA1_V1	183	7.43	1.81	5.10	13.60	0.0332
HbA1_V2	85	7.35	1.69	4.40	13.00	
SBP_V1	165	140.53	20.02	105.00	197.00	0.0512
SBP_V2	85	134.41	17.38	98.00	193.00	
DBP_V1	165	76.35	13.65	45.00	132.00	0.3896
SBP_V2	85	73.21	10.65	54.00	92.00	

Table 23 — Progression analysis — diabetic group.

Legend: V1 — baseline; V2 — second visit. HbA1c — serum glycosylated hemoglobin; SBP — systolic blood pressure; DBP — diastolic blood pressure.

There was a slight and non-significant decrease of SFCT from V1 to V2 (Wilcoxon; $p=0.1012$), with no correlation with the variables analyzed (table 24)

	SFCT_Dif	CFRT_Dif	HbA1_Dif	SistBP~f	DiastBP~f
SFCT_Dif	1.000				
CFRT_Dif	0.224	1.000			
	<i>0.089</i>				
HbA1_Dif	0.034	-0.148	1.000		
	<i>0.800</i>	<i>0.264</i>			
SBP_Dif	0.089	0.005	-0.276	1.000	
	<i>0.503</i>	<i>0.968</i>	<i>0.035</i>		
DBP_Dif	0.113	-0.377	-0.003	0.687	1.000
	<i>0.393</i>	<i>0.003</i>	<i>0.984</i>	<i>0.000</i>	

Table 24 — Correlation analysis between SFCT variation and CFRT and systemic variables — diabetic group.

The variation of SCFT did not show any correlation with the duration of Diabetes or age ($r = -0.155$; $p = 0.158$ for the duration of Diabetes, and $r = -0.156$; $p = 0.155$ for Age) — table 25.

	SFCT_Dif	Years Diabetes~s	age
SFCT_Dif	1.000		
Years — Diabetes	-0.155	1.000	
	<i>0.158</i>		
age	-0.156	0.1713	1.000
	<i>0.155</i>	<i>0.1170</i>	

Table 25 — Correlation of Variation of SCFT with duration of Diabetes and with age

Comparison between the stage of DR from V1 to V2 for each eye was performed for the 85 eyes with a second visit. In V1 we had 61.9% eyes with grade 0 (no DR); 23.8% with Grade 1 (mild NPDR); 10.7% with Grade 2 (moderate NPDR) and 3.6% with grade 3 (severe NPDR or PDR). In V2 we have 57.1% eyes with grade 0; 34.5%

with Grade 1; 4.8% with Grade 2 and 3.6% with grade 3. 79.9% of the eyes maintained the degree of DR from V1 to V2: 52.4% eyes with grade 0; 19% with grade 1; 4.8% with Grade 2 and 3.6% with grade 3.

Statistically there was no significant variance ($p= 0.0744$: Stuart-Maxwell test) for the DR stage, and for Macular edema ($p= 0.6547$: McNemar test).

The stage of DR was not analyzed for progression since very few patients had changes from baseline to V2. Four patients had a slight improvement in the DR stage (mild to no visible lesions). For Macular edema, 3 eyes with no ME at baseline had ME on V2. Eyes with macular edema at baseline were directed for treatment and dropped out from the study statistical analysis. The eyes with macular edema were analyzed individually for morphological changes (chapter 4.2.1).

Group 2, Control

14 eyes were analyzed for V2.

The variables used for analysis of progression for the 2 consecutive visits were SFCT, CFRT, SBP, DBP and correlation with age at baseline was looked for.

Variable	Obs	Mean	Std. Dev.	Min	Max	P (Wilcoxon)
SFCT_V1	78	281.8	74.1	61.0	412.0	0.729
SFCT_V2	14	286.9	55.9	193.0	399.0	
CFRT_V1	78	258.3	26.7	173	309.0	0.091
CFRT_V2	14	268.9	26.2	194.0	296.0	
SBP_V1	62	135.3	20.1	102.0	199.0	0.664
SBP_V2	12	124.0	13.7	101.0	144.0	
DBP_V1	62	78.4	12.9	52.0	114.0	0.875
DBP_V2	12	70.67	7.22	58.00	81.00	

Table 26 — Progression analysis — control group.

Legend: V1 — baseline; V2 — second visit. SBP — systolic blood pressure; DBP — diastolic blood pressure.

There was a slight and non-significant increase of SFCT from V1 to V2 (Wilcoxon; $p=0.729$), with no correlation with the variables analyzed (table 26).

There was a negative and moderate correlation between the variation of SFCT and CFRT. However, this correlation was not statically significant ($r = -0.408$; $p = 0.188$). No correlation was found between the variation of SFCT and age ($r=0.130$; $p=0.657$). (table 27).

	SFCT_Dif	CFRT_Dif	SistBP~f	DiastBP~f
SFCT_Dif	1.000			
CFRT_Dif	-0.408	1.000		
	<i>0.188</i>			
SBP_Dif	-0.286	-0.170	1.000	
	<i>0.367</i>	<i>0.590</i>		
DBP_Dif	-0.332	0.220	0.070	1.000
	<i>0.291</i>	<i>0.490</i>	<i>0.820</i>	

Table 27 — Correlation analysis between SFCT variation and CFRT and systemic variables — control group.

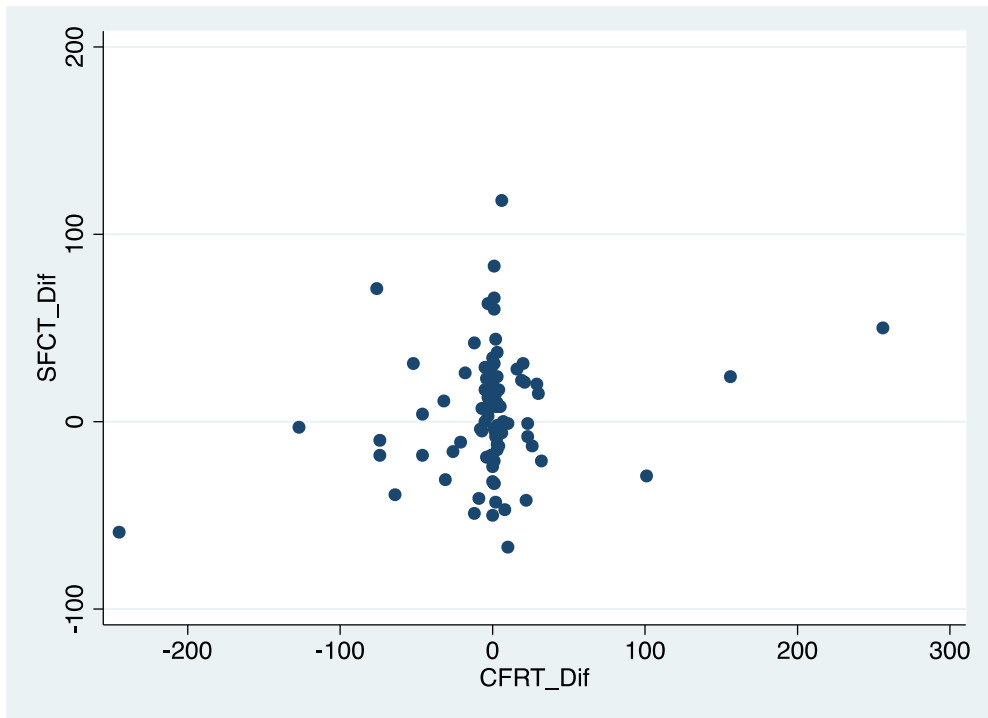
To study the impact of CFRT variables (v2-v1), SBP (v2-v1), (v2-V1), age, and group (i.e., control or diabetic) with the variable SFCT (v2-v1), a linear regression model was performed with the variable SFCT (v2-v1) as a dependent variable and the remaining variables as independent ones (table 28).

The model obtained was not statistically significant (P = 0.060) and explains about 7.3 % of the variance of SFCT (V2-V1) (R2 = 0.0734).

SFCT_Dif	Coef.	Std. Err.	t	P>t	[95% Conf.	Interval]
CFRT_Dif	0.178	0.065	2.74	0.008	0.048	0.307
SBP_Dif	-0.042	0.229	-0.18	0.857	-0.499	0.416
DBP_Dif	0.384	0.392	0.98	0.331	-0.398	1.165
Age	-0.411	0.317	-1.30	0.199	-1.044	0.221
Group	10.511	9.117	1.15	0.253	-7.656	28.682
_cons	21.378	18.900	1.13	0.262	-16.290	59.046

Table 28 — Multivariate analysis of progression of variables with SFCT progression — control group.

The only factor associated with the variation of the SFCT is the variation of the CFRT, where a greater variation of SFCT is associated with a greater variation of CFRT ($P=0.008$) — graphic 6. But this association is weak (Spearman coefficient: $r = 0.0681$; $p = 0.5097$).



Graphic 6 — Correlation of progression of SFCT and CFRT — control group

CHAPTER 5 — DISCUSSION

5 — DISCUSSION

The study included an important sample of patients that were followed for about two years. Its purpose was twofold:

- to evaluate the correlation of choroidal features and changes with diabetic retinopathy and to identify possible markers of a diabetic choroidopathy in OCT images.
- to find out whether choroidal thickness measurement could be considered alone as a reliable parameter for diabetic choroidopathy and if it could be related or justified by morphological findings in the choroidal structure.

Very little was known about this at the beginning of the study. In order to avoid possible bias of choroidal changes caused by any diabetic retinopathy treatment such as laser and/or intravitreal injections, or other ocular treatments, since their effects on the choroid are still unclear, these were considered as exclusion criteria. Published data regarding possible effects of treatment on the choroid are unclear and disparate. While Ohara et al¹⁵⁰ and Zhang et al¹⁵¹ described a significantly decrease in CT after pan retinal photocoagulation (PRP), Cho et al¹⁵² described an increase in CT after PRP. Kniggiendorf¹⁵³ and Lains¹⁵⁴ described a choroidal thinning following treatment with intravitreal Anti-VEGF.

Since we considered previous treatment as exclusion criteria, most eyes included in this study were in earlier stages of the disease or had no diabetic retinopathy. In Portugal there is a National screening program for diabetic retinopathy that allows to evaluate, detect and treat almost all patients diagnosed with Diabetes by the family

Doctor and presenting diabetic retinopathy, most times in very early stages of diabetic retinopathy. It is not frequent to observe at the sub-speciality Retina consultation of the Ophthalmology department of an end-line treatment Hospital, more advanced cases of diabetic retinopathy with or without macular edema, but naïve of any treatment.

Being an observational study with the intent to evaluate the natural course of progression, the follow-up visits were not planned with a restricted timing as it is done in clinical trials and were dependent on the appointment made by the family doctor and the health system gear. Thus, the follow-up visits interval varied a lot and many patients were lost of follow-up leading to an important decrease on the sample for ensuing visits.

The study included both patients' eyes except in situations where exclusion criteria were found in one eye. The inclusion of the two eyes was part of the principle that the changes to be studied were specific to each eye, independent of the contralateral eye. Thus, the non-ocular variables were presented demographically by patient (age, sex, SBP, DBP, HbA1c, Diabetes in years) while ocular variables were presented by eye (VA, RE, OP, SFCT, CFRT, contour, Layers, DR). The non-ocular variables were selected on the basis of previously published data that refer to a possible effect on choroidal thickness. Visual acuity, refractive error and ocular pressure were also recorded to have statistical data of possible effects on the choroid, but it was not the purpose of the study to correlate choroidal findings with visual function refractive error and ocular pressure.

Since one of the purposes of the study was to evaluate choroidal morphologic findings on OCT images, and few or almost none of these had been described previously in literature, we performed two pilot studies to define parameters for evaluation and comparison in the main study. In order to make choroidal thickness comparable with other publications, in this study we decided to register the subfoveal choroidal thickness for statistical analysis. However, variations in choroidal thickness along the scans were analyzed with the morphologic evaluation of the retina and choroid.

It should also be noted that both graders for the OCT images (Lilianne Duarte and Miguel Ruão) had previously made an inter-grader variability study for choroidal posterior boundaries and choroidal thickness measurements with high agreement (unpublished data). The OCT devices used for this study had not a built-in software for automatic segmentation of the choroid boundaries, so this was done manually on the line scans. We could have tried to build a choroidal thickness map manually by doing segmentation of each scan of the cube protocol and slide the layers of the retinal thickness map, but this would be time consuming with great risk of slight errors of segmentation. Thus, in order to get superimposed thickness maps of the retina and choroid, we performed an ancillary study in collaboration with another Hospital with an OCT device that performs choroidal maps by automated segmentation.

Only with follow up visits and images it is possible to evaluate if any findings found in a single visit change with progression of the disease with possible clinical meaning. Therefore, our study was designed as longitudinal, and morphologic and statistical analysis was made. Although some patients performed more than two

visits, the sample was too small to have significance, so we did the analysis comparing two follow-up visits. As far as we know, there is no other longitudinal study evaluating choroidal findings in diabetic patients.

The outcome of our study shows that we can define normal morphologic features of the choroid layers and sclero-choroidal interface. With diabetic disease, changes in those morphologic features can be observed, classified, followed up and correlated with the retinal disease. Choroidal morphological changes occur focally related to the subjacent retina. Automated retinal and choroidal superimposed maps could be an easy way to identify focal zones to be evaluated for morphological changes. Statistical analysis showed a great variability and dispersion of sub-foveal choroidal thickness with an important variation susceptibility to different variables, turning into a low reliable parameter. Nevertheless, some significance was found between choroidal thickness in the correlation with age (decreases with age) for both groups: in Diabetics also with choroidal morphological changes (corroborating the morphologic study results) and in Controls also with blood pressure.

For both groups, Diabetics and Controls, ocular but non-retinal or choroidal variables (VA, RE, OP), no statistically significant differences were found between OD and OS. These results give confidence in analyzing all eyes as separate subjects for retinal and choroidal findings.

We compared the 2 groups (control and diabetic) regarding the non-retinal or choroidal variables, and using non-parametric tests due to the non-normality of the variables we found the following results:

- There were statistically significant differences between the two groups for:
 - VA — it makes clinical sense because the presence of pathology in diabetic eyes can interfere with the visual function;
 - SBP — Diabetic patients usually are with more morbidity, sometimes with kidney diabetic disease that can affect blood pressure control; and for RE and OP.
- The statistical significance finding however, has no clinical relevance. In fact, if we look to the mean values, they have no clinical significance.

Since there was no significant difference for age, sex, and refractive error, we can consider that the groups were similar for these parameters.

The use of parametric tests is justified by the fact that most variables do not follow normal distribution within each group. Those considered statistically as normal are: age (only for diabetics); gender; refractive error (only for controls); DBP (only for controls); SFCT (only for diabetics); CFRT (only for controls). To avoid any bias in the statistical analysis, since some variables had normal distribution and others did not, we opted to use non-parametric tests, thus making the analysis more robust.

When comparing both groups, there were no significant differences between SCFT and CFRT at baseline between the 2 groups (diabetic and control), but most of the diabetic (62%) had no retinopathy, being comparable to controls.

Nevertheless, besides the statistical result, we do have to look to the graphic for individual values to have the perception of the great variability of SFCT measurements by age or CFRT.

Statistical Analysis of diabetics at baseline

In our research, we found SFCT mean values of $273.8 \mu \pm 80.9$ (range: 96-495 μ). When analyzing them by diabetic retinopathy sub-groups we found that the values were similar for NDR, mild NPDR and moderate NPDR, but higher in severe NPDR and PDR (respectively: $264.32 \mu \pm 81.08$; $262 \mu \pm 65.6$; $265.64 \mu \pm 85.46$; $336.75 \mu \pm 55.57$). In the cases of macular edema the value was $262.81 \mu \pm 85.10$. As described previously in the literature review, mean values of SFCT in diabetic patients vary from studies. A great number of studies showed a decrease in SFCT with the severity of the diabetic retinopathy, while we found higher values in more severe stages, as described by Kim et al in a large sample study¹³⁸. Our results can be biased since the number of eyes with more advanced disease was too small. However, like the results from all other published studies, what remains is the great variability or dispersion of SFCT measurements, which raises the question if mean value of a single sub foveal measurement is reliable. The choroidal thickness variability can be dependent on systemic, individual or pathologic conditions. Campos et al¹⁵⁵ and Melancia et al¹⁵⁶ made important reviews concerning publications somehow controversial results regarding choroidal thickness in Diabetes. As referred by Campos et al, published studies could not be entirely comparable for choroidal thickness since in they differ in terms of the design and variables analyzed. Some studies compared healthy patients with diabetic ones

without retinopathy^{127–131,138,142,157}, and others compared healthy patients with diabetic ones with retinopathy disease and/or macular edema^{78,128,130,138,142,158,159}. Increase, decrease or no change of choroidal thickness compared to healthy or related to the retinopathy stage can be found in the literature. Most studies are not longitudinal and are based in one single visit measurement. Few studies looked for correlation of choroidal thickness with other variables.

In our study, when analyzing the impact of various variables on SFCT using the model of linear regression we obtained a statistically significant result ($p=0.001$) with a R^2 of 0.4020 (it explains 40% of the SFCT variance). In other words, the fact that the model is significant means that the selected variables explain and can somehow predict the dependent variable (SFCT), and the value of R^2 tells us that the model can explain a lot or a little. More than one third of the variable (SFCT) may be influenced by the remaining variables. When we look at the results of the model, we see that the variables that actually could explain or predict the dependent variable SFCT, are the ones that were significant i.e. layers (choroidal morphologic changes) and age, and the others end up explaining very little. The variable layers could be predictive since their significance level was of $p=0.033$. Significance was also found negatively correlated with age. What these statistical results tell us is that, although SFCT can be influenced by various variables, the ones that have a significant impact are an increased thickness correlated to normal choroidal layers and decreased thickness with increasing age. No significant correlation was found with the central retinal thickness, which could be explained by the similar SFCT approximate value for eyes with macular edema comparing to the greater sample of eyes with NDR or initial stages. Most published studies regarding choroidal thickness in Diabetes do

not do a multivariate analysis to evaluate the impact of other variables in SFCT measurements. Few studies look for correlation with univariate analysis with metabolic state, duration of Diabetes, and age. The only consensual correlated variable is age with progressive decrease of thickness measurements. The choroid is a richly vascular structure with involving fibroblast and muscle meshwork. It is, therefore, expectable to have contractile or expansion (dilatation) response from these structures to physiologic and pathologic conditions, either ocular or systemic. On diabetic patients the metabolic state is altered frequently and associated to other morbidities such as high blood pressure. We do know from elsewhere in the body the vascular effect and damage of hyperglycemia and vascular changes with blood pressure disease. Nevertheless, in our study metabolic state and blood pressure, or duration of Diabetes could explain some variability but were not significant for correlation with SFCT. The same result was found for ocular variables except the choroidal ones. In their work, Xu et al¹⁵⁷ also did a multivariate analysis and found correlation of SFCT with glycosylated Hemoglobin, age, diastolic blood pressure and the diagnose of Diabetes, but no correlation with the presence or stage of diabetic retinopathy. These findings also alert to the caution of using choroidal thickness alone as a parameter to determine the diabetic choroidopathy.

Control Baseline Statistical Analysis

We found for the control group mean SFCT values of $281.8 \mu \pm 74.1$ (ranging from 61 to 412μ). Our results are within the mean values of other studies in healthy population (table 1), but as described previously data vary tremendously from paper to paper. Control group also had a great variability in the SFCT values, as in the

diabetic group. Comparing with post-mortem data of choroidal thickness ($\pm 220 \mu$) our mean choroidal thickness is slightly higher, but we should expect a thinning with histologic preparations and dehydration phenomena. Sohn et al in 2014¹⁶⁰ published a histology study demonstrating a normal distribution of choroidal thickness but with a high range of thickness values, corroborating findings in published studies as well as in ours. Furthermore, it is expectable to have a multitude of variables that can interfere with the choroidal thickness measurement, even physiologic conditions.

When analyzing the impact of other variables on SFCT the model obtained was statistically significant ($p < 0.001$) explaining about 44% or more of the SFCT variance ($R^2 = 0.439$). A positive significant correlation was found only with SBP and a negative correlation with DBP and age. The simple regression model gives us a ratio of SFCT decrease of $-38\mu/10$ years. However, using a model of regression analysis taking into account the variables statistically significant (and considering SBP constant), then the ratio of loss falls to $-23\mu/10$ years. The correlation of choroidal thinning with aging is the only consensual data from all studies, but the ratio for 10 years varies from -11.8μ (Pappuru⁹⁶), -13.1μ (Shin¹⁰³), -14μ (Ikuno⁹⁸), -15.6μ (Margolis¹⁸), -19.5μ (Ouyang¹⁰¹), -30μ (Hirata⁹⁹) to -33μ (Wei¹⁰⁴). These differences in the ratio might be justified by the fact that just few authors made corrections for statistically significant variables, and samples were very different in number, age and race (table 1). It is risky to establish a mean ratio of thinning with age since multifactorial factors can affect choroidal thickness. One of these factors can be blood pressure: in our study we found significance for systolic blood pressure. The choroid as a highly vascular structure can be sensitive to changes in systemic blood pressure. Few studies were published regarding the effect of systemic blood

pressure in choroidal thickness, but results are controversial. Akay et al¹⁶¹ and Ahn et al¹⁶² found a correlation of increased systemic arterial blood pressure with CT (with severe hypertension in the latter), but GöK et al¹⁶³ conclude in their study that blood hypertension does not affect CT. Samson et al¹⁶⁴ made a multivariate analysis in their study where they found a similar result to ours: a correlation only between systolic blood pressure with increased CT. Even if we still don't know the real effect that blood pressure and blood pressure medication could have on CT measurements, it might be a confounding co-factor, especially if severe or uncontrolled. Other studies^{165,166} in healthy populations demonstrated diurnal choroidal thickness variability, by comparing morning to late afternoon measurements on the same individuals and the same day.

Progression statistical analysis

In the progression analysis there was no major or significant variation/progression of all variables, hence it is difficult to find correlations. The multivariate analysis of the impact of the other variables on SFCT was not statistically significant ($p=0.060$) with a $R^2= 0.0734$ explaining only 7.3% of the variance.

The only factor associated with the variation of the SFCT is the variation of the CFRT: a greater variation of SFCT is associated with a greater variation of CFRT ($P = 0.008$). Considering the association found with SFCT (Spearman coefficient) this association is, however, weak ($r = 0.0681$; $p = 0.5097$).

No publication was found with longitudinal data (sequential visits) for progression to compare with our results.

We did not find statistically significant data. Probably because most eyes in diabetic group were at the initial stages or even with no retinopathy, relatively well controlled metabolically, comparable to controls. Therefore, a mean of two year of follow up might be a too short follow-up period for disease progression evaluation. Moreover, with the “lost-to-follow-up” rate and the eyes dropped out for treatment, the sample decreased on the second visit. Data was in general almost the same for baseline and the second visit. Nevertheless, a weak correlation was found between the retinal progression and choroidal thickness change.

Morphological Analysis

From the pilot study we found differences in morphology of the choroid of normal and diabetic eyes, which allowed establishing a classification system of normal and abnormal that was used for the main study. The pilot study allowed suggesting that:

- In healthy eyes, the SCI border tends to be regular, and has an inverted dome shape with the thickest point under the fovea; the ChS layer is regular and homogeneous with no focal invasion of great vessels
- In diabetic eyes, this regular and homogeneous aspect tends to be disturbed, especially with progression of the retinopathy state, but it is in the presence of Macular edema that we can find a correlation between the choroidal morphological changes and the suffering suprajacent retina. Findings are: loss of the “inverted dome shape” and irregular delineation of the SCI, abnormal layers with loss of the integrity of the mottled ChS and parallel to the Bruch’s membrane, focal atrophy or increased thickness of

vascular layers, loss of even distribution, hyperreflective spaces on the vascular zone.

Based on this normal and abnormal classification for SCI and Vascular layers, a morphologic analysis was made on the main study.

For the healthy control group, we found that:

- The ChS layer was always preserved (mottled, homogeneous with posterior limit parallel to the Bruch's membrane
- Most eyes had a normal SCI (inverted dome shape with thickest point subfoveal). When irregular it was always due to great vessels layer abnormalities.
- Thinnest choroids in older subjects difficult evaluation.

For the diabetic group we found that:

- Half of the eyes had no morphologic abnormalities, probably, because most eyes had no DR or were at initial stages of DR.
- When choroidal morphologic changes were found, they were particularly due to vascular changes than SCI changes, and primarily on the ChS layer and in eyes with DR.
- Changes in the great vessel layers were the major responsible for the irregular sclero-choroidal border, usually due to focal atrophy or thinning, loss of vessels with hyperreflective spaces occupying the vessels space or hypertrophy.

- In the absence of evident retinal disease and changes in the choriocapillaris/Sattler's layer, great vessels layer abnormalities are usually caused by focal loss or atrophy, more frequently nasal to the fovea, or loss of even distribution.
- The changes on the choriocapillaris/Sattler's layer such as focal atrophy/loss with approach of the great vessels to the Bruch's membrane and hypertrophy associated with focal thinning or loss of subjacent great vessels, are correlated to the changes in the retinal anatomy above them. This becomes more evident in the presence of macular edema, specially, if the photoreceptor layer is affected.

Only two published studies (Branchini¹⁴⁸ and Adhi¹⁴³), were done looking for morphologic findings of the choroid, using cross-sectional OCT images. The first study was carried out in healthy patients and findings compared with eyes with pathology such Age Macular Disease. The results of their study were used as a classification reference for our pilot studies. The second was performed in diabetic patients compared with healthy controls. This study has various similarities with ours. As parameters to evaluate choroidal morphologic changes were defined: the choroidoscleral interface could be regular, convex or bowl shaped (normal) or irregular or "S" shaped; they considered as normal if the thickest point of the choroid was sub-foveal (beneath the fovea or 100 μ nasal or temporal); focal thinning of choroidal thickness was considered whenever the thinning was 50% less than the mean value in healthy (previously established) at the same location. However, for vascular analysis, a cut-off value was established for the diameter of large vessels (> 100 μ). The large sub-foveal vessel and thickness measure from the anterior to

choroidoscleral limits of the vessel were identified in order to determine great vessels layer thickness by subtraction from the total SFCT, and consequently the Sattler and choriocapillaris layers. An irregular contour of the SCI was found on more than 90% of the eyes with diabetic retinopathy but not in the healthy ones. In addition, a significant thinning in CT in the Sattler and choriocapillaris layers in advanced stages of DR and Macular edema was found.

The results of our morphological study are in accordance with the results of the studies mentioned above. However, in those studies, the morphological and vascular analysis was performed only at the subfoveal location. The method used in those studies for vascular analysis using mean values extrapolated from central measurements do not identify focal extra-foveal changes in choroidal morphology. The authors do not do a direct correlation of the focal choroidal changes with the retina above. It is a retrospective of one visit analysis with no data regarding progression of the findings. A number of patients were previously treated, so we cannot be sure if some findings could be a consequence of the treatment performed.

Other studies^{167–169} looking for choroidal morphological findings on OCT used on the other hand, En-face images. In our point of view, those studies had some limitations, since the choroidal layers were identified by pre-determined thickness slabs based on mean thickness values previously established. If we take into account that there is a great variability in thickness of the choroid in healthy patients, and if in pathology the layers become irregular, we can predict artifacts on the evaluation. Nevertheless, Murakami et al¹⁶⁸ found that diabetic eyes had more frequently than controls groups, areas without definite vascular structures in Sattler's layer, focally narrowed vessels

and vascular stump in Haller's layer. But, statistically, they found no association of morphological changes with CT.

Our findings are particularly interesting in that they suggest a response of the choroid to the retinal disease where it seems that to more acute stages a functional choroid respond increasing the blood flow to nourish the suffering retina, but later a diabetic choroidopathy occurs with ischemic, atrophic and other changes. Choroidal morphological changes seem to occur in a focal manner and only subjacent to the zone of the retina needing further nutrition and metabolic input.

However, only with consecutive exams in follow-up visits we can validate if the choroidal morphological findings really may represent diabetic choroidopathy and its correlation with the retinal disease. In order to evaluate that, this study was designed as longitudinal research with follow-up visits, looking for progression on choroidal morphologic changes. We found that SFCT varied in subsequent visits despite the CFRT evolution. However, there was no evidence of any pattern or correlation of SFCT change (either an increase or a decrease) with the retinal thickness, although a great percentage of eyes with decrease in SFCT had also a CFRT decrease. Even when we stratified for severity of thickness change, no patterns were evident. SFCT should not be considered as a reliable parameter to evaluate progression or risk of progression, or a parameter to define severity or sequela of the retinal diabetic disease.

From case to case analysis we found that focal changes in the retina tended to have subjacent choroidal changes. This may be explained by the theoretical assumption

of the choroidal function to support the retina, particularly the posterior layers. It seemed that, in some cases of retinal disturbances, there was a need to improve vascular and blood supply with a reactive or physiologic enlargement or dilatation of the great vessels pushed towards the Bruch's membrane external limit and the retina. When the ocular diabetic disease becomes more advanced, the physiologic response of the choroid fails, and the choroid might start with Diabetes microvascular complications, with ischemic processes leading to focal areas of atrophy of the ChS layer and/or the great vessels layer, which corresponds on OCT images to the focal areas hyperreflective and/or atrophic.

We know from histology that the choriocapillaris is organized in lobules as independent functional units with intervention on the retina immediately above, and only the choriocapillaris leak in the choroid. This may explain the correlation of focal retinal changes with the subjacent choroid found in our study. Even before the OCT, in histologic studies, Hidayat and Fine⁷⁰, Fryczkowsky⁷¹ and Cao⁷² described a diabetic vascular choroidopathy with degeneration of the choriocapillaris with capillary dropout, basement membrane thickening, vascular abnormalities, such as, tortuosity, dilatation narrowing, microaneurysms and neovascularization. Cao et al. add that focal choriocapillaris degeneration is more initial and becomes diffuse at advanced stages associated with neovascularization.

An interesting work of Zouache et al in 2016 demonstrates that the architecture of the choriocapillaris in independent capillary networks units, the lobules, are correlated with individual unit blood flow rates which can lead to localized

implications of the suprajacent retina function. This might be in agreement with the OCT findings of related focal choroidal changes with suprajacent retinopathy.

In an excellent review of diabetic choroidopathy in 2017, Luty et al¹⁷⁰ postulate that inflammation and inflammatory cells might contribute to loss of choroidal vasculature. This was based on previously demonstrated accumulation of macrophages and PMNs in the retinas of diabetic rats. From histology and histochemistry there is evidence of a Diabetic choroidopathy that somehow leads to morphological changes in the choroid.

Querques et al¹⁴² postulated a mechanism to explain how the choroid could be involved in the development of diabetic macular edema. They suggest that a decreased sub foveal choroidal thickness could cause tissue hypoxia with an increase in the level of VEGF, resulting in the breakdown of the blood-retinal barrier, responsible for the development of DR and macular edema¹⁴⁵.

The choroid has a completely different anatomy from the retina. While the retina is composed primarily of well-structured and organized cellular layers, with very little ability or property of changing size, the choroid is a highly and mostly vascular structure involved in connective tissue with high ability and property in changing size and thickness due to contractile and blood flow states. Thus, it is reliable to establish normal thickness values for the retina, since anatomically no extreme variability is expected at physiologic states. Moreover, even having choroidal thickness values from histology, on in vivo state, it is highly susceptible to physiologic influence, be it ocular or systemic, with a high variability of measurements. Thus, thickness

measurement only makes sense if correlated with morphology and analyzed individually and focally in subsequent visits.

From our findings, focal morphologic changes in the choroid were correlated with focal changes in the retina. We made an ancillary study to evaluate if superimposing automated OCT retina thickness maps with choroid thickness maps would allow us to quickly localize focal areas of choroid morphologic changes correlated with the retinal disease. Our results demonstrated that we can superimpose retinal changes with choroidal changes using the maps and easily identify the focal zone to evaluate for morphological choroidal changes in line scans. Normal eyes showed the same pattern of choroidal thickness map as described in previously published studies^{99,101,106–109,128,131,133}. They showed a continuous decrease in thickness from the superior, to temporal, to inferior to the nasal macula — the STIN pattern. In diabetic eyes different patterns of maps were found, with evidence of changes in the choroid even in early stages of DR. These results should be validated with a larger sample study. Unfortunately, till now, only one commercially available OCT (Topcon SS OCT) device has a software for automated choroidal thickness maps. With all the other OCTs available, we can build a choroidal thickness map doing choroid segmentation manually for each scan of the macular cube. This procedure is time-consuming with great probability of segmentation errors in different scans, becoming not reliable or feasible.

Our study has some limitations or weaknesses.

The classification used to define choroidal morphologic findings is dependent on quality and resolution of OCT images to allow good identification of SCI border and vascular abnormalities. In most available OCT devices, automatic SCI limit segmentation is not an option and becomes dependent on the training of the grader. When the choroid is very thin it is impossible to evaluate all the parameters described as to be evaluated for classification. Even with our simple classification, in some cases it is not easy to identify the choroidal findings or boundaries. A very clear definition needs to be made. Huynh et al.¹⁷¹ made a review looking to the posterior boundaries of the choroid in several studies and found some variability and lack of clarity in the definition of the exact choroidal scleral interface, leading to the variability in choroidal thickness measurements. They propose a harmonization classification and suggest that, for choroidal thickness measurements, the posterior boundary should be considered as the end of the choroidal vessels. Nevertheless, they advise that the suprachoroidal layer should also be measured, since it can have clinical relevance in pathology.¹⁷¹

In our study we have done statistical analysis only for subfoveal choroidal thickness, although we demonstrate that changes in thickness occurs focally, sometimes extra-foveal. Using only the central value for statistical analysis can leave out important thickness changes to be taken into account in the statistical data. But this is a limitation of all published papers, and our study was designed so as to be comparable with other studies.

In order to avoid the possible bias of the results, the inclusion/exclusion criteria were very strict, and only treatment-naïve eyes were allowed. Although we had a very good sample of eyes, the distribution by diabetic retinopathy severity groups was not equitable. There was a predominance of eyes with no or initial stages of DR, and therefore, less probability to have pathologic changes. Very few eyes had advanced stages and a small sample had macular edema. These were the ones that showed more prominent choroidal changes in the pilot studies.

One of the main purposes of our study was also to evaluate progression, but the sample was too reduced for follow up visits. With the advance of the diabetic disease, a longer follow-up period may be needed to better evaluate progression.

To our best knowledge, our study is the first to identify choroidal morphologic changes and correlate them with the retinal disease above. We were able to evidence very clearly in the morphologic progression analysis that there are choroidal morphological changes related to the retinal state, that can evolve to recovery or sequela, according to the severity of the disease. We think we demonstrated that statistical analysis of mean choroidal thickness, especially the central or subfoveal (mostly used in studies) is not a very reliable parameter to evaluate diabetic choroidopathy. However, even in the statistical analysis we found correlation with choroidal morphologic changes corroborating the argument that the choroid should be analyzed first for morphologic findings than for thickness. Our study was the first to introduce as a variable in the statistical analysis the presence/absence of morphologic changes in the choroid.

Based on our findings we propose a schematic module of physiologic and pathologic events occurring in the choroid.

NORMAL CHANGES IN CHOROIDAL THICKNESS — PHYSIOLOGIC RESPONSE

Changes in thickness respects the normal anatomy of the choroid, maintaining the inverted dome shape with the thickest point sub-foveal, integrity and homogeneity of the choriocapillaris and Sattler layers. Thickness changes are due essentially to physiologic vasodilatation and vasoconstriction, and it is reversible.

CHOROIDAL THICKNESS AND MORPHOLOGY ANALYSED BY OPTICAL COHERENCE TOMOGRAPHY AS A METHOD TO APPROACH DIABETIC OCULAR DISEASE PROGNOSIS AND PROGRESSION

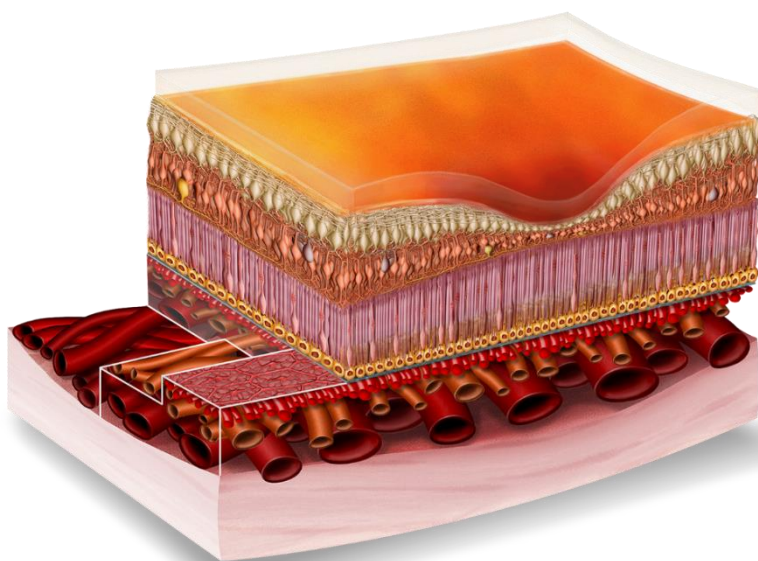
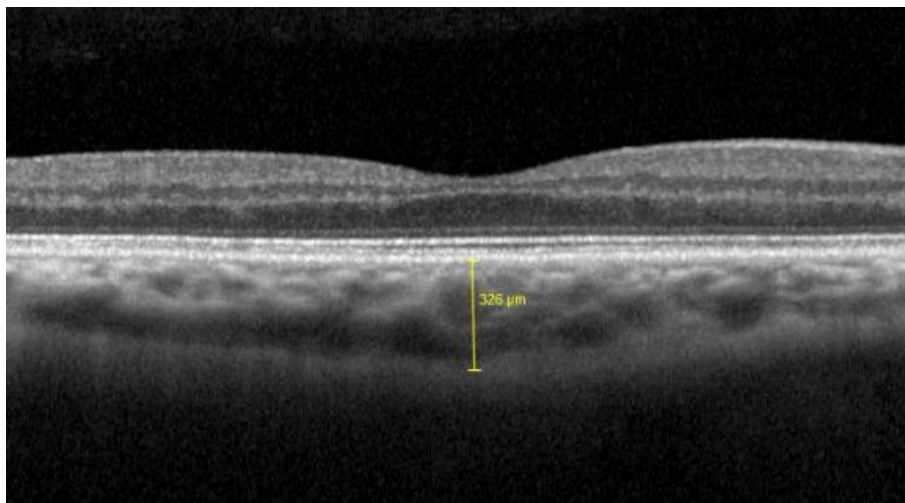
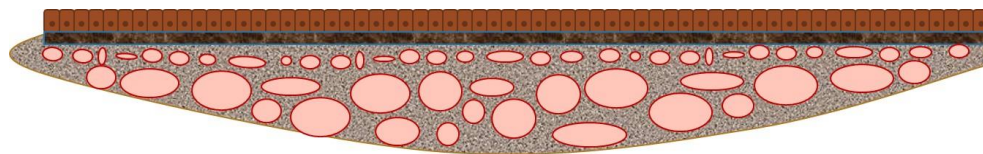


Figure 35 — Schematic and OCT image of normal choroidal morphology.

CHOROIDAL THICKNESS AND MORPHOLOGY ANALYSED BY OPTICAL COHERENCE TOMOGRAPHY AS A METHOD TO APPROACH DIABETIC OCULAR DISEASE PROGNOSIS AND PROGRESSION

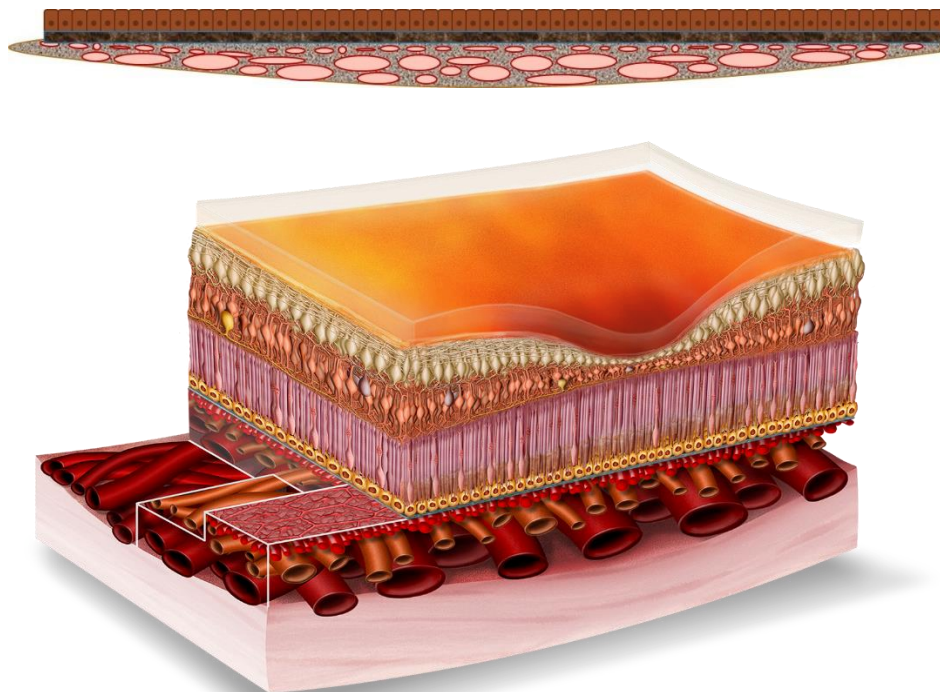


Figure 36 — Schematic image of normal choroidal morphology with vasoconstriction

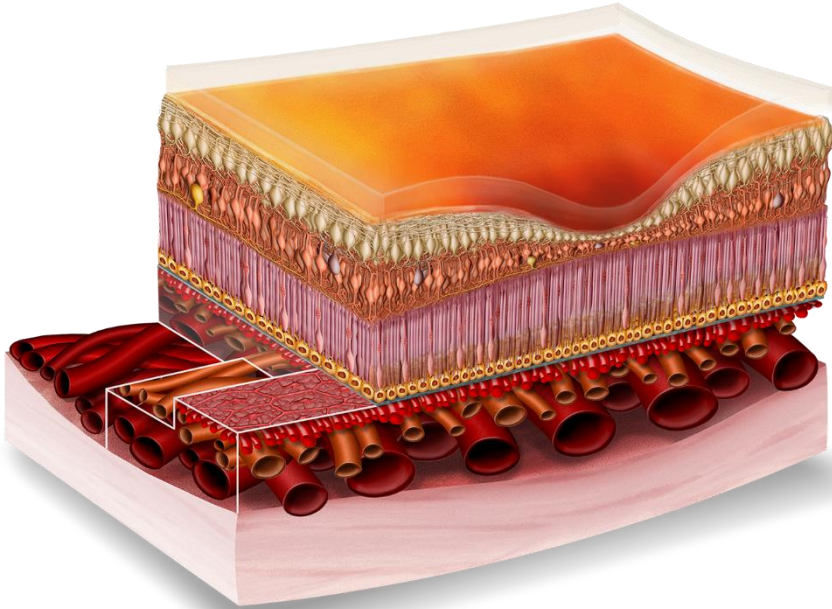
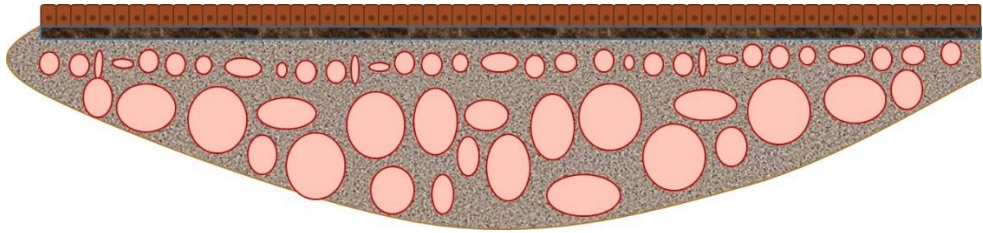


Figure 37 — Schematic image of normal choroidal morphology with vasodilatation

ABNORMAL CHANGES IN CHOROIDAL THICKNESS — PATHOLOGIC RESPONSE

Changes in choroidal morphology with pathologic findings. Focal increase or decrease in thickness causing irregular contour with loss of the inverted dome shape. Focal changes in thickness are correlated with increased vascular caliper and

invasion of adjacent vascular layer (great vessel into the ChS layer or vice-versa),
atrophic vascular layers and/or disappearance of vessels.




Figure 38 — Schematic image of normal choroidal morphology

CHOROIDAL THICKNESS AND MORPHOLOGY ANALYSED BY OPTICAL COHERENCE TOMOGRAPHY AS A METHOD TO APPROACH DIABETIC OCULAR DISEASE PROGNOSIS AND PROGRESSION

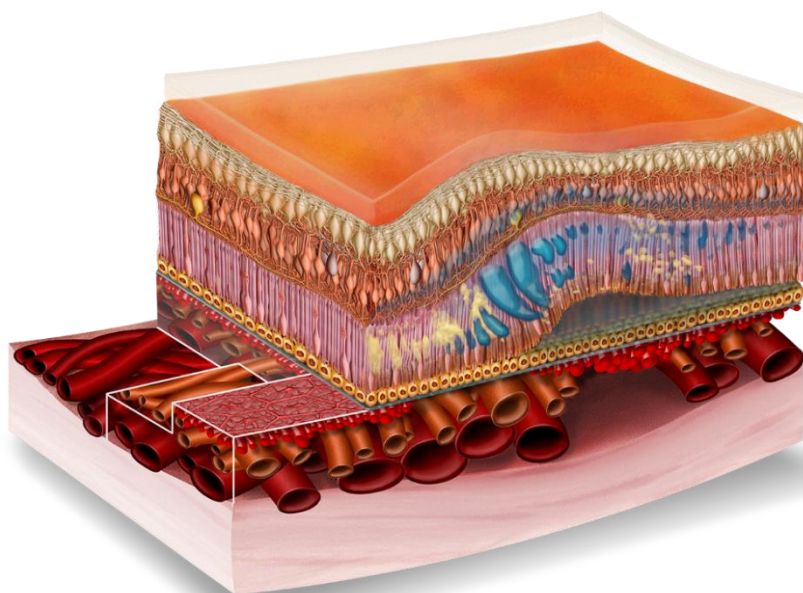
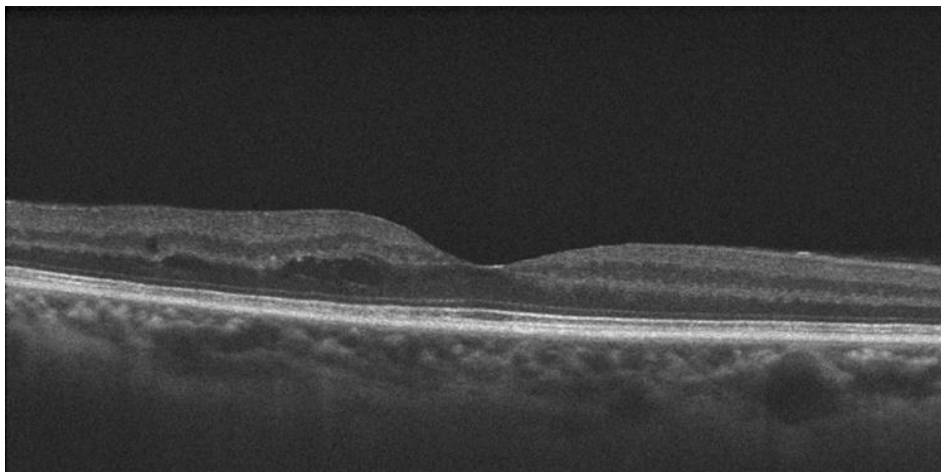


Figure 39 — Schematic and OCT image of an abnormal or pathologic choroidal morphology

Since most morphologic changes in the choroid are vascular, the best way to prove and evidence those changes would be with choroidal vascular architecture maps and flow data.

More recently, with the OCT-Angiography, it has been is possible to obtain angiographic visualization with higher resolution of the vascular architecture (at capillary level) in a noninvasive manner with no dye.

Some studies looking for vascular index and with OCT-angiography have been performed and published, and this could be the future complement to better understand the Diabetic choroidopathy^{133,172-175}.

CHAPTER 6 — CONCLUSION

6 — CONCLUSION

1 — We were able to identify morphologic parameters to be evaluated for normality or abnormality in OCT images of the choroid, allowing a simple classification system, achievable with any commercially available OCT device and software.

2 — With diabetic retinal disease we demonstrated the evidence of a Diabetic choroidopathy directly correlated with the retinal disease above, and that changes occur focally, in accordance to data previously described in histology.

3 — Choroidal thickness alone, as a mean value or one-point measurement is not reliable for analysis. Choroidal thickness changes should be analyzed and validated individually, in a map, correlated with choroidal morphologic changes and in subsequent observations.

4 — The software of currently available OCT devices should be improved to allow automated and reliable choroidal segmentation and automated choroidal thickness maps.

5 — Diabetic choroidopathy can be identified with OCT images, and signs of the disease could predict eventual progression, or regression with treatment, which could have some prognostic clinical value in ocular diabetic disease. More consistent data will be surely available, in the near future with the advances in OCT technology such as OCT-Angiography.

6 — We are the first, to our knowledge, presenting a longitudinal study in Diabetic choroidopathy using OCT images, where we were able to find that morphological changes in choroid occur related to the progression of the subjacent diabetic retinopathy.

REFERENCES

REFERENCES

1. Cho NH, Shaw JE, Karuranga S, et al. IDF Diabetes Atlas: Global estimates of diabetes prevalence for 2017 and projections for 2045. *Diabetes Res Clin Pract.* 2018;138:271-281. doi:10.1016/j.diabres.2018.02.023
2. WHO | Diabetes programme. WHO. 2018. <http://www.who.int/diabetes/en/>. Accessed May 8, 2018.
3. Fowler MJ. Microvascular and Macrovascular Complications of Diabetes. *Clin Diabetes @BULLET.* 2008;26(2). <http://clinical.diabetesjournals.org/content/26/2/77.full-text.pdf>. Accessed May 9, 2018.
4. Bourne RRA, Stevens GA, White RA, et al. Causes of vision loss worldwide, 1990-2010: a systematic analysis. *Lancet Glob Heal.* 2013;1:e339-e349. doi:10.1016/S2214-109X(13)70113-X
5. Yau JWY, Rogers SL, Kawasaki R, et al. Global Prevalence and Major Risk Factors of Diabetic Retinopathy. *Diabetes Care.* 2012;35(3):556-564. doi:10.2337/dc11-1909
6. Wolfensberger TJ, Hamilton AM. Diabetic retinopathy--an historical review. *Semin Ophthalmol.* 2001;16(1):2-7. <http://www.ncbi.nlm.nih.gov/pubmed/15487691>. Accessed May 9, 2018.
7. Wessing A. Diabetic retinopathy: update on diagnosis and treatment. *Nephrol Dial Transpl.* 1997;12:2013-2018. <http://citeseerx.ist.psu.edu/viewdoc/download?doi=10.1.1.564.5693&rep=rep1&type=pdf>. Accessed May 9, 2018.
8. Jaeger E. *Beitrage Zur Pathologie Des Auges.* Wien; 1856.
9. Ballantyne, AJ; Loewenstein A. The pathology of diabetic retinopathy. *Trans Ophthalmol Soc U K.* 1943;63:95.
10. ASHTON N. Vascular changes in diabetes with particular reference to the retinal vessels; preliminary report. *Br J Ophthalmol.* 1949;33(7):407-420. <http://www.ncbi.nlm.nih.gov/pubmed/18152811>. Accessed May 9, 2018.
11. COGAN DG, TOUSSAINT D, KUWABARA T. Retinal vascular patterns. IV. Diabetic retinopathy. *Arch Ophthalmol (Chicago, Ill 1960).* 1961;66:366-378. <http://www.ncbi.nlm.nih.gov/pubmed/13694291>. Accessed May 9, 2018.

12. Alvis DL, Julian KG. The Story Surrounding Fluorescein Angiography. *J Ophthalmic Photogr.* 1982;5(1):6-8. <https://c.ymcdn.com/sites/www.opsweb.org/resource/resmgr/history/05-1-02.pdf>. Accessed May 9, 2018.
13. Same PJ. Landmarks in the historical development of fluorescein angiography. *J Ophthalmic Photogr.* 1993;15(1):17-23. <https://c.ymcdn.com/sites/www.opsweb.org/resource/resmgr/history/15-1-04.pdf>. Accessed May 9, 2018.
14. Huang D, Swanson EA, Lin CP, et al. Optical coherence tomography. *Science.* 1991;254(5035):1178-1181. <http://www.ncbi.nlm.nih.gov/pubmed/1957169>. Accessed May 9, 2018.
15. Fujimoto J, Swanson E. The Development, Commercialization, and Impact of Optical Coherence Tomography. *Invest Ophthalmol Vis Sci.* 2016;57(9):OCT1-OCT13. doi:10.1167/iovs.16-19963
16. Gabriele ML, Wollstein G, Ishikawa H, et al. Optical coherence tomography: history, current status, and laboratory work. *Invest Ophthalmol Vis Sci.* 2011;52(5):2425-2436. doi:10.1167/iovs.10-6312
17. Spaide RF, Koizumi H, Pozonni MC. Enhanced Depth Imaging Spectral-Domain Optical Coherence Tomography. *Am J Ophthalmol.* 2008;146(4):496-500. doi:10.1016/j.ajo.2008.05.032
18. Margolis R, Spaide RF. A Pilot Study of Enhanced Depth Imaging Optical Coherence Tomography of the Choroid in Normal Eyes. *Am J Ophthalmol.* 2009;147(5):811-815. doi:10.1016/j.ajo.2008.12.008
19. Kannel WB. Diabetes and Cardiovascular Disease. *JAMA.* 1979;241(19):2035. doi:10.1001/jama.1979.03290450033020
20. Laing SP, Swerdlow AJ, Slater SD, et al. Mortality from heart disease in a cohort of 23,000 patients with insulin-treated diabetes. *Diabetologia.* 2003;46(6):760-765. doi:10.1007/s00125-003-1116-6
21. Paterson AD, Rutledge BN, Cleary PA, Lachin JM, Crow RS, Diabetes Control and Complications Trial/Epidemiology of Diabetes Interventions and Complications Research Group. The Effect of Intensive Diabetes Treatment on Resting Heart Rate in Type 1 Diabetes: The Diabetes Control and Complications Trial/Epidemiology of Diabetes Interventions and Complications Study. *Diabetes Care.* 2007;30(8):2107-2112. doi:10.2337/dc06-1441

22. Tight blood pressure control and risk of macrovascular and microvascular complications in type 2 diabetes: UKPDS 38. UK Prospective Diabetes Study Group. *BMJ.* 1998;317(7160):703-713. <http://www.ncbi.nlm.nih.gov/pubmed/9732337>. Accessed May 13, 2018.
23. Lehto S, Rönnemaa T, Pyörälä K, Laakso M. Predictors of stroke in middle-aged patients with non-insulin-dependent diabetes. *Stroke.* 1996;27(1):63-68. <http://www.ncbi.nlm.nih.gov/pubmed/8553405>. Accessed May 13, 2018.
24. Almdal T, Scharling H, Jensen JS, Vestergaard H. The independent effect of type 2 diabetes mellitus on ischemic heart disease, stroke, and death: a population-based study of 13,000 men and women with 20 years of follow-up. *Arch Intern Med.* 2004;164(13):1422-1426. doi:10.1001/archinte.164.13.1422
25. Efficacy of atenolol and captopril in reducing risk of macrovascular and microvascular complications in type 2 diabetes: UKPDS 39. UK Prospective Diabetes Study Group. *BMJ.* 1998;317(7160):713-720. <http://www.ncbi.nlm.nih.gov/pubmed/9732338>. Accessed May 13, 2018.
26. Nathan DM, Cleary PA, Backlund J-YC, et al. Intensive Diabetes Treatment and Cardiovascular Disease in Patients with Type 1 Diabetes. *N Engl J Med.* 2005;353(25):2643-2653. doi:10.1056/NEJMoa052187
27. Barrett EJ, Liu Z, Khamaisi M, et al. Diabetic Microvascular Disease: An Endocrine Society Scientific Statement. *J Clin Endocrinol Metab.* 2017;102(12):4343-4410. doi:10.1210/jc.2017-01922
28. Effect of intensive blood-glucose control with metformin on complications in overweight patients with type 2 diabetes (UKPDS 34). UK Prospective Diabetes Study (UKPDS) Group. *Lancet (London, England).* 1998;352(9131):854-865. <http://www.ncbi.nlm.nih.gov/pubmed/9742977>. Accessed May 17, 2018.
29. Diabetes Control and Complications Trial Research Group, Nathan DM, Genuth S, et al. The Effect of Intensive Treatment of Diabetes on the Development and Progression of Long-Term Complications in Insulin-Dependent Diabetes Mellitus. *N Engl J Med.* 1993;329(14):977-986. doi:10.1056/NEJM199309303291401
30. Pinazo-Durán MD, Zanón-Moreno V, Lleó-Perez A, et al. Genetic systems for a new approach to risk of progression of diabetic retinopathy. *Arch Soc Esp Oftalmol.* 2016;91(5). doi:10.1016/j.oftal.2016.01.016

31. Pinazo-Durán MD, Shoaie-Nia K, Sanz-González SM, et al. Identification of new candidate genes for retinopathy in type 2 diabetics. Valencia Study on Diabetic Retinopathy (VSDR). Report number 3. *Arch Soc Esp Ophthalmol*. 2018. doi:10.1016/j.oftal.2017.12.016
32. Petrovič D. Candidate Genes for Proliferative Diabetic Retinopathy. *Biomed Res Int*. 2013;2013:1-9. doi:10.1155/2013/540416
33. Kowluru RA, Chan P-S. Oxidative stress and diabetic retinopathy. *Exp Diabetes Res*. 2007;2007:43603. doi:10.1155/2007/43603
34. Wan T-T, Li X-F, Sun Y-M, Li Y-B, Su Y. Recent advances in understanding the biochemical and molecular mechanism of diabetic retinopathy. *Biomed Pharmacother*. 2015;74:145-147. doi:10.1016/j.biopha.2015.08.002
35. Goldberg MF, Jampol LM. Knowledge of diabetic retinopathy before and 18 years after the Airlie House Symposium on Treatment of Diabetic Retinopathy. *Ophthalmology*. 1987;94(7):741-746. <http://www.ncbi.nlm.nih.gov/pubmed/2889177>. Accessed May 17, 2018.
36. Diabetic retinopathy study. Report Number 6. Design, methods, and baseline results. Report Number 7. A modification of the Airlie House classification of diabetic retinopathy. Prepared by the Diabetic Retinopathy. *Invest Ophthalmol Vis Sci*. 1981;21(1 Pt 2):1-226. <http://www.ncbi.nlm.nih.gov/pubmed/7195893>. Accessed May 17, 2018.
37. Grading diabetic retinopathy from stereoscopic color fundus photographs--an extension of the modified Airlie House classification. ETDRS report number 10. Early Treatment Diabetic Retinopathy Study Research Group. *Ophthalmology*. 1991;98(5 Suppl):786-806. <http://www.ncbi.nlm.nih.gov/pubmed/2062513>. Accessed May 17, 2018.
38. Wilkinson CP, Ferris FL, Klein RE, et al. Proposed international clinical diabetic retinopathy and diabetic macular edema disease severity scales. *Ophthalmology*. 2003;110(9):1677-1682. doi:10.1016/S0161-6420(03)00475-5
39. Klein R, Myers CE, Lee KE, Gangnon R, Klein BEK. Changes in retinal vessel diameter and incidence and progression of diabetic retinopathy. *Arch Ophthalmol (Chicago, Ill 1960)*. 2012;130(6):749-755. doi:10.1001/archophthalmol.2011.2560
40. Cheung CY, Ikram MK, Klein R, Wong TY. The clinical implications of recent studies on the structure and function of the retinal microvasculature in diabetes. *Diabetologia*. 2015;58(5):871-885. doi:10.1007/s00125-015-3511-1

41. Nunes S, Pires I, Rosa A, Duarte L, Bernardes R, Cunha-Vaz J. Microaneurysm turnover is a biomarker for diabetic retinopathy progression to clinically significant macular edema: Findings for type 2 diabetics with nonproliferative retinopathy. *Ophthalmologica*. 2009;223(5):292-297. doi:10.1159/000213639
42. Pappuru RKR, Ribeiro L, Lobo C, Alves D, Cunha-Vaz J. Microaneurysm turnover is a predictor of diabetic retinopathy progression. *Br J Ophthalmol*. April 2018:bjophthalmol-2018-311887. doi:10.1136/bjophthalmol-2018-311887
43. Hellstedt T, Immonen I. Disappearance and formation rates of microaneurysms in early diabetic retinopathy. *Br J Ophthalmol*. 1996;80(2):135-139. <http://www.ncbi.nlm.nih.gov/pubmed/8814743>. Accessed May 17, 2018.
44. Kohner EM, Stratton IM, Aldington SJ, Turner RC, Matthews DR. Microaneurysms in the development of diabetic retinopathy (UKPDS 42). UK Prospective Diabetes Study Group. *Diabetologia*. 1999;42(9):1107-1112. <http://www.ncbi.nlm.nih.gov/pubmed/10447523>. Accessed May 17, 2018.
45. Haritoglou C, Kernt M, Neubauer A, et al. Microaneurysm formation rate as a predictive marker for progression to clinically significant macular edema in nonproliferative diabetic retinopathy. *Retina*. 2014;34(1):157-164. doi:10.1097/IAE.0b013e318295f6de
46. Ribeiro ML, Nunes SG, Cunha-Vaz JG. Microaneurysm turnover at the macula predicts risk of development of clinically significant macular edema in persons with mild nonproliferative diabetic retinopathy. *Diabetes Care*. 2013;36(5):1254-1259. doi:10.2337/dc12-1491
47. Nunes S, Ribeiro L. Three Different Phenotypes of Mild Nonproliferative Diabetic Retinopathy With Different Risks for Development of Clinically Significant Macular Edema. *Investig Ophthalmology Vis Sci*. 2016;54(7):4595-4604. doi:10.1167/iovs.13-11895
48. Cunha-Vaz J, Ribeiro L, Lobo C. Phenotypes and biomarkers of diabetic retinopathy. *Prog Retin Eye Res*. 2014;41:90-111. doi:10.1016/j.preteyeres.2014.03.003
49. Cunha-Vaz J. Characterization and Relevance of Different Diabetic Retinopathy Phenotypes. In: *Diabetic Retinopathy*. Vol 39. Basel: KARGER; 2007:13-30. doi:10.1159/000098497

50. Stem MS, Gardner TW. Neurodegeneration in the pathogenesis of diabetic retinopathy: molecular mechanisms and therapeutic implications. *Curr Med Chem*. 2013;20(26):3241-3250. <http://www.ncbi.nlm.nih.gov/pubmed/23745549>. Accessed May 17, 2018.
51. Simó R, Hernández C, European Consortium for the Early Treatment of Diabetic Retinopathy (EUROCONDOR). Neurodegeneration in the diabetic eye: new insights and therapeutic perspectives. *Trends Endocrinol Metab*. 2014;25(1):23-33. doi:10.1016/j.tem.2013.09.005
52. Villarroel M, Ciudin A, Hernández C, Simó R. Neurodegeneration: An early event of diabetic retinopathy. *World J Diabetes*. 2010;1(2):57-64. doi:10.4239/wjd.v1.i2.57
53. Wang N-L. Neurodegeneration in Diabetic Retinopathy: Current Concepts and Therapeutic Implications. *Chin Med J (Engl)*. 2016;129(24):3001-3003. doi:10.4103/0366-6999.195478
54. Lynch SK, Abramoff MD. Diabetic retinopathy is a neurodegenerative disorder. *Vision Res*. 2017;139:101-107. doi:10.1016/j.visres.2017.03.003
55. ACCORD Study Group, ACCORD Eye Study Group, Chew EY, et al. Effects of Medical Therapies on Retinopathy Progression in Type 2 Diabetes. *N Engl J Med*. 2010;363(3):233-244. doi:10.1056/NEJMoa1001288
56. Guyer DR, Schachat AP, Green WR. The Choroid: Structural Considerations. In: Ryan, Stephen J.; Hinton, David R.; Schachat AP, ed. *Retina*. 4th ed. Elsevier; 2006:33-42.
57. Ramrattan RS, van der Schaft TL, Mooy CM, de Bruijn WC, Mulder PG, de Jong PT. Morphometric analysis of Bruch's membrane, the choriocapillaris, and the choroid in aging. *Invest Ophthalmol Vis Sci*. 1994;35(6):2857-2864. <http://www.ncbi.nlm.nih.gov/pubmed/8188481>. Accessed May 22, 2018.
58. Nussenblatt RB. Elements of the Immune System and Concepts of Intraocular Inflammatory Disease Pathogenesis. In: *Uveitis*. Elsevier; 2010:1-36. doi:10.1016/B978-1-4377-0667-3.00006-0
59. Cholkar K, Dasari SR, Pal D, Mitra AK. Eye: anatomy, physiology and barriers to drug delivery. In: *Ocular Transporters and Receptors*. Elsevier; 2013:1-36. doi:10.1533/9781908818317.1
60. Zhang Y, Wildsoet CF. RPE and Choroid Mechanisms Underlying Ocular Growth and Myopia. *Prog Mol Biol Transl Sci*. 2015;134:221-240. doi:10.1016/BS.PMBTS.2015.06.014

61. Yoneya S, Tso MOM, Shimizu K. Patterns of the choriocapillaris - A method to study the choroidal vasculature of the enucleated human eye. *Int Ophthalmol.* 1983;6(2):95-99. doi:10.1007/BF00127637
62. Torczynski E, Tso MOM. The architecture of the choriocapillaris at the posterior pole. *Am J Ophthalmol.* 1976;81(4):428-440. doi:10.1016/0002-9394(76)90298-1
63. Zouache MA, Eames I, Klettner CA, Luthert PJ. Form, shape and function: Segmented blood flow in the choriocapillaris. *Sci Rep.* 2016;6(1):35754. doi:10.1038/srep35754
64. Hogan MJ, Alvarado JA, Weddell JE. *Histology of the Human Eye: An Atlas and Textbook [by] Michael J. Hogan, Jorge A. Alvarado [and] Joan Esperson Weddell.* Saunders; 1971. https://books.google.com/books/about/Histology_of_the_human_eye.html?id=29JqAAAAAAJ&pgis=1. Accessed May 22, 2018.
65. Wajer SD, Taomoto M, McLeod DS, et al. Velocity Measurements of Normal and Sickle Red Blood Cells in the Rat Retinal and Choroidal Vasculatures. *Microvasc Res.* 2000;60(3):281-293. doi:10.1006/mvre.2000.2270
66. Nickla DL, Wallman J. The multifunctional choroid. *Prog Retin Eye Res.* 2010;29(2):144-168. doi:10.1016/j.preteyeres.2009.12.002
67. Wallman J, Wildsoet C, Xu A, et al. Moving the retina: choroidal modulation of refractive state. *Vision Res.* 1995;35(1):37-50. <http://www.ncbi.nlm.nih.gov/pubmed/7839608>. Accessed May 23, 2018.
68. Remington LA, Remington LA. Uvea. In: *Clinical Anatomy and Physiology of the Visual System.* Elsevier; 2012:40-60. doi:10.1016/B978-1-4377-1926-0.10003-7
69. Saracco JB, Gastaud P, Ridings B, Ubaud CA. [Diabetic choroidopathy (author's transl)]. *J Fr d'ophtalmologie.* 1982;5(4):231-236. <http://www.ncbi.nlm.nih.gov/pubmed/7108132>. Accessed May 23, 2018.
70. Hidayat AA, Fine BS. Diabetic choroidopathy. Light and electron microscopic observations of seven cases. *Ophthalmology.* 1985;92(4):512-522. doi:10.1016/S0161-6420(85)34013-7
71. Fryczkowski AW, Sato SE, Hodes BL. Changes in the diabetic choroidal vasculature: scanning electron microscopy findings. *Ann Ophthalmol.* 1988;20(8):299-305. <http://www.ncbi.nlm.nih.gov/pubmed/3190107>. Accessed July 3, 2017.

72. Cao J, McLeod S, Merges CA, Luttly GA. Choriocapillaris degeneration and related pathologic changes in human diabetic eyes. *Arch Ophthalmol*. 1998;116(5):589-597. doi:10.1001/archopht.116.5.589
73. Luttly GA. Effects of diabetes on the eye. *Investig Ophthalmol Vis Sci*. 2013;54(14):81-87. doi:10.1167/iovs.13-12979
74. Dimitrova G, Kato S, Tamaki Y, et al. Choroidal circulation in diabetic patients. *Eye (Lond)*. 2001;15(Pt 5):602-607. doi:10.1038/eye.2001.193
75. Nagaoka T, Kitaya N, Sugawara R, et al. Alteration of choroidal circulation in the foveal region in patients with type 2 diabetes. *Br J Ophthalmol*. 2004;88(8):1060-1063. doi:10.1136/bjo.2003.035345
76. Pemp B, Schmetterer L. Ocular blood flow in diabetes and age-related macular degeneration. *Can J Ophthalmol*. 2008;43(3):295-301. doi:10.3129/i08-049
77. Shiragami C, Shiraga F, Matsuo T, Tsuchida Y, Ohtsuki H. Risk factors for diabetic choroidopathy in patients with diabetic retinopathy. *Graefe's Arch Clin Exp Ophthalmol*. 2002;240(6):436-442. doi:10.1007/s00417-002-0451-5
78. Hua R, Liu L, Wang X, Chen L. Imaging evidence of diabetic choroidopathy in vivo: Angiographic pathoanatomy and choroidal-enhanced depth imaging. *PLoS One*. 2013;8(12):e83494. doi:10.1371/journal.pone.0083494
79. Swanson EA, Izatt JA, Lin CP, et al. In vivo retinal imaging by optical coherence tomography. *Opt Lett*. 1993;18(21):1864. doi:10.1364/OL.18.001864
80. Fujimoto JG, Pitris C, Boppart SA, Brezinski ME. Optical coherence tomography: an emerging technology for biomedical imaging and optical biopsy. *Neoplasia*. 2000;2(1-2):9-25. <http://www.ncbi.nlm.nih.gov/pubmed/10933065>. Accessed May 24, 2018.
81. Regatieri C V, Branchini L a, Fujimoto JG, Duker JS. Choroidal imaging using spectral-domain optical coherence tomography. *Retina*. 2012;32(5):865-876. doi:10.1097/IAE.0b013e318251a3a8.CHOROIDAL
82. Laviers H, Zambarakji H. Enhanced depth imaging-OCT of the choroid: a review of the current literature. *Graefe's Arch Clin Exp Ophthalmol*. 2014;252(12):1871-1883. doi:10.1007/s00417-014-2840-y
83. Chhablani J, Wong IY, Kozak I. Choroidal imaging: A review. *Saudi J Ophthalmol*. 2014;28(2):123-128. doi:10.1016/j.sjopt.2014.03.004

84. Mrejen S, Spaide RF. Optical coherence tomography: Imaging of the choroid and beyond. *Surv Ophthalmol.* 2013;58(5):387-429. doi:10.1016/j.survophthal.2012.12.001
85. Ikuno Y, Maruko I, Yasuno Y, et al. Reproducibility of retinal and choroidal thickness measurements in enhanced depth imaging and high-penetration optical coherence tomography. *Investig Ophthalmol Vis Sci.* 2011;52(8):5536-5540. doi:10.1167/iovs.10-6811
86. Rahman W, Chen FK, Yeoh J, Patel P, Tufail A, Da Cruz L. Repeatability of manual subfoveal choroidal thickness measurements in healthy subjects using the technique of enhanced depth imaging optical coherence tomography. *Investig Ophthalmol Vis Sci.* 2011;52(5):2267-2271. doi:10.1167/iovs.10-6024
87. Lauren Branchini, Caio V. Regatieri, Ignacio Flores-Moreno BB, James G. Fujimoto JSD. Reproducibility of Choroidal Thickness Measurements Across Three Spectral Domain Optical Coherence Tomography Systems. *Ophthalmology.* 2013;119(1):119-123. doi:10.1016/j.ophtha.2011.07.002.Reproducibility
88. Chen W, Wang ZT, Zhang H. Comparison of choroidal thickness measured by two methods. *Int J Ophthalmol.* 2012;5(3):348-353. doi:10.3980/j.issn.2222-3959.2012.03.19
89. Chhablani J, Barteselli G, Wang H, et al. Repeatability and Reproducibility of Manual Choroidal Volume Measurements Using Enhanced Depth Imaging Optical Coherence Tomography. *Invest Ophthalmol Vis Sci.* 2012;53(4):2274. doi:10.1167/IOVS.12-9435
90. Yamashita T, Yamashita T, Shirasawa M, Arimura N, Terasaki H, Sakamoto T. Repeatability and reproducibility of subfoveal choroidal thickness in normal eyes of Japanese using different SD-OCT devices. *Investig Ophthalmol Vis Sci.* 2012;53(3):1102-1107. doi:10.1167/iovs.11-8836
91. Matsuo Y, Sakamoto T, Yamashita T, Tomita M, Shirasawa M, Terasaki H. Comparisons of choroidal thickness of normal eyes obtained by two different spectral-domain OCT instruments and one swept-source OCT instrument. *Investig Ophthalmol Vis Sci.* 2013;54(12):7630-7636. doi:10.1167/iovs.13-13135
92. Cho AR, Choi YJ, Kim YT, Medscape. Influence of choroidal thickness on subfoveal choroidal thickness measurement repeatability using enhanced depth imaging optical coherence tomography. *Eye (Lond).* 2014;28(10):1151-1160. doi:10.1038/eye.2014.197

93. Copete S, Flores-Moreno I, Montero J a, Duker JS, Ruiz-Moreno JM. Direct comparison of spectral-domain and swept-source OCT in the measurement of choroidal thickness in normal eyes. *Br J Ophthalmol*. 2014;98(3):334-338. doi:10.1136/bjophthalmol-2013-303904
94. Read S a., Collins MJ, Vincent SJ, Alonso-Caneiro D. Choroidal thickness in childhood. *Invest Ophthalmol Vis Sci*. 2013;54(5):3586-3593. doi:10.1167/iovs.13-11732
95. Sanchez-Cano A, Orduna E, Segura F, et al. Choroidal Thickness And Volume In Healthy Young Whites And Their Relationship With Axial Length, Ammetropy And Sex. *Am J Ophthalmol*. 2014;i(3):574-83.e1. doi:10.1016/j.ajo.2014.05.035
96. Pappuru R, Chhablani J, Kumar U, et al. Choroidal thickness profi le in healthy Indian subjects. *Indian J Ophthalmol*. 2014;62(11):1060. doi:10.4103/0301-4738.146711
97. Varsha Manjunath Mohammad Taha, James G. Fujimoto and JSD. Choroidal Thickness in Normal Eyes Measured Using Cirrus-HD Optical Coherence Tomography. *Am J Ophthalmol*. 2010;150(3):325-329. doi:10.1016/j.ajo.2010.04.018.Choroidal
98. Ikuno Y, Kawaguchi K, Nouchi T, Yasuno Y. Choroidal Thickness in Healthy Japanese Subjects. 2010;51:2173-2176. doi:10.1167/iovs.09-4383
99. Hirata M, Tsujikawa A, Matsumoto A, et al. Macular choroidal thickness and volume in normal subjects measured by swept-source optical coherence tomography. *Invest Ophthalmol Vis Sci*. 2011;52(8):4971-4978. doi:10.1167/iovs.11-7729
100. Ding X, Li J, Zeng J, et al. Choroidal thickness in healthy Chinese subjects. *Investig Ophthalmol Vis Sci*. 2011;52(13):9555-9560. doi:10.1167/iovs.11-8076
101. Ouyang Y, Heussen FM, Mokwa N, et al. Spatial distribution of posterior pole choroidal thickness by spectral domain optical coherence tomography. *Investig Ophthalmol Vis Sci*. 2011;52(9):7019-7026. doi:10.1167/iovs.11-8046
102. Huang J, Savini G, Chen S, Feng Y, Wang Q. Choroidal thickness measurements. *Ophthalmology*. 2012;119(6):1286. doi:10.1016/j.ophtha.2012.02.026

103. Shin JW, Shin YU, Cho HY, Lee BR. Measurement of choroidal thickness in normal eyes using 3D OCT-1000 spectral domain optical coherence tomography. *Korean J Ophthalmol.* 2012;26(4):255-259. doi:10.3341/kjo.2012.26.4.255
104. Wei W Bin, Xu L, Jonas JB, et al. Subfoveal choroidal thickness: The Beijing Eye Study. *Ophthalmology.* 2013;120(1):175-180. doi:10.1016/j.ophtha.2012.07.048
105. Kahn KN, McKibbin M, Kahn RS. Variability in subfoveal choroidal thickness measurements. *Invest Ophthalmol Vis Sci.* 2011;52(10):7221; author reply 7221. doi:10.1167/iops.11-8019
106. Tan CSH, Cheong KX, Lim LW, Li KZ. Topographic variation of choroidal and retinal thicknesses at the macula in healthy adults. *Br J Ophthalmol.* 2014;98(3):339-344. doi:10.1136/bjophthalmol-2013-304000
107. Barteselli G, Chhablani J, El-Emam S, et al. Choroidal volume variations with age, axial length, and sex in healthy subjects: A three-dimensional analysis. *Ophthalmology.* 2012;119(12):2572-2578. doi:10.1016/j.ophtha.2012.06.065
108. Chen FK, Yeoh J, Rahman W, Patel PJ, Tufail A, da Cruz L. Topographic variation and interocular symmetry of macular choroidal thickness using enhanced depth imaging optical coherence tomography. *Investig Ophthalmol Vis Sci.* 2012;53(2):975-985. doi:10.1167/iops.11-8771
109. Noori J, Esfahani MR, Hajizadeh F, Zaferani MM. Choroidal mapping; a novel approach for evaluating choroidal thickness and volume. *J Ophthalmic Vis Res.* 2012;7(2):180-185.
110. Nagasawa T, Mitamura Y, Katome T, et al. Macular choroidal thickness and volume in healthy pediatric individuals measured by swept-source optical coherence tomography. *Invest Ophthalmol Vis Sci.* 2013;54(10):7068-7074. doi:10.1167/iops.13-12350
111. Michalewski J, Michalewska Z, Nawrocka Z, Bednarski M, Nawrocki J. Correlation of choroidal thickness and volume measurements with axial length and age using swept source optical coherence tomography and optical low-coherence reflectometry. *Biomed Res Int.* 2014;2014:639160. doi:10.1155/2014/639160
112. Tan CSH, Cheong KX. Macular choroidal thicknesses in healthy adults-relationship with ocular and demographic factors. *Investig Ophthalmol Vis Sci.* 2014;55(10):6452-6458. doi:10.1167/iops.13-13771

113. Ruiz-Medrano J, Flores-Moreno I, Peña-García P, Montero JA, Duker JS, Ruiz-Moreno JM. Macular Choroidal Thickness Profile in a Healthy Population Measured by Swept-Source Optical Coherence Tomography. *Investig Ophthalmology Vis Sci*. 2014;55(6):3532. doi:10.1167/iovs.14-13868
114. Brown JS, Flitcroft DI, Ying GS, et al. In vivo human choroidal thickness measurements: Evidence for diurnal fluctuations. *Investig Ophthalmol Vis Sci*. 2009;50(1):5-12. doi:10.1167/iovs.08-1779
115. Usui S, Ikuno Y, Akiba M, et al. Circadian changes in subfoveal choroidal thickness and the relationship with circulatory factors in healthy subjects. *Invest Ophthalmol Vis Sci*. 2012;53(4):2300-2307. doi:10.1167/iovs.11-8383
116. Tan CS, Ouyang Y, Ruiz H, Sadda SR. Diurnal Variation of Choroidal Thickness in Normal, Healthy Subjects Measured by Spectral Domain Optical Coherence Tomography. *Investig Ophthalmology Vis Sci*. 2012;53(1):261. doi:10.1167/iovs.11-8782
117. Osmanbasoglu OA, Alkin Z, Ozkaya A, Ozpinar Y, Yazici AT, Demirok A. Diurnal choroidal thickness changes in normal eyes of Turkish people measured by spectral domain optical coherence tomography. *J Ophthalmol*. 2013;2013:687165. doi:10.1155/2013/687165
118. Mansouri K, Medeiros F a., Marchase N, Tatham AJ, Auerbach D, Weinreb RN. Assessment of choroidal thickness and volume during the water drinking test by swept-source optical coherence tomography. *Ophthalmology*. 2013;120(12):2508-2516. doi:10.1016/j.ophtha.2013.07.040
119. Aksoy Y, Çolakoglu K, Kar T, Sevinc MK, Eyi YE. Choroidal Thickness Is Affected by More Factors Than Estimated. *Investig Ophthalmology Vis Sci*. 2014;55(3):1311. doi:10.1167/iovs.13-13820
120. Motaghiannezam R, Schwartz DM, Fraser SE. In vivo human choroidal vascular pattern visualization using high-speed swept-source optical coherence tomography at 1060 nm. *Investig Ophthalmol Vis Sci*. 2012;53(4):2337-2343. doi:10.1167/iovs.11-7823
121. Zhang L, Lee K, Niemeijer M, Mullins RF, Sonka M, Abramoff MD. Automated segmentation of the choroid from clinical SD-OCT. *Investig Ophthalmol Vis Sci*. 2012;53(12):7510-7519. doi:10.1167/iovs.12-10311
122. Tian J, Marziliano P, Baskaran M, Tun T a, Aung T. Automatic segmentation of the choroid in enhanced depth imaging optical coherence tomography images. *Biomed Opt Express*. 2013;4(3):397-411. doi:10.1364/BOE.4.000397

123. Branchini LA, Adhi M, Regatieri C V, et al. Analysis of Choroidal Morphology and Vasculature in Healthy Eyes Using Spectral-Domain Optical Coherence Tomography. *Ophthalmology*. 2014;120(9):1901-1908. doi:10.1016/j.ophtha.2013.01.066.Analysis
124. Yiu G, Pecen P, Sarin N, et al. Characterization of the choroid-scleral junction and suprachoroidal layer in healthy individuals on enhanced-depth imaging optical coherence tomography. *JAMA Ophthalmol*. 2014;132(2):174-181. doi:10.1001/jamaophthalmol.2013.7288
125. Kajić V, Esmaeelpour M, Glittenberg C, et al. Automated three-dimensional choroidal vessel segmentation of 3D 1060 nm OCT retinal data. *Biomed Opt Express*. 2013;4(1):134. doi:10.1364/BOE.4.000134
126. Esmaeelpour M, Kajić V, Zabihiyan B, et al. Choroidal Haller's and Sattler's layer thickness measurement using 3-dimensional 1060-nm optical coherence tomography. *PLoS One*. 2014;9(6):e99690. doi:10.1371/journal.pone.0099690
127. Branchini LA, Adhi M, Regatieri C V, et al. Analysis of choroidal morphologic features and vasculature in healthy eyes using spectral-domain optical coherence tomography. *Ophthalmology*. 2013;120(9):1901-1908. doi:10.1016/j.ophtha.2013.01.066
128. Esmaeelpour M, Považay B, Hermann B, et al. Mapping choroidal and retinal thickness variation in type 2 diabetes using three-dimensional 1060-nm optical coherence tomography. *Invest Ophthalmol Vis Sci*. 2011;52(8):5311-5316. doi:10.1167/iovs.10-6875
129. Esmaeelpour M, Brunner S, Ansari-Shahrezaei S, et al. Choroidal thinning in diabetes type 1 detected by 3- dimensional 1060 nm optical coherence tomography. *Investig Ophthalmol Vis Sci*. 2012;53(11):6803-6809. doi:10.1167/iovs.12-10314
130. Unsal E, Eltutar K, Zirtiloğlu S, Dinçer N, Ozdoğan Erkul S, Güngel H. Choroidal thickness in patients with diabetic retinopathy. *Clin Ophthalmol*. 2014;8:637-642. doi:10.2147/OPHTH.S59395
131. Vujosevic S, Martini F, Cavarzeran F, Pilotto E, Midena E. Macular and Peripapillary Choroidal Thickness in Diabetic Patients. *Retina*. 2012;1. doi:10.1097/IAE.0b013e31825db73d
132. Lee HK, Lim JW, Shin MC. Comparison of Choroidal Thickness in Patients with Diabetes by Spectral-domain Optical Coherence Tomography. *Korean J Ophthalmol*. 2013;27(6):1011-8942. doi:10.3341/kjo.2013.27.6.433

133. Gerendas BS, Waldstein SM, Simader C, et al. Three-dimensional automated choroidal volume assessment on standard spectral-domain optical coherence tomography and correlation with the level of diabetic macular edema. *Am J Ophthalmol.* 2014;158(5):1039-1048. doi:10.1016/j.ajo.2014.08.001
134. Sayin N, Kara N, Pirhan D, et al. Evaluation of subfoveal choroidal thickness in children with type 1 diabetes mellitus: an EDI-OCT study. *Semin Ophthalmol.* 2014;29(1):27-31. doi:10.3109/08820538.2013.838279
135. Yülek F, Uğurlu N, Önal ED, et al. Choroidal changes and duration of diabetes. *Semin Ophthalmol.* 2014;29(2):80-84. doi:10.3109/08820538.2013.821504
136. Farias LB, Lavinsky D, Schneider WM, Guimarães L, Lavinsky J, Canani LH. Choroidal thickness in patients with diabetes and microalbuminuria. *Ophthalmology.* 2014;121(10):2071-2073. doi:10.1016/j.ophtha.2014.04.038
137. Jo Y, Ikuno Y, Iwamoto R, Okita K, Nishida K. Choroidal thickness changes after diabetes type 2 and blood pressure control in a hospitalized situation. *Retina.* 2014;34(6):1190-1198. doi:10.1097/IAE.0000000000000051
138. Kim JT, Lee DH, Joe SG, Kim JG, Yoon YH. Changes in choroidal thickness in relation to the severity of retinopathy and macular edema in type 2 diabetic patients. *Investig Ophthalmol Vis Sci.* 2013;54(5):3378-3384. doi:10.1167/iavs.12-11503
139. Xu J, Xu L, Du KF, et al. Subfoveal choroidal thickness in diabetes and diabetic retinopathy. *Ophthalmology.* 2013;120(10):2023-2028. doi:10.1016/j.ophtha.2013.03.009
140. Regatieri C V, Branchini L a, Fujimoto JG, Duker JS. Choroidal imaging using spectral-domain optical coherence tomography. *Retina.* 2012;32(5):865-876. doi:10.1097/IAE.0b013e318251a3a8.CHOROIDAL
141. Lee JY, Lee DH, Lee JY, Yoon YH. Correlation between subfoveal choroidal thickness and the severity or progression of nonexudative age-related macular degeneration. *Invest Ophthalmol Vis Sci.* 2013;54(12):7812-7818. doi:10.1167/iavs.13-12284
142. Querques G, Lattanzio R, Querques L, et al. Enhanced depth imaging optical coherence tomography in type 2 diabetes. *Invest Ophthalmol Vis Sci.* 2012;53(10):6017-6024. doi:10.1167/iavs.12-9692

143. Adhi M, Brewer E, Waheed NK, Duker JS. Analysis of morphological features and vascular layers of choroid in diabetic retinopathy using spectral-domain optical coherence tomography. *JAMA Ophthalmol.* 2013;131(10):1267-1274. doi:10.1001/jamaophthalmol.2013.4321
144. Toyoda F, Tanaka Y, Shimmura M, Kinoshita N, Takano H, Kakehashi A. Diabetic retinal and choroidal edema in SDT rats. *J Diabetes Res.* 2016;2016:2345141. doi:10.1155/2016/2345141
145. Cunha-Vaz JG. The blood-retinal barriers. *Doc Ophthalmol.* 1976;41(2):287-327. <http://www.ncbi.nlm.nih.gov/pubmed/1009819>. Accessed July 3, 2017.
146. Luty GA, McLeod DS. Phosphatase enzyme histochemistry for studying vascular hierarchy, pathology, and endothelial cell dysfunction in retina and choroid. In: *Vision Research.* Vol 45. ; 2005:3504-3511. doi:10.1016/j.visres.2005.08.022
147. Johnson RN, McDonald HR, Ai E, Jumper JM, Fu AD. Chapter 51 – Fluorescein Angiography: Basic Principles and Interpretation. In: *Retina.* ; 2006:873-916. doi:10.1016/B978-0-323-02598-0.50057-4
148. Branchini LA, Adhi M, Regatieri C V, et al. Analysis of choroidal morphologic features and vasculature in healthy eyes using spectral-domain optical coherence tomography. *Ophthalmology.* 2013;120(9):1901-1908. doi:10.1016/j.ophtha.2013.01.066
149. Duarte L, Ruão M, Gallego R. Focal choroidal changes on diabetic macular edema. *Acta Ophthalmol.* 2015;93(S255):n/a-n/a. doi:10.1111/j.1755-3768.2015.0614
150. Ohara Z, Tabuchi H, Nakakura S, et al. Changes in choroidal thickness in patients with diabetic retinopathy. *Int Ophthalmol.* 2017;38(1):279-286. doi:10.1007/s10792-017-0459-9
151. Zhang Z, Meng X, Wu Z, et al. Changes in Choroidal Thickness After Panretinal Photocoagulation for Diabetic Retinopathy: A 12-Week Longitudinal Study. *Invest Ophthalmol Vis Sci.* 2015;56(4):2631-2638. doi:10.1167/iovs.14-16226
152. Cho GE, Cho HY, Kim YT. Change in subfoveal choroidal thickness after argon laser panretinal photocoagulation. *Int J Ophthalmol.* 2013;6(4):505-509. doi:10.3980/j.issn.2222-3959.2013.04.18

153. Kniggendorf VF, Novais EA, Kniggendorf SL, Xavier C, Cole ED, Regatieri C V. Effect of intravitreal anti-VEGF on choroidal thickness in patients with diabetic macular edema using spectral domain OCT. *Arq Bras Oftalmol.* 2016;79(3):155-158. doi:10.5935/0004-2749.20160047
154. Laíns and Figueira J, Santos AR, Baltar A, et al. Choroidal thickness in diabetic retinopathy: the influence of antiangiogenic therapy. *Retina.* 2014;34(6):1199-1207. doi:10.1097/IAE.0000000000000053
155. Campos A, Campos EJ, Martins J, Ambrósio AF, Silva R. Viewing the choroid: where we stand, challenges and contradictions in diabetic retinopathy and diabetic macular oedema. *Acta Ophthalmol.* 2017;95(5):446-459. doi:10.1111/aos.13210
156. Melancia D, Vicente A, Cunha JP, Abegão Pinto L, Ferreira J. Diabetic choroidopathy: a review of the current literature. *Græfe's Arch Clin Exp Ophthalmol.* 2016;254(8):1453-1461. doi:10.1007/s00417-016-3360-8
157. Xu J, Xu L, Du KF, et al. Subfoveal Choroidal Thickness in Diabetes and Diabetic Retinopathy. *Ophthalmology.* 2013;120(10):2023-2028. doi:10.1016/j.ophtha.2013.03.009
158. Caio V Regatieri, Lauren Branchini, Jill Carmody, James G Fujimoto JSD. Choroidal Thickness in Patients With Diabetic Retinopathy Analyzed By Spectral-Domain Optical. *Retina.* 2012;32(3):563-568. doi:10.1097/IAE.0b013e31822f5678.CHOROIDAL
159. De Freytas A, Gallego Pinazo R, Cisneros Lanuza A. Grosor corioideo subfoveal medido con tomografía de coherencia óptica swept source en ojos con edema macular diabético. *Arch Soc Esp Oftalmol.* 2016;91(5):228-231. doi:10.1016/j.oftal.2015.12.015
160. Sohn EH, Khanna A, Tucker BA, Abramoff MD, Stone EM, Mullins RF. Structural and biochemical analyses of choroidal thickness in human donor eyes. *Investig Ophthalmol Vis Sci.* 2014;55(3):1352-1360. doi:10.1167/iovs.13-13754
161. Akay F, Gundogan FC, Yolcu U, Toyran S, Uzun S. Choroidal thickness in systemic arterial hypertension. *Eur J Ophthalmol.* 2015;26(2):152-157. doi:10.5301/ejo.5000675
162. Ahn SJ, Woo SJ, Park KH. Retinal and Choroidal Changes With Severe Hypertension and Their Association With Visual Outcome. *Invest Ophthalmol Vis Sci.* 2014;55(12):7775-7785. doi:10.1167/iovs.14-14915

163. Gök M, Karabas VL, Emre E, Aksar AT, Aslan MS, Ural D. Evaluation of choroidal thickness via enhanced depth-imaging optical coherence tomography in patients with systemic hypertension. *Indian J Ophthalmol.* 2015;63(3):239-243. doi:10.4103/0301-4738.156928
164. Sansom LT, Suter CA, McKibbin M. The association between systolic blood pressure, ocular perfusion pressure and subfoveal choroidal thickness in normal individuals. *Acta Ophthalmol.* 2016;94(2):e157-e158. doi:10.1111/aos.12794
165. Gabriel M, Esmaeelpour M, Shams-Mafi F, et al. Mapping diurnal changes in choroidal, Haller's and Sattler's layer thickness using 3-dimensional 1060-nm optical coherence tomography. *Graefe's Arch Clin Exp Ophthalmol.* 2017;255(10):1957-1963. doi:10.1007/s00417-017-3723-9
166. Iwase T, Yamamoto K, Ra E, Murotani K, Matsui S, Terasaki H. Diurnal variations in blood flow at optic nerve head and choroid in healthy eyes: diurnal variations in blood flow. *Medicine (Baltimore).* 2015;94(6):e519. doi:10.1097/MD.0000000000000519
167. Sohrab M, Wu K, Fawzi AA. A Pilot Study of Morphometric Analysis of Choroidal Vasculature In Vivo, Using En Face Optical Coherence Tomography. *PLoS One.* 2012;7(11):e48631. doi:10.1371/journal.pone.0048631
168. Murakami T, Uji A, Suzuma K, et al. In vivo choroidal vascular lesions in diabetes on swept-source optical coherence tomography. *PLoS One.* 2016;11(8):e0160317. doi:10.1371/journal.pone.0160317
169. Adhi M, Ferrara D, Mullins RF, et al. Characterization of Choroidal Layers in Normal Aging Eyes Using Enface Swept-Source Optical Coherence Tomography. *PLoS One.* 2015;10(7):e0133080. doi:10.1371/journal.pone.0133080
170. Lutty GA. Diabetic choroidopathy. *Vision Res.* 2017;139:161-167. doi:10.1016/j.visres.2017.04.011
171. Huynh E, Chandrasekera E, Bukowska D, McLenachan S, Mackey DA, Chen FK. Past, Present, and Future Concepts of the Choroidal Scleral Interface Morphology on Optical Coherence Tomography. *Asia-Pacific J Ophthalmol.* 2017;6(1):94-103. doi:10.22608/APO.201698
172. Tan KA, Laude A, Yip V, Loo E, Wong EP, Agrawal R. Choroidal vascularity index – a novel optical coherence tomography parameter for disease monitoring in diabetes mellitus? *Acta Ophthalmol.* 2016;94(7):e612-e616. doi:10.1111/aos.13044

173. Agrawal R, Gupta P, Tan K-A, Cheung CMG, Wong T-Y, Cheng C-Y. Choroidal vascularity index as a measure of vascular status of the choroid: Measurements in healthy eyes from a population-based study. *Sci Rep*. 2016;6:21090. doi:10.1038/srep21090
174. Wang JC, Láíns I, Providência J, et al. Diabetic Choroidopathy: Choroidal Vascular Density and Volume in Diabetic Retinopathy With Swept-Source Optical Coherence Tomography. *Am J Ophthalmol*. 2017;184:75-83. doi:10.1016/j.ajo.2017.09.030
175. Verma A, Nagpal M, Mehrotra N. In Vivo Assessment of Choroid in Diabetic Retinopathy by Enhanced Depth Imaging in Spectral Domain Optical Coherence Tomography. *Asia-Pacific J Ophthalmol (Philadelphia, Pa)*. March 2016. doi:10.1097/APO.0000000000000204

APPENDIX 1 — Copyright license

ELSEVIER LICENSE TERMS AND CONDITIONS

Jul 31, 2018

This Agreement between Dr. LILIANNE DUARTE ("You") and Elsevier ("Elsevier") consists of your license details and the terms and conditions provided by Elsevier and Copyright Clearance Center.

License Number	4357651096377
License date	May 28, 2018
Licensed Content Publisher	Elsevier
Licensed Content Publication	Ophthalmology: Journal of the American Academy of Ophthalmology
Licensed Content Title	Analysis of Choroidal Morphologic Features and Vasculature in Healthy Eyes Using Spectral-Domain Optical Coherence Tomography
Licensed Content Author	Lauren A. Branchini, Mehreen Adhi, Caio V. Regatieri, Namrata Nandakumar, Jonathan J. Liu, Nora Laver, James G. Fujimoto, Jay S. Duker
Licensed Content Date	Sep 1, 2013
Licensed Content Volume	120
Licensed Content Issue	9
Licensed Content Pages	8
Start Page	1901
End Page	1908
Type of Use	reuse in a thesis/dissertation
Portion	figures/tables/illustrations
Number of figures/tables/illustrations	1
Format	electronic
Are you the author of this Elsevier article?	No
Will you be translating?	No
Original figure numbers	Figure 2
Title of your thesis/dissertation	CHOROIDAL THICKNESS AND MORPHOLOGY ANALYSED BY OPTICAL COHERENCE TOMOGRAPHY AS A METHOD TO APPROACH DIABETIC OCULAR DISEASE PROGNOSIS AND PROGRESSION
Expected completion date	Oct 2018
Estimated size (number of pages)	140
Requestor Location	Dr. LILIANNE DUARTE R D Maria Pia, 665

APPENDIX 2 — Patient Informed Consent Form

PROTOCOLO CHEDV-OFT-01-14

FOLHA DE INFORMAÇÃO AO DOENTE

ESTUDO: “ESPESSURA E MORFOLOGIA DA CORÓIDE ANALISADA COM A TOMOGRAFIA ÓPTICA DE COERÊNCIA COMO MÉTODO DE AVALIAÇÃO PROGNÓSTICA E DE PROGRESSÃO DA DOENÇA DIABÉTICA OCULAR”

Descrição do estudo e Procedimentos do estudo

O estudo proposto é um estudo observacional em que se pretende avaliar as características e alterações que ocorrem na coróide nos doentes diabéticos, comparando com pessoas não diabéticas. A coróide é a parte do olho mais rica em vasos sanguíneos e que está localizada mais exteriormente, daí até agora ter sido de difícil visualização com os métodos de exames complementares de que dispúnhamos. A forma como a Diabetes pode causar doença no olho é através da alteração do normal funcionamento dos vasos sanguíneos. Com a nova técnica de exame complementar, chamada Tomografia Óptica de Coerência, conseguimos de forma não invasiva, avaliar a estrutura das camadas mais profundas do olho.

Neste estudo vamos seguir doentes diabéticos de acordo com os procedimentos habituais e recomendados, fazer uma análise dos exames para avaliar as alterações que ocorrem. Vão ser também observados indivíduos sem o Diagnóstico de Diabetes para se poder comparar as alterações encontradas entre os dois grupos.

Este estudo terá a duração de 2 anos, em que os voluntários serão observados de 6 em 6 meses ou sempre que o quadro clínico o justificar. Sempre que houver necessidade de tratamento serão orientados para o fazer. Em todas as consultas será feito um exame oftalmológico completo que inclui para todos os voluntários a realização da Tomografia Óptica de Coerência. No caso dos voluntários diabéticos, realizarão, de acordo com a prática clínica habitual, a angiografia fluoresceínica, com uma periodicidade anual ou sempre que a evolução da doença o indicar.

Participação voluntária

A sua participação neste estudo observacional deve ser de sua livre vontade.

Se decidir não participar neste estudo, não sofrerá nenhuma consequência negativa no seu futuro tratamento. Isto também se aplica se decidir desistir de participar em qualquer altura. Esta opção está aberta para si a qualquer momento, e não lhe será pedido que forneça explicações por desistir de participar ou continuar o estudo.

Versão 2 de 11 de Abril de 2014

1

PROTOCOLO CHEDV-OFT-01-14

Para sua segurança, será submetido a um exame final em qualquer dos casos.

Local de Realização do Estudo

Este estudo será realizado no Serviço de Oftalmologia do Hospital de São Sebastião, em Santa Maria da Feira, Centro Hospitalar Entre o Douro e o Vouga.

Benefícios/Riscos

A sua participação neste estudo pode ter os seguintes benefícios: uma supervisão médica pelo especialista em oftalmologia e tratamento necessário.

Os riscos associados à participação no estudo estão relacionados com o risco da angiografia fluoresceínica. É um método invasivo para avaliação da circulação ocular (na retina), em que se injeta um produto de contraste na veia do antebraço, e que vai circular até ao olho, permitindo, através do registo por fotografias seriadas, avaliar a circulação da retina e as zonas afetadas pela retinopatia diabética e com necessidade de tratamento. É um exame importante e necessário no estudo da retinopatia diabética. Pode apresentar efeitos secundários ligeiros como coloração amarelada da pele e urina nas 24 a 36 horas após a injeção até a eliminação total do produto de contraste (em 100% dos casos), náuseas (em menos de 10% dos casos), vômitos (em menos de 2% dos casos), prurido (comichão) ou reação vagal (desmaio) à injeção (em menos de 1% dos casos). Efeitos secundários graves com reações alérgicas graves são muito raros.

A sua participação neste estudo não deverá causar qualquer inconveniente para além das visitas programadas ao Serviço de Oftalmologia.

Confidencialidade dos registos clínicos

Durante o estudo, os seus dados pessoais serão arquivados. Todos os dados serão tratados anonimamente e serão apenas disponibilizados ao responsável do estudo para avaliação clínica.

Toda a confidencialidade será mantida durante e após o estudo e durante os procedimentos de controlo acima descritos.

Descontinuação involuntária do estudo

O investigador poderá excluí-lo do estudo pelo interesse da sua saúde. Se durante o estudo desenvolver qualquer outra alteração oftalmológica não relacionada com a Diabetes ou doença sistémica grave será orientado para tratamento e sairá do estudo.

PROCOLO CHEDV-OFT-01-14

Para sua segurança, terá um exame médico final em qualquer dos casos.

Pessoa a contactar

No caso de qualquer problema ou dúvida poderá contactar as pessoas abaixo indicadas:

Dr^a Lilianne Duarte

Serviço de Oftalmologia

Hospital de São Sebastião/ Centro Hospitalar Entre o Douro e o Vouga

PROTOCOLO CHEDV-OFT-01-14

CONSENTIMENTO ESCRITO

Eu, abaixo assinado, _____, residente em _____, concordo em participar no estudo denominado “ESPESSURA E MORFOLOGIA DA COROIDE ANALISADA COM A TOMOGRAFIA ÓPTICA DE COERÊNCIA COMO MÉTODO DE AVALIAÇÃO PROGNÓSTICA E DE PROGRESSÃO DA DOENÇA DIABÉTICA OCULAR”.

Foram-me dadas todas as explicações pelo(a) Dr(a) _____, responsável pelo estudo, acerca da natureza, objectivos e duração. Foi-me dada oportunidade de colocar todas as questões relacionadas com todos os aspectos do estudo. Foi-me também dada uma cópia da Folha de Informação ao Doente.

Depois destas considerações, concordo em colaborar neste estudo e com a sua equipa, e informá-la imediatamente se surgir alguma anormalidade. Tomei conhecimento que sou livre para desistir do estudo em qualquer altura, se assim o desejar.

A minha identidade nunca será revelada, e os dados obtidos serão tratados confidencialmente. Concordo que eles podem ser examinados pelos investigadores envolvidos no estudo e pelos representantes das autoridades de saúde. Concordo em não me opor à divulgação dos resultados a que o estudo se propõe.

Data e Assinatura do Investigador

Data e Assinatura do Doente

APPENDIX 3 — Hospital Study Approval



Exma. Senhora
Dra. Lilianne Duarte
Serviço de Oftalmologia
Centro Hospitalar de Entre o Douro e Vouga

CA-286/14-2
FS/AC

Data: 2014/05/16

Assunto: "Espessura e morfologia da coróide analisada com a tomografia ótica de coerência como método de avaliação prognóstica e de progressão da doença diabética ocular"

O Conselho de Administração do Centro Hospitalar de Entre o Douro e Vouga, EPE, deliberou em reunião de 15 de maio de 2014, autorizar a realização do trabalho de investigação mencionado em epígrafe.

Com os melhores cumprimentos,



Fernando Silva
Presidente do Conselho de Administração