

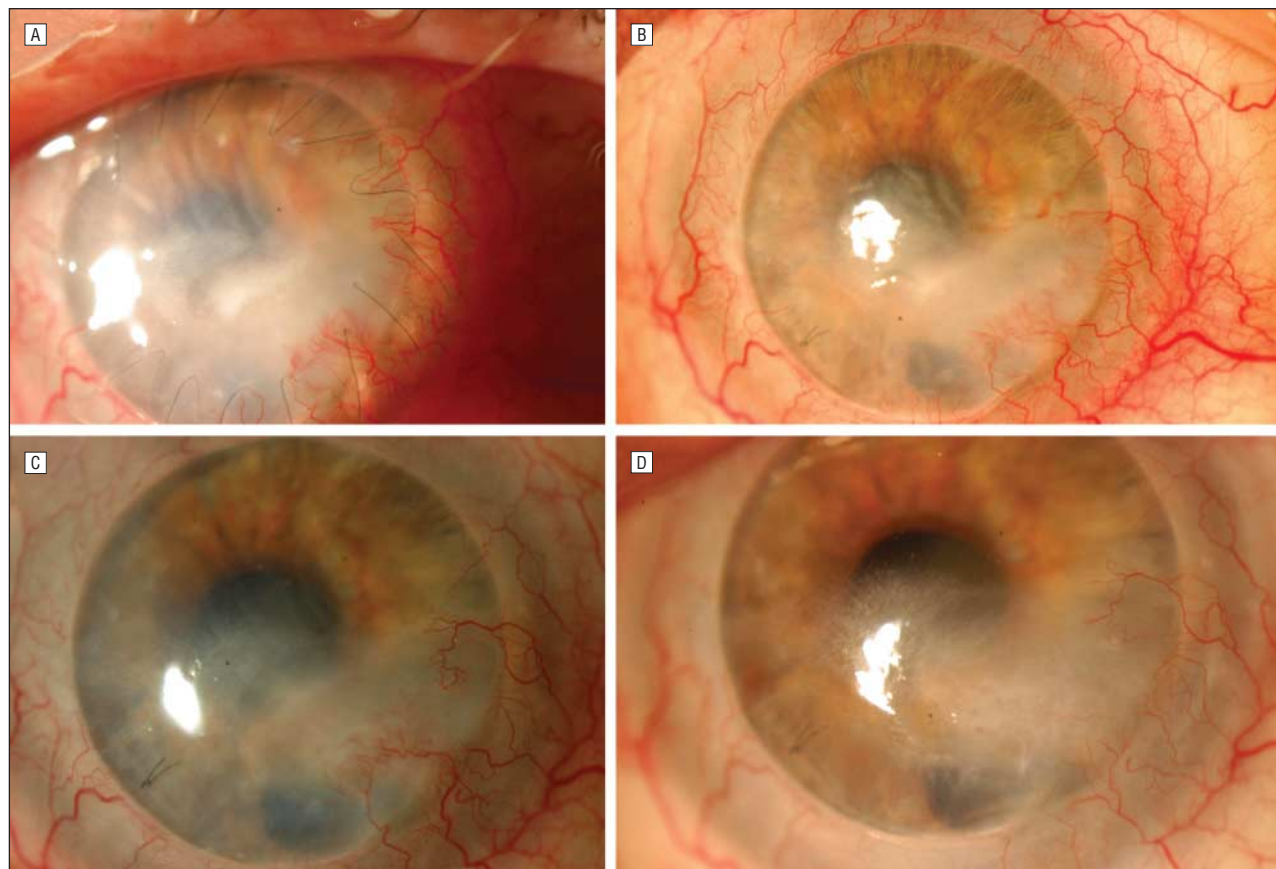
## RESEARCH LETTERS

### Successful Topical Application of Caspofungin in the Treatment of Fungal Keratitis Refractory to Voriconazole

Fungal keratitis is an important ophthalmic problem because it leads to corneal blindness and sometimes to loss of the eye.<sup>1,2</sup> There is no agreed protocol for the treatment of suspected fungal keratitis. Topical and oral voriconazole have now been reported to be effective.<sup>3</sup> However, some cases do not respond to this treatment. New antifungal agents such as caspofungin acetate, 0.5%, are promising alternatives.

**Report of a Case.** A 60-year-old woman with a history of penetrating keratoplasty in her right eye due to corneal herpetic infection 1 year earlier was admitted be-

cause of visual disturbances and ocular pain. Slitlamp examination revealed an epithelial defect with corneal infiltration (**Figure, A**). Corneal scrapings were taken for smear and culture, and *Candida albicans* was isolated. We asked our pharmacology service for amphotericin B eyedrops but were informed of solubility and stability problems with the actual presentation of this drug. Treatment with topical voriconazole, 1%, administered every hour and oral voriconazole at a dosage of 200 mg twice daily was started. After 1 month the lesion had not progressed but there was no change in corneal infiltration, and cultures remained repeatedly positive for *C albicans* with no evidence of viral infection (**Figure, B**). Therefore, after obtaining the patient's consent and permission of sanitary authorities, we decided to apply topical caspofungin, 0.5%, every hour. To obtain the eyedrops, 1 vial of 50 mg of caspofungin acetate was diluted in 10.5 mL of sterile normal saline; all eyedrops were freshly made daily, kept at 4°C, and protected from light. One week later, clinical improvement was observed and cultures revealed no growth (**Figure, C**). Treatment with



**Figure.** Evolution of the case. A, Epithelial defect with corneal infiltration. Corneal scrapings were taken for smear and culture, and *Candida albicans* was isolated. B, One month after starting treatment with topical voriconazole, cultures remained positive for *C albicans*. C, One week after starting treatment with topical caspofungin acetate, clinical improvement was observed and cultures revealed no growth. D, Four weeks after starting treatment with topical caspofungin, complete healing of the corneal epithelium and resolution of the corneal infiltrate were observed. However, the corneal opacity persisted (a neglected suture was removed).

topical caspofungin was progressively decreased over 3 further weeks. Following the completion of treatment, complete healing of the corneal epithelium and resolution of the corneal infiltrate were observed, although the corneal opacity persisted (Figure, D). There was no evidence of ocular toxic effects and no recurrence of fungal keratitis over a follow-up period of 6 months.

**Comment.** *C albicans* is the most frequent cause of fungal keratitis in temperate regions and is an opportunistic organism that can complicate chronic keratopathy and corneal grafting. Persistent epithelial defects and suture-related problems, along with immunosuppression, have been found to be the major predisposing risk factors.

Caspofungin is a first-in-class echinocandin with potent activity against *Candida* and *Aspergillus*, the dominant human fungal pathogens. In contrast to all other antifungal drugs, echinocandins have a selective action on a target present only in fungal cell walls (not in mammalian cells): they inhibit the synthesis of an essential component, (1,3)-D-glucan. Caspofungin is fungicidal in vivo and in vitro against all *Candida* species, including fluconazole-resistant strains. Its activity differs from that of the azole antifungal group, which is fungistatic.<sup>4</sup> In our case, we think that voriconazole stopped progression of the infiltrate but did not kill the microorganism. The presence of the fungus after 1 month could be due to poor drug penetration, fungal resistance, or both. We therefore suggest that an ideal treatment protocol should include antifungal agents chosen on the basis of in vitro susceptibility of the fungus with a duration assessed by in vivo monitoring of fungal filaments or yeasts.

To our knowledge, the topical ocular use of caspofungin has been reported in rabbits.<sup>5</sup> There has been only 1 report of its use in humans, although it was in association with other antifungal drugs.<sup>4</sup>

In conclusion, topical caspofungin, 0.5%, is a new, promising option in the treatment of refractory fungal-related corneal ulcers with no evidence of ocular toxic effects. However, future studies with larger samples are indicated to further evaluate its efficacy and tolerance.

Mercedes Hurtado-Sarrió, MD, PhD  
Antonio Duch-Samper, MD, PhD  
Angel Cisneros-Lanuza, MD, PhD  
Manuel Díaz-Llopis, MD, PhD  
Javier Peman-García, MD  
Amparo Vazquez-Polo, MD

**Author Affiliations:** Ophthalmology Service (Drs Hurtado-Sarrió, Cisneros-Lanuza, and Díaz-Llopis), Microbiology Service (Dr Peman-García), and Pharmacology Service (Dr Vazquez-Polo), La Fe University Hospital, and Ophthalmology Service, Arnau de Vilanova Hospital (Dr Duch-Samper), Valencia, Spain.

**Correspondence:** Dr Hurtado-Sarrió, Ophthalmology Service, La Fe University Hospital, Esmeralda I, Casa 7, Mas Camarena, 46117, Betera, Valencia, Spain (hurtado\_mer@gva.es).

**Financial Disclosure:** None reported.

1. Vajpayee RB, Sharma N, Sinha R, Agarwal T, Singhvi A. Infectious keratitis following keratoplasty. *Surv Ophthalmol.* 2007;52(1):1-12.
2. Tuft SJ, Tullio AB. Fungal keratitis in the United Kingdom 2003-2005. *Eye (Lond).* 2009;23(6):1308-1313.
3. Lee SJ, Lee JJ, Kim SD. Topical and oral voriconazole in the treatment of fungal keratitis. *Korean J Ophthalmol.* 2009;23(1):46-48.
4. Tu EY. *Alternaria* keratitis: clinical presentation and resolution with topical fluconazole or intrastromal voriconazole and topical caspofungin. *Cornea.* 2009;28(1):116-119.
5. Vorwerk CK, Tuchen S, Streit F, Binder L, Hofmüller W, Behrens-Baumann W. Aqueous humor concentrations of topically administered caspofungin in rabbits. *Ophthalmic Res.* 2009;41(2):102-105.

## IgG4-Positive Dacryoadenitis and Küttner Submandibular Sclerosing Inflammatory Tumor

The coexistence of idiopathic inflammatory masses of the submandibular and lacrimal glands featuring lymphoid hyperplasia and fibrosclerosis is unknown to most ophthalmologists.<sup>1-3</sup> The former is referred to as Küttner tumor. Systemic and autoimmune diseases, including Sjögren syndrome (SS) and lymphoma, are characteristically absent in this complex. In our case, IgG4-positive plasma cells were present in the lesions of both glands.

**Report of a Case.** A 69-year-old woman had left submandibular gland swelling that developed over 2 months in 2002. Biopsy revealed chronic sclerosing sialadenitis. Recurrence and rebiopsy in 2005 showed the same pathologic findings. In 2008, the patient had sudden bulging of her right eye with lateral eyelid fullness, pain, and double vision. Best-corrected visual acuities were 20/30 OD and 20/25 OS. The right eye exhibited mild epibulbar injection, painful limited abduction, and 3 mm of proptosis (Figure 1A). A computed tomographic scan demonstrated enlargement of the right lacrimal gland and lateral and superior rectus muscles (Figure 1B). Results from a general physical examination and standard serological studies were negative. Serum IgG4 levels were not obtained. The patient did not have diabetes or abdominal or urinary tract symptoms, and an abdominal computed tomographic scan was not performed. Biopsy of the lacrimal gland revealed sclerosing dacryoadenitis. The patient was treated with a prednisone taper over 2 months starting at 80 mg daily and decreasing by 10 mg every week. Seven months later, she manifested a nontender, palpable lacrimal gland with residual proptosis without recurrence of submandibular disease. The patient continued to feel well and no systemic disease has emerged over a clinical course of 7 years.

The submandibular and lacrimal gland biopsies displayed similar histopathologic features. The fibrous septa in the former were thickened and enclosed lobules of glandular tissue exhibiting a lymphoplasmacytic infiltrate with scattered follicles (Figure 1C). Interstitial fibrosis and acinar atrophy were juxtaposed with uninvolved lobules of well-preserved glandular tissue (Figure 1D). A smaller lacrimal gland biopsy specimen harbored a dense lymphoplasmacytic infiltrate (Figure 1E) with rare surviving acini (Figure 1F). The CD3<sup>+</sup> T lymphocytes somewhat predominated over CD20<sup>+</sup> B lymphocytes in the parotid gland (Figure 2A), whereas the converse was