

Filamin C variants are associated with a distinctive clinical and immunohistochemical arrhythmogenic cardiomyopathy phenotype

Charlotte L. Hall ^{a,1}, Mohammed M. Akhtar ^{a,1}, Maria Sabater-Molina ^{b,1}, Marta Futema ^{a,1}, Angeliki Asimaki ^{c,1}, Alexandros Protonotarios ^{a,1}, Chrysoula Dalageorgou ^{a,1}, Alan M. Pittman ^{d,1}, Mari Paz Suarez ^{e,1}, Beatriz Aguilera ^{e,1}, Pilar Molina ^{f,1}, Esther Zorio ^{g,1}, Juan Pedro Hernández ^{h,1}, Francisco Pastor ^{i,1}, Juan R. Gimeno ^{j,1}, Petros Syrris ^{a,*}, William J. McKenna ^{a,1}

^a Centre for Heart Muscle Disease, Institute of Cardiovascular Science, University College London, London, UK

^b Laboratorio de Cardiogenética, Instituto Murciano de Investigación Biosanitaria and Universidad de Murcia, Murcia, Spain

^c Cardiology Clinical Academic Group, Molecular and Clinical Sciences Research Institute, St Georges University of London, London, UK

^d Molecular and Clinical Sciences Research Institute, St Georges University of London, London, UK

^e Instituto Nacional de Toxicología y Ciencias Forenses de Madrid (INTCF), Madrid, Spain

^f Department of Pathology at the Instituto de Medicina Legal y Ciencias Forenses de Valencia (IMLCF-Valencia), Histology Unit at the Universitat de València, Research Group on Inherited Heart Diseases, Sudden Death and Mechanisms of Disease (CaFaMuSMe) from the Instituto de Investigación Sanitaria (IIS) La Fe, Valencia, Spain

^g Cardiology Department at Hospital Universitario y Politécnico La Fe and Research Group on Inherited Heart Diseases, Sudden Death and Mechanisms of Disease (CaFaMuSMe) from the Instituto de Investigación Sanitaria (IIS) La Fe, Valencia, Spain

^h Instituto de Medicina Legal de Murcia (IML-Murcia), Murcia, Spain

ⁱ Servicio de Cardiología del Hospital Universitario Virgen de la Arrixaca and Departamento de Medicina Interna de la Universidad de Murcia, Murcia, Spain

^j Hospital Universitario Virgen de la Arrixaca, Murcia, Spain

ARTICLE INFO

Article history:

Received 11 June 2019

Received in revised form 13 August 2019

Accepted 18 September 2019

Available online 8 October 2019

Keywords:

Arrhythmogenic cardiomyopathy

ARVC

Filamin C variants

Immunohistochemistry

Late gadolinium enhancement

ABSTRACT

Background: Pathogenic variants in the filamin C (*FLNC*) gene are associated with inherited cardiomyopathies including dilated cardiomyopathy with an arrhythmogenic phenotype. We evaluated *FLNC* variants in arrhythmogenic cardiomyopathy (ACM) and investigated the disease mechanism at a molecular level.

Methods: 120 gene-elusive ACM patients who fulfilled diagnostic criteria for arrhythmogenic right ventricular cardiomyopathy (ARVC) were screened by whole exome sequencing. Fixed cardiac tissue from *FLNC* variant carriers who had died suddenly was investigated by histology and immunohistochemistry.

Results: Novel or rare *FLNC* variants, four null and five variants of unknown significance, were identified in nine ACM probands (7.5%). In *FLNC* null variant carriers (including family members, n = 16) Task Force diagnostic electrocardiogram repolarization/depolarization abnormalities were uncommon (19%), echocardiography was normal in 69%, while 56% had >500 ventricular ectopics/24 h or ventricular tachycardia on Holter and 67% had late gadolinium enhancement (LGE) on cardiac magnetic resonance imaging (CMRI). Ten gene positive individuals (63%) had abnormalities on ECG or CMRI that are not included in the current diagnostic criteria for ARVC. Immunohistochemistry showed altered key protein distribution, distinctive from that observed in ARVC, predominantly in the left ventricle.

Conclusions: ACM associated with *FLNC* variants presents with a distinctive phenotype characterized by Holter arrhythmia and LGE on CMRI with unremarkable ECG and echocardiographic findings. Clinical presentation in asymptomatic mutation carriers at risk of sudden death may include abnormalities which are currently non-diagnostic for ARVC. At the molecular level, the pathogenic mechanism related to *FLNC* appears different to classic forms of ARVC caused by desmosomal mutations.

© 2019 The Authors. Published by Elsevier B.V. This is an open access article under the CC BY-NC-ND license (<http://creativecommons.org/licenses/by-nc-nd/4.0/>).

* Corresponding author. Centre for Heart Muscle Disease, Institute of Cardiovascular Science, University College London, London, WC1E 6DD, UK.

E-mail address: p.syrris@ucl.ac.uk (P. Syrris).

¹ The author takes responsibility for all aspects of the reliability and freedom from bias of the data presented and their discussed interpretation.

1. Introduction

Efforts to improve early detection of individuals at risk of life threatening arrhythmia from inherited cardiovascular disease are ongoing [1]. Identification of patients who present with arrhythmias independent of or not explained by recognized causes of cardiac disease has led to the proposal for the term arrhythmogenic cardiomyopathy (ACM) [2–4]. The recognition of a number of inherited arrhythmogenic cardiomyopathies has led to the recent broader acceptance of this term [1]. Incorporated within this classification are patients who present with ventricular arrhythmia in association with right, left or biventricular disease. Arrhythmogenic Right Ventricular Cardiomyopathy (ARVC) caused by mutations in desmosomal genes is the most studied of the ACMs with well established clinical and pathological diagnostic criteria [5,6].

ACM with prominent left ventricle involvement can be indistinguishable from arrhythmogenic forms of dilated cardiomyopathy (DCM) both clinically and genetically [7]. The *FLNC* gene, encoding the major cardiac structural protein filamin C, has been implicated in inherited forms of cardiomyopathy, including DCM [8]. Recent studies have reported truncating variants in *FLNC* as the cause of DCM with life-threatening ventricular arrhythmia [9,10]. Clinical evaluation of *FLNC* mutation carriers and molecular characterization of cardiac tissue from a patient carrying a truncating variant have shown a link between DCM and ARVC, both at the clinical and cellular level [10]. However, to date, the causal role of *FLNC* variants in ACM cases fulfilling Task Force diagnostic criteria for ARVC has not been directly investigated. As a result, the clinical and molecular phenotype of *FLNC*-associated ACM is currently unknown.

In this study, we investigate the clinical characteristics of *FLNC* mutation carriers in ACM pedigrees in which the index cases fulfil current diagnostic criteria for ARVC. We also report the distribution of key proteins in myocardial tissue with *FLNC* variants and compare it with that observed in classic forms of the disorder.

2. Methods

2.1. Patient cohort

Genetic screening of 269 ACM patients by targeted next generation sequencing as described by Lopes et al. [11] identified a group of 120 index cases who were free of potentially pathogenic variants in major genes associated with cardiomyopathy, arrhythmia and heart failure syndromes. This gene-elusive cohort underwent whole exome sequencing in order to identify novel causative ACM genes.

Patients were referred to the Inherited Cardiovascular Disease Unit at the Heart Hospital (prior to 2014) and the Barts Cardiac Centre, St Bartholomew's Hospital with a suspicion of ACM or with a premature sudden cardiac death and/or known ACM in their family. Clinical diagnosis of arrhythmogenic cardiomyopathy was based on the Task Force diagnostic criteria [6]. Index cases included in this study had a diagnosis of definite or borderline ARVC based on the fulfilment of the current Task Force diagnostic criteria for the disorder [6], or had a possible diagnosis on account of a first-degree relative who died suddenly aged less than 35 years with a post mortem (PM) diagnosis of ARVC. Detailed clinical evaluation included medical and family history, 12-lead electrocardiogram (ECG), signal averaged ECG (SAECG), 24-h ambulatory ECG, standard 2D transthoracic echocardiogram and cardiac magnetic resonance imaging (CMRI). When appropriate clinical phenotyping and genetic testing was offered to extended relatives within pedigrees.

This study conforms with the ethical guidelines of the 1975 Declaration of Helsinki and has received approval by the National Health Service (NHS) Ethics Committees (REC ID: 15/LO/0549, UK) and CEIC Hospital Virgen de la Arrixaca (Spain) and CEIC Hospital

Universitario y Politécnico La Fe (Spain). Informed written consent for inclusion in the study was obtained from all participants or, in cases of minors or deceased individuals, from first-degree family members.

2.2. Whole exome sequencing (WES)

In this study we performed whole exome sequencing on DNA samples from ACM index cases and family members. DNA from whole blood, paraffin-embedded cardiac tissue and saliva samples was extracted utilizing kits and protocols from Qiagen and DNA Genotek. Genomic DNA was subjected to sample preparation as per the protocol recommended by Agilent for the SureSelect^{XT} Target Enrichment for Illumina paired-end multiplexed sequencing method. Targeted exonic regions were captured using the Agilent SureSelect^{XT} Human Exon V5 following the manufacturer's protocol. Enriched DNA libraries were exome sequenced on the Illumina NextSeq500 platform as paired-end 75 base reads at a minimum of 30x coverage. Bioinformatic analysis of WES data including copy number variation was based on an in-house developed pipeline (Supplementary material, Appendix).

2.3. Immunohistochemistry

As cardiac tissue was not available from British patients screened by WES, in order to determine the effects of *FLNC* mutations at the level of the intercalated disc, post mortem cardiac tissue from patients with *FLNC* variants was sourced from a Spanish clinicopathology consortium. Right and left ventricle (RV and LV) specimens from eleven sudden cardiac death (SCD) victims with a diagnosis of arrhythmogenic cardiomyopathy carrying potentially pathogenic *FLNC* variants were included in this study. Post-mortem (PM) examination protocol was in keeping with published guidelines. The patients, all male, (aged 16–52, mean age of death 33.5 years) had a diagnosis of ARVC or left dominant arrhythmogenic cardiomyopathy at autopsy due to the presence of fibrosis and fat infiltration (nine cases) and predominant fibrosis (3 cases). Cardiac samples from those cases were fixed in formalin and preserved in paraffin blocks. Immunohistochemical analysis of key proteins previously implicated in the molecular pathogenesis of classical ARVC in myocardial tissue was carried out based on the protocol developed by Asimaki et al. [12]. Detailed description of the method is provided in the Appendix. Tissue samples from age-matched individuals with no clinical or pathological evidence of heart disease were subjected to the same protocol and used as negative controls (n = 5). In summary, RV and LV specimens from each SCD case were stained for filamin C, plakoglobin, desmoplakin, connexin 43, synapse-associated protein SAP97 and glycogen synthase kinase 3 β , GSK3 β .

3. Results

3.1. *FLNC* variants

WES of a cohort of 120 gene-elusive ACM index cases identified seven novel and two rare *FLNC* variants (7.5%). They include four null variants (three nonsense and one splice site variant) which are predicted to be pathogenic based on the American College of Medical Genetics and Genomics (ACMG) guidelines and five variants of unknown significance (VUS, one in-frame deletion and four missense variants) [13]. Details of these variants are given in Appendix Table A1. *FLNC* variants identified by WES were confirmed by Sanger DNA sequencing. There were no *FLNC* copy number variants identified in the cohort.

3.2. Clinical phenotypes of *FLNC* variant carriers

Index cases carrying *FLNC* variants had a diagnosis of definite ($n = 4$), borderline ($n = 2$) or possible ($n = 3$) ARVC based on the Task Force diagnostic criteria [6]. All had at least one sudden cardiac death victim in their extended families ranging from 20 to 71 years (median 40yrs) and ARVC or arrhythmogenic left ventricular cardiomyopathy (ALVC) was diagnosed at PM in six deceased family members (Appendix Table A2).

Segregation analysis and cascade genetic screening with clinical evaluation of relatives in pedigrees was feasible in the four families carrying the null *FLNC* variants (Fig. 1). Detailed clinical features for *FLNC* variant carriers in Families A–D are provided in Table 1. For the VUS variants, pedigree analysis was possible in only two cases (Families E and F) which carried the p.59_62DLQRdel and p.K2260R variants respectively (Appendix Figure A1). No family members of index cases G, H and I were available. Clinical characteristics of *FLNC* VUS carriers are given in Appendix Table A3. There was no evidence of skeletal muscle abnormalities in ACM index cases or their relatives and serum creatine kinase levels were normal in those tested. In addition to ACM index cases, another 26 relatives were clinically evaluated and genotyped for *FLNC* variants; fourteen of them were genotype positive. DNA from two SCD cases was available and those individuals were also found to be *FLNC* variant carriers (Fig. 1 and Figure A1 and Table 1 and A3).

Due to the limited clinical information on pedigrees with *FLNC* VUS variants and the ambiguity regarding possible pathogenicity of such variants, analysis focused on the ACM families with *FLNC* null variants (index cases and relatives, $n = 16$). In this cohort the presence of Task Force diagnostic ECG repolarization and depolarization abnormalities were uncommon, $n = 2$ (12.5%) and $n = 1$ (6.25%) respectively. ECG was unremarkable in 5 genotype positive individuals (31%), abnormalities in the remaining included low voltage 5/16 (32%) and poor R wave progression across anterior chest leads 1/16 (6%). In the majority of cases echocardiogram did not reveal overt abnormalities ($n = 11$, 69%). Clinical presentation with palpitation and/or syncope was uncommon, however, 7 patients (44%) had non sustained VT and/or >500 VES/24 h and 2 (12.5%) presented with sustained VT. Of 15 *FLNC* null variant carriers who had cardiac MRI, the majority ($n = 10$, 67%) showed late gadolinium enhancement (LGE). Characteristic ECG and CMR images from a *FLNC* variant carrier are shown in Fig. 2.

3.3. Immunohistochemical analysis of fixed myocardial tissue

Histological examination of eleven cardiac specimens from sudden death victims (numbered 1 to 11, Appendix Table A4) carrying *FLNC* mutations was performed at post mortem. Mean weight was 471.3 ± 58.9 g. All but two cases had normal internal left ventricular measurements (mean LV diameter 37.4 ± 11.0 mm). Wall thickness was within normal limits in all hearts (11–13 mm).

Evidence of fibrosis was present in both ventricles in ten samples; fibrofatty replacement was evident in three samples whilst four specimens showed signs of fibrosis and inflammation, mainly in the left ventricle. Distribution of fibrofatty infiltration in the left ventricle was circumferential in 7 (mesocardial in 4 and subepicardial in 3) and inferolateral subepicardial in 4 cases. Infiltration which was predominant in the inferolateral wall, extended from the basal to the apical segments. Inflammatory infiltrates affecting the left ventricle were multifocal in 2 and extensive in another 2. There was only one specimen (case no 9) with remarkable inflammatory infiltrates in the right ventricle, which also had extensive left involvement. The same sample had no evidence of fibrosis at PM, however, fat infiltration was present. Characteristic histology images are shown in Appendix Figure A2.

Cardiac specimens used for immunohistochemistry experiments originated from ACM patients with *FLNC* variants who had suffered

sudden cardiac death. Those included three deletions and eight single nucleotide substitutions (two splice site, four termination and two missense variants). Two unrelated cases carried the same nonsense mutation: c.5398G > T; p.G1800X. A list of *FLNC* variants in fixed tissue samples is given in Appendix Table A4.

Immunoreactive signal for filamin C was strong and indistinguishable from controls in RV samples from ten ACM cases but it was found to be reduced in LV specimens from all eleven cases. The signal for plakoglobin was strong and indistinguishable from controls in nine cases in both RV and LV samples. Junctional signal for Cx43 was reduced in two RV samples and six LV samples. Moreover, signal for the desmosomal protein desmoplakin was found to be reduced at cell-cell junctions in eight RV samples and five LV samples. In contrast, GSK3 β was present in the cytosol in all *FLNC* cases examined as in control myocardium samples. Finally, immunoreactive signal for SAP97 appeared reduced in the majority of RV and LV samples whilst in two cases this protein was only detected in the sarcomere. Characteristic confocal microscopy images from case no 6 are displayed in Fig. 3. Immunohistochemistry data from RV and LV specimens from all eleven cases are summarised in Appendix Figure A3.

4. Discussion

For the first time we performed clinical characterization of *FLNC* variants in an ACM cohort; previous studies have focused on pure DCM or DCM with an arrhythmogenic component [8–10]. We observed marked phenotypic differences in ACM associated with *FLNC* null variants compared to classic ARVC caused by desmosomal gene mutations.

Repolarization (e.g. T wave inversion) and depolarization (such as prolonged terminal activation duration and epsilon waves) abnormalities are considered typical diagnostic features for classic forms of ARVC [6]. However, in our *FLNC* cohort only three patients (19%) had Task Force diagnostic ECG repolarization and depolarization abnormalities. In contrast, the majority of *FLNC* null variant carriers (69%) had ECG repolarization and depolarization abnormalities, such as right bundle branch block (RBBB) and loss of inferior R waves, which, in isolation, are not considered diagnostic criteria [6]. Similarly, standard echocardiographic imaging has been shown to detect structural abnormalities in the majority of ARVC patients [14] but 69% of our cases had no detectable echocardiographic disease features. Moreover, the most striking observation was that MRI showed the presence of LGE with preserved ventricular function in all index cases and the majority of gene positive family members, a clinical feature which is not currently a diagnostic criterion for ARVC [6]. Consequently, in these cases, strict adherence to the Task Force diagnostic criteria, can lead to individuals at risk being incorrectly classified as either unaffected or being at low risk of complications. This highlights the importance of genetic evaluation of asymptomatic family members and the need of more detailed phenotyping targeting recognized features of particular subtypes of ACM. In this study familial evaluation limited to ECG and echocardiography would not have identified the majority of at-risk individuals whereas significant abnormalities were detected with ECG monitoring and CMRI, for example individuals IV:1 (Family A) and II:1 and III:4 (Family C).

In summary, we present the clinical phenotype of *FLNC* families with index cases who fulfil Task Force diagnostic criteria for ARVC. It is characterized by predominant LV involvement; frequently non-diagnostic electrocardiography and echocardiography; frequent ventricular ectopy or non-sustained VT on 24-h Holter monitoring and fibrosis (late gadolinium enhancement) on MRI. Notably there is a high incidence of adverse cardiovascular events, highlighted in our cohort with a family history of multiple sudden cardiac death victims at a young age. This clinical pattern appears similar to emerging experience of other genetically determined arrhythmogenic cardiomyopathies caused by mutations in TMEM43, phospholamban, desmin and lamin A/C [15–18]. All may present with life threatening arrhythmia, myocardial

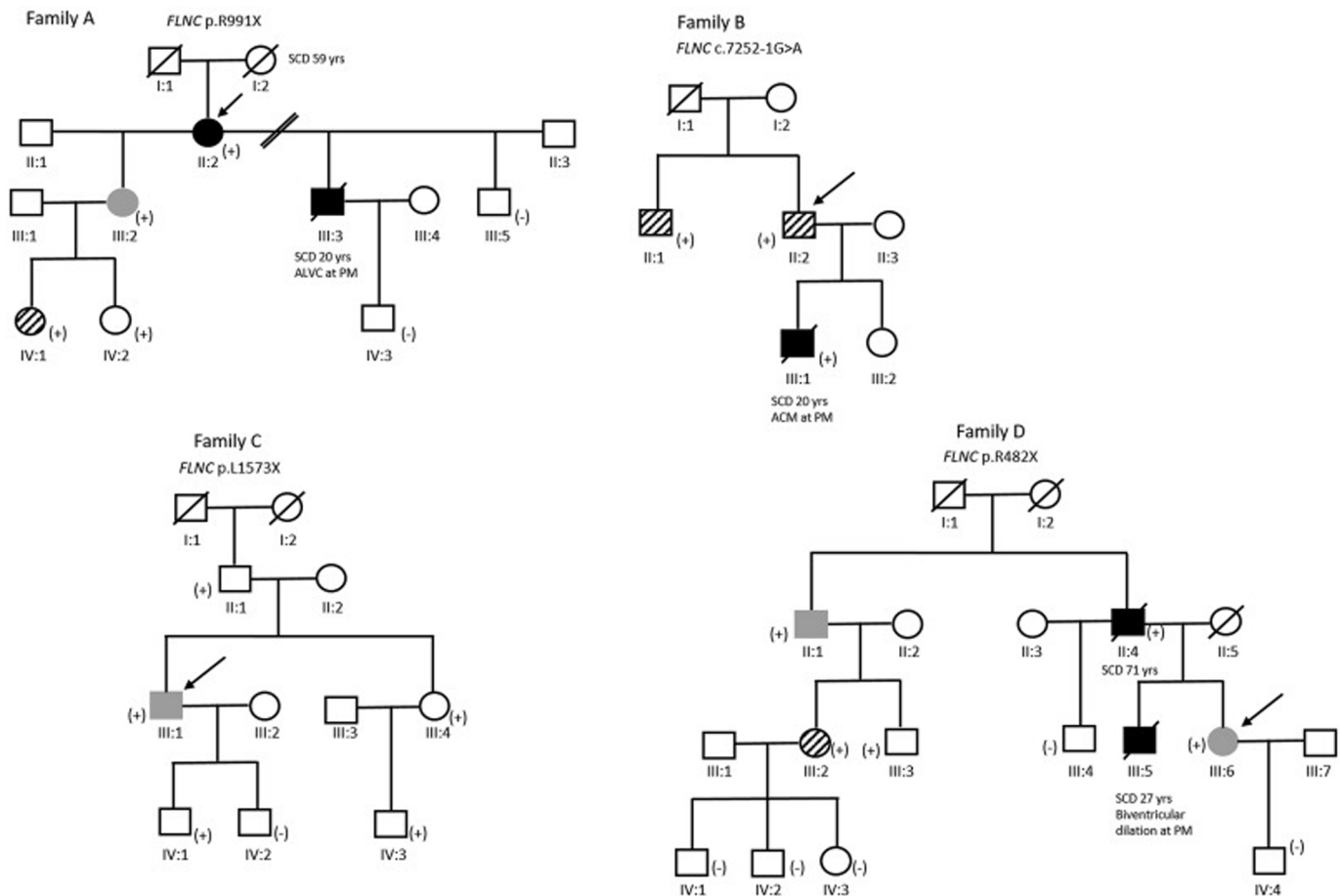


Fig. 1. Pedigrees of ACM families with *FLNC* variants. Squares indicate males; circles, females; slashes, deceased individuals; black symbols, definite diagnosis of ARVC based on current Task Force diagnostic criteria [6] or evidence of ARVC at post mortem; grey symbols, borderline diagnosis of ARVC; hatched symbols, gene positive individuals with possible diagnosis of ARVC; (+), positive genotype for *FLNC* variant; (–), negative genotype for *FLNC* variant; Arrows indicate the index case in each family. ALVC, arrhythmogenic left ventricular cardiomyopathy; PM, post mortem; SCD, sudden cardiac death. Gene negative individuals with a possible diagnosis of ARVC based solely on family history are depicted as unaffected.

structural abnormalities, usually predominantly of the left ventricle, though patients have been reported who fulfil Task Force diagnostic criteria. This highlights the need for evolution of the current classification with use of the term ‘arrhythmogenic cardiomyopathy’ which incorporates ARVC as well as other inherited and acquired forms of ACM. The recent Heart Rhythm Society guidelines for the diagnosis and management of arrhythmogenic cardiomyopathy recognize this evolving scenario [1].

Previous studies have highlighted the importance of immunohistochemistry of cardiac tissue from mutation carriers in investigating the disease mechanisms related to ACM [19,20]. In this study, we sought to characterize the molecular profile of fixed RV and LV specimens from ACM sudden death cases. It has been previously shown that filamin C displays a strong localisation at the intercalated disc that decreases or is completely absent in patients with restrictive and dilated cardiomyopathy carrying *FLNC* mutations [8,21]. Here, staining for *FLNC* showed a decreased immunoreactive signal intensity in the left ventricle in all eleven ACM cases highlighting a predominant left ventricle disease pattern associated with mutations in this gene. This is consistent with a recent study that reported reduced immunohistochemical staining signal for filamin C in left ventricle samples from an arrhythmogenic DCM patient who carried the p.G1891Vfs61X mutation [10].

It is now well established that in ARVC plakoglobin translocates from the intercalated discs to intracellular pools [19], an observation that is considered as a “hallmark” of disease pathogenesis [22]. However, the

signal for plakoglobin was strong and indistinguishable from controls in nine cases (82%) examined in our *FLNC* cohort in both left and right ventricular samples. Interestingly, signal for plakoglobin was decreased in both RV and LV specimens carrying the two missense variants (p.K35N and p.T160K). However, at present, the significance of this finding is unclear. Similar to plakoglobin mislocalization, the enzyme GSK3 β is re-distributed from the cytosol to the intercalated disc in classic ARVC [23]. However, none of the eleven *FLNC* cases examined showed this re-distribution.

Immunoreactive signal for the major gap junction protein Cx43 is usually significantly depressed at cardiac intercalated discs in patients with ARVC [23]. In our *FLNC* cohort, junctional signal for Cx43 was reduced only in two (20%) RV and six LV (60%) cases. Considering the advanced disease state and predominant LV involvement in all our *FLNC* cases, it is unclear whether Cx43 remodelling played a primary role in ACM pathogenesis or was a result of the histological changes in the myocardium. The signal for the desmosomal protein desmoplakin was found to be reduced at cell-cell junctions mainly in RV samples (80%) and when DSP staining intensity was reduced in the left ventricle, the corresponding RV signal for the same case was also reduced. Altered desmoplakin localisation has been reported in left dominant arrhythmogenic cardiomyopathy [24] and, as our *FLNC* cases had a predominantly left dominant pattern of disease, the observed reduction of desmoplakin signal is in line with this phenotype.

SAP97 is a membrane-associated guanylate kinase reported to show consistently decreased immunohistochemistry staining intensity in

Table 1
Clinical characteristics of *FLNC* null variant carriers in families A–D.

| Family-Individual | <i>FLNC</i> Genotype | NYHA class/Symptoms | Age | Sex | ECG | Echocardiography | | Arrhythmia | | CMRI | | | | Task Force Diagnostic Criteria (m, M)/Diagnosis |
|-----------------------------|----------------------|---------------------|--------|-----|--|---|----------|--|-------------|----------|-------------|----------|---|---|
| | | | | | | Description | LVEF (%) | 24 h VE count/type of arrhythmia | RV EDV (ml) | RVEF (%) | LV EDV (ml) | LVEF (%) | LGE distribution | |
| Family A II:2 (index case) | p.Arg991X | NYHA II | 76 | F | Permanent AF, low QRS voltage in limb leads | Borderline LV dilatation with mild LV systolic dysfunction | 50 | 19,248 | 146 | 49 | 122 | 41 | Basal lateral LGE | 2 m and 1 M Definite |
| Family A III:2 | p.Arg991X | Asymptomatic | 44 | F | Late potentials Low QRS voltage in limb leads | Normal biventricular size and function | 55–60 | 12,935 | Normal | Normal | 172 | 52 | Normal/No LGE | 1 m and 1 M Borderline |
| Family A IV:1 | p.Arg991X | Palpitations | 20 | F | T-wave inversion inferior leads | Normal biventricular size and function | 55–60 | 69 | 212 | 54 | 206 | 59 | Basal lateral sub-epicardial LGE | 2 m Possible |
| Family A IV:2 | p.Arg991X | Asymptomatic | 18 | F | Unremarkable | Normal biventricular size and function | 55–60 | 1 | 168 | 58 | 184 | 56 | Normal/No LGE | 1 m Unaffected |
| Family B II:1 | c.7252-1G > A | Presyncope | 64 | M | Incomplete RBBB | Normal biventricular size and function | 55–60 | 535 | | | | | | 2 m Possible |
| Family B II:2 (index case) | c.7252-1G > A | Asymptomatic | 62 | M | Low QRS voltage | Normal biventricular size and function | 55–60 | 22 | 210 | 61 | 209 | 65 | Sub-epicardial LGE basal-mid anterolateral and inferolateral walls | 1 M* Possible |
| Family C II:1 | p.L1573X | Asymptomatic | 76 | M | Loss of inferior R waves | Normal biventricular size and function | 59 | 0 | 147 | 67 | 156 | 64 | Basal lateral epicardial LGE | None Unaffected |
| Family C III:1 (index case) | p.L1573X | Syncope | 54 | M | Low QRS voltage in limb leads | Non-dilated LV with mild LV dysfunction RV regional wall motion abnormality (dyskinetic RVOT and RV free wall) | 45–50 | Sustained VT of LBBB morphology with superior axis | 211 | 51 | 183 | 51 | Extensive basal to mid sub-endocardial LGE in the anterolateral and inferolateral walls | 1 m and 1 M Borderline |
| Family C III:4 | p.L1573X | Palpitations | 50 | F | T wave inversion V6 | Normal biventricular size and function | 60 | 166 | Normal | Normal | 112 | 70 | Equivocal basal LGE | 1 m Unaffected |
| Family C IV:1 | p.L1573X | Asymptomatic | 19 | M | Unremarkable | Normal biventricular size and function | 59 | 3 | 180 | 54 | 173 | 57 | Normal/No LGE | None Unaffected |
| Family C IV:3 | p.L1573X | Asymptomatic | 26 | F | Poor R-wave progression in anterior leads | Normal biventricular size and function | 60 | 0 | 141 | 64 | 161 | 60 | Normal/No LGE | None Unaffected |
| Family D II:1 | p.Arg482X | Asymptomatic | 73 | M | Unremarkable | Non-dilated LV and mild LV dysfunction | 45 | 1093 | 141 | 41 | 196 | 48 | Circumferential basal LGE and mid-inferior and inferolateral LGE | 1 m and 1 M Borderline |
| Family D II:4 | p.Arg482X | NYHA II | SCD 71 | M | T-wave inversion V6 | Dilated LV and severe LV dysfunction | 35 | 9249 | Normal | normal | 257 | 52 | Extensive inferior and inferolateral subepicardial basal LGE | 2 m and 1 M Definite |
| Family D III:2 | p.Arg482X | Asymptomatic | 46 | F | Unremarkable | Normal biventricular size and function | 60–65 | 6 Non-sustained VT | 131 | 71 | 149 | 68 | Normal/No LGE | 2 m Possible |
| Family D III:3 | p.Arg482X | Asymptomatic | 43 | M | Unremarkable | Normal biventricular size and function | 60–65 | 3 | 161 | 57 | 146 | 68 | Subtle streak of non-ischaemic LGE in the basal inferolateral wall | 1 m Unaffected |
| Family D III:6 (index case) | p.Arg482X | NYHA II | 50 | F | Low QRS voltage in precordial leads | Borderline LV dilatation with mild to moderate LV systolic dysfunction | 40–45 | 5197 | 227 | 62 | 187 | 62 | Basal inferolateral and inferior wall LGE | 1 m and 1 M Borderline |

AF, atrial fibrillation; CMRI, cardiac magnetic resonance imaging; SCD, sudden cardiac death; ECG, electrocardiogram; EDV, end diastolic volume; EF, ejection fraction; NYHA, New York Heart Association classification; LBBB, left bundle branch block; LGE, late gadolinium enhancement; LV, left ventricle; LVEF, left ventricular ejection fraction; LVIDD, end-diastolic internal dimension; m, minor Task Force ARVC diagnostic criterion; M, major Task Force ARVC diagnostic criterion; RBBB, right bundle branch block; RV, right ventricle; RVEF, right ventricular ejection fraction; RVOT, right ventricle outflow tract; VE, ventricular ectopic; VT, ventricular tachycardia; * one major diagnostic criterion due to family history.

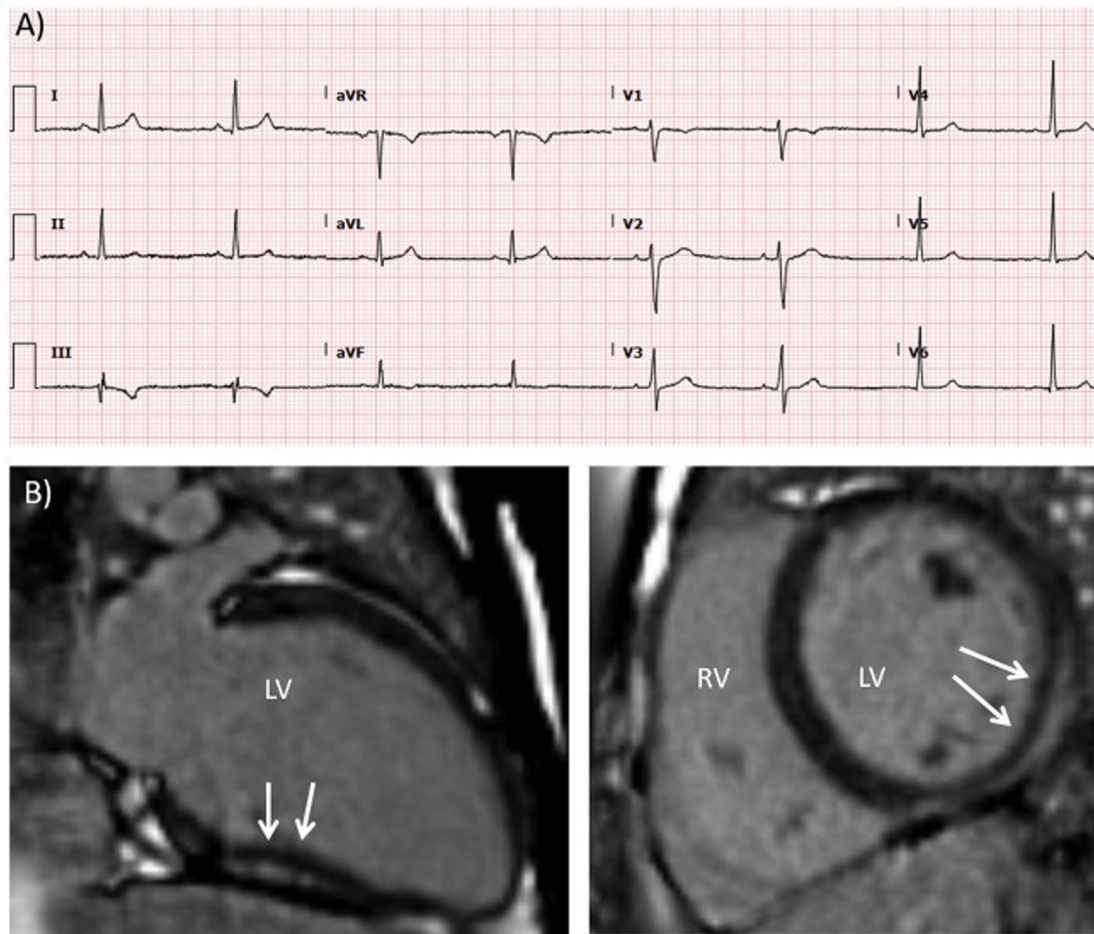


Fig. 2. ECG and cardiac MR images from individual IV:1 (Family A) who was clinically screened due to family history of ACM. A) Electrocardiogram showing inferior lead T-wave inversion (III and aVF). B) CMRI two-chamber view of the left ventricle (left image) and short axis view (right image) showing basal lateral subepicardial late gadolinium enhancement (white arrows).

both the sarcomeric and junctional pools in the myocardium of desmosomal ACM patients independently of the specific causative mutation [25]. In our cohort *SAP97* was reduced in the majority of RV and LV specimens whilst in two cases *SAP97* signal was detectable in the sarcomeres but not at the intercalated discs. This finding is consistent with previous reports on myocardial samples from patients with end-stage ischemic, dilated and hypertrophic cardiomyopathy [25].

Overall, we observed a specific localisation pattern in our cohort for three proteins: *FLNC* signal was reduced in all cases; plakoglobin signal was normal in the large majority of RV and LV specimens and *GSK3β* signal was normal in all cases tested. All these findings point to a disease pattern different to classic ARVC and are consistent with the hypothesis that ACM associated with *FLNC* variants presents with a left dominant arrhythmogenic cardiomyopathy phenotype which may manifest via a different mechanism to typical right ventricular arrhythmogenic cardiomyopathy. Begay et al., 2018 observed similar immunohistochemistry results to our data for a patient with the p.G1891Vfs61X *FLNC* mutation, namely normal plakoglobin immunostaining signal, typical *GSK3β* cytoplasmic distribution and reduced DSP signal compared to control samples [10].

Collectively, our analysis suggests that the clinical and molecular “signature” of *FLNC* cardiomyopathy is distinct to that of ARVC. These results indicate that these two clinical entities reflect different molecular mechanisms of pathogenesis.

4.1. Limitations

This study is limited by the small number of recruited *FLNC* variant carriers which, in part, is attributed to the low frequency of causative *FLNC* variants in ACM and the high genetic heterogeneity that characterizes the disorder. As it is common in studies of cardiomyopathy patients, small family sizes have restricted our ability to perform extensive segregation analysis in all *FLNC* cases.

Immunohistochemical analysis relied on the availability of paraffin fixed tissue. The challenges in collecting human heart samples are well known. Therefore, this study was also hindered by limited quantity of tissue for each case and some samples were not immunostained for a complete set of proteins.

5. Conclusion

ACM related to *FLNC* variants presents with a distinctive phenotype that may not be recognized by current Task Force ARVC diagnostic criteria or by familial evaluation limited to ECG or echocardiography. Physicians should be aware of “non-diagnostic” disease features in asymptomatic gene positive individuals.

The molecular mechanism of pathogenesis of this form of ACM is markedly different to classic ARVC and does not involve mislocalization of plakoglobin or *GSK3β*.

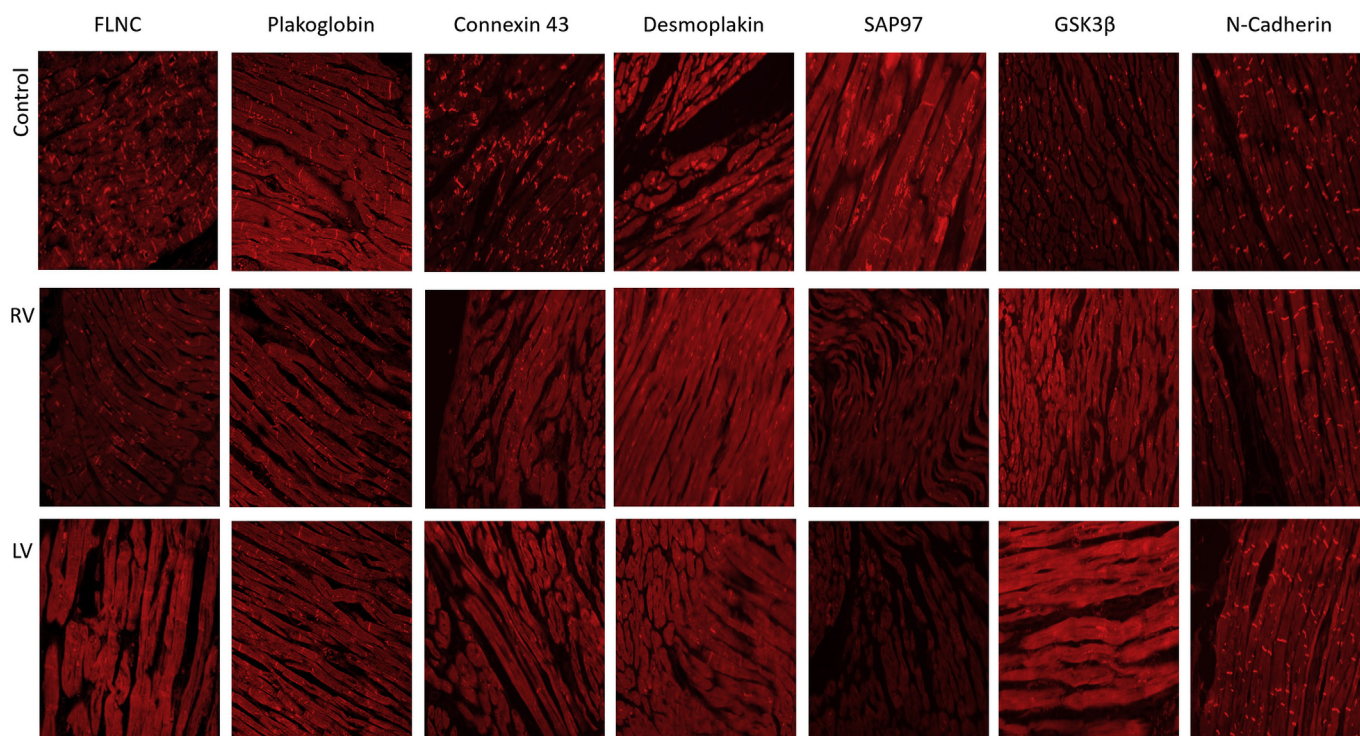


Fig. 3. Immunohistochemistry staining of paraffin-embedded cardiac specimens from case no 6 carrying the p.Y705X FLNC variant. Top panel, control sample; middle panel, RV sample; bottom panel, LV sample. Immunoreactive signal for plakoglobin and GSK3 β at the intercalated discs appear normal compared control samples. Signal for FLNC appears normal in the RV but reduced in the LV. Signal for connexin 43, desmoplakin, and SAP97 is reduced in both RV and LV. N-cadherin is used as a marker of tissue quality and is normal in all specimens.

Funding

This study was funded by Fondation Leducq Transatlantic Networks of Excellence Program grant no 14CVD03 and supported by the National Institute for Health Research University College London Hospitals Biomedical Research Centre in the UK. In Spain, the study was supported by Plan Estatal de I + D + I 2013–2016 – European Regional Development Fund (FEDER) “A way of making Europe”, Instituto de Salud Carlos III, Spain [PI14/01477, PI18/01582 and La Fe Biobank PT17/0015/0043 to E.Z. and PI14/01676, PI18/01231 and the BioBank “Biobanco en Red de la Región de Murcia” (PT17/0015/0038) to J.R.G.].

Declaration of competing interest

None.

Appendix A. Supplementary data

Supplementary data to this article can be found online at <https://doi.org/10.1016/j.ijcard.2019.09.048>.

References

- [1] J.A. Towbin, W.J. McKenna, D.J. Abrams, M.J. Ackerman, H. Calkins, F.C.C. Darrieux, et al., 2019 HRS Expert Consensus Statement on Evaluation, Risk Stratification, and Management of Arrhythmogenic Cardiomyopathy, *Heart Rhythm*, 2019.
- [2] M. Sekiguchi, O. Kinoshita, [From arrhythmogenic right ventricular dysplasia/cardiomyopathy (ARVD/ARVC) to a broader concept of ABCDE syndrome], *Nihon Kyobu Rinsho* 58 (2000) 108–116.
- [3] C. Basso, D. Corrado, G. Thiene, Arrhythmogenic right ventricular cardiomyopathy: what's in a name? From a congenital defect (dysplasia) to a genetically determined cardiomyopathy (dystrophy), *Am. J. Cardiol.* 106 (2010) 275–277.
- [4] C. Basso, B. Bauce, D. Corrado, G. Thiene, Pathophysiology of arrhythmogenic cardiomyopathy, *Nat. Rev. Cardiol.* 9 (2011) 223–233.
- [5] D. Corrado, C. Basso, D.P. Judge, Arrhythmogenic Cardiomyopathy, *Circ. Res.* 121 (2017) 784–802.
- [6] F.I. Marcus, W.J. McKenna, D. Sherrill, C. Basso, B. Bauce, D.A. Bluemke, et al., Diagnosis of arrhythmogenic right ventricular cardiomyopathy/dysplasia: proposed modification of the task force criteria, *Circulation* 121 (2010) 1533–1541.
- [7] A.J. Marian, E. van Rooij, R. Roberts, Genetics and Genomics of single-gene cardiovascular diseases: common hereditary cardiomyopathies as prototypes of single-gene disorders, *J. Am. Coll. Cardiol.* 68 (2016) 2831–2849.
- [8] R.L. Begay, C.A. Sharp, A. Martin, S.L. Graw, G. Sinagra, D. Miani, et al., FLNC gene splice mutations cause dilated cardiomyopathy, *JACC Basic. Transl. Sci.* 1 (2016) 344–359.
- [9] M.F. Ortiz-Genga, S. Cuenca, M. Dal Ferro, E. Zorio, R. Salgado-Aranda, V. Climent, et al., Truncating FLNC mutations are associated with high-risk dilated and arrhythmogenic cardiomyopathies, *J. Am. Coll. Cardiol.* 68 (2016) 2440–2451.
- [10] R.L. Begay, S.L. Graw, G. Sinagra, A. Asimaki, T.J. Rowland, D.B. Slavov, et al., Filamin C truncation mutations are associated with arrhythmogenic dilated cardiomyopathy and changes in the cell-cell adhesion structures, *JACC Clin. Electrophysiol.* 4 (2018) 504–514.
- [11] L.R. Lopes, A. Zekavati, P. Syrris, M. Hubank, C. Giambartolomei, C. Dalageorgou, et al., Genetic complexity in hypertrophic cardiomyopathy revealed by high-throughput sequencing, *J. Med. Genet.* 50 (2013) 228–239.
- [12] A. Asimaki, A. Protonotarios, C.A. James, S.P. Chelko, C. Tichnell, B. Murray, et al., Characterizing the molecular pathology of arrhythmogenic cardiomyopathy in patient Buccal Mucosa cells, *Circ. Arrhythm. Electrophysiol.* 9 (2016), e003688.
- [13] S. Richards, N. Aziz, S. Bale, D. Bick, S. Das, J. Gastier-Foster, et al., Standards and guidelines for the interpretation of sequence variants: a joint consensus recommendation of the American College of medical genetics and Genomics and the association for molecular pathology, *Genet. Med.* 17 (2015) 405–424.
- [14] D.M. Yoerger, F. Marcus, D. Sherrill, H. Calkins, J.A. Towbin, W. Zareba, et al., Echocardiographic findings in patients meeting task force criteria for arrhythmogenic right ventricular dysplasia: new insights from the multidisciplinary study of right ventricular dysplasia, *J. Am. Coll. Cardiol.* 45 (2005) 860–865.
- [15] N.D. Merner, K.A. Hodgkinson, A.F. Haywood, S. Connors, V.M. French, J.D. Drenckhahn, et al., Arrhythmogenic right ventricular cardiomyopathy type 5 is a fully penetrant, lethal arrhythmic disorder caused by a missense mutation in the TMEM43 gene, *Am. J. Hum. Genet.* 82 (2008) 809–821.
- [16] P.A. van der Zwaag, I.A. van Rijsingen, A. Asimaki, J.D. Jongbloed, D.J. van Veldhuisen, A.C. Wiesfeld, et al., Phospholamban R14del mutation in patients diagnosed with dilated cardiomyopathy or arrhythmogenic right ventricular cardiomyopathy: evidence supporting the concept of arrhythmogenic cardiomyopathy, *Eur. J. Heart Fail.* 14 (2012) 1199–1207.

- [17] J.P. van Tintelen, I.C. Van Gelder, A. Asimaki, A.J. Suurmeijer, A.C. Wiesfeld, J.D. Jongbloed, et al., Severe cardiac phenotype with right ventricular predominance in a large cohort of patients with a single missense mutation in the DES gene, *Heart Rhythm* 6 (2009) 1574–1583.
- [18] G. Quarta, P. Syrris, M. Ashworth, S. Jenkins, K. Zuborne Alapi, J. Morgan, et al., Mutations in the Lamin A/C gene mimic arrhythmogenic right ventricular cardiomyopathy, *Eur. Heart J.* 33 (2012) 1128–1136.
- [19] A. Asimaki, H. Tandri, H. Huang, M.K. Halushka, S. Gautam, C. Basso, et al., A new diagnostic test for arrhythmogenic right ventricular cardiomyopathy, *N. Engl. J. Med.* 360 (2009) 1075–1084.
- [20] L.M. Fidler, G.J. Wilson, F. Liu, X. Cui, S.W. Scherer, G.P. Taylor, et al., Abnormal connexin 43 in arrhythmogenic right ventricular cardiomyopathy caused by plakophilin-2 mutations, *J. Cell Mol. Med.* 13 (2009) 4219–4228.
- [21] N.R. Tucker, M.A. McLellan, D. Hu, J. Ye, V.A. Parsons, R.W. Mills, et al., Novel mutation in FLNC (filamin C) causes familial restrictive cardiomyopathy, *Circ. Cardiovasc. Genet.* 10 (2017).
- [22] A. Asimaki, A.G. Kleber, J.E. Saffitz, Pathogenesis of arrhythmogenic cardiomyopathy, *Can. J. Cardiol.* 31 (2015) 1313–1324.
- [23] A. Asimaki, J.E. Saffitz, Remodeling of cell-cell junctions in arrhythmogenic cardiomyopathy, *Cell Commun. Adhes.* 21 (2014) 13–23.
- [24] S.R. Kaplan, J.J. Gard, L. Carvajal-Huerta, J.C. Ruiz-Cabezas, G. Thiene, J.E. Saffitz, Structural and molecular pathology of the heart in Carvajal syndrome, *Cardiovasc. Pathol.* 13 (2004) 26–32.
- [25] A. Asimaki, S. Kapoor, E. Plovie, A. Karin Arndt, E. Adams, Z. Liu, et al., Identification of a new modulator of the intercalated disc in a zebrafish model of arrhythmogenic cardiomyopathy, *Sci. Transl. Med.* 6 (2014) 240ra274.