

Journal section: Oral Surgery

Publication Types: Research

Traumatic bone cyst: A retrospective study of 21 cases

Isidoro Cortell-Ballester ¹, Rui Figueiredo ², Leonardo Berini-Aytés ³, Cosme Gay-Escoda ⁴

¹ DDS. Resident of the Master of Oral Surgery and Implantology. University of Barcelona Dental School

² DDS. Associate Professor of Oral Surgery. Professor of the Master of Oral Surgery and Implantology. University of Barcelona Dental School. UB-IDIBELL Research group

³ DDS, MD, PhD. Assistant Professor of Oral Surgery. Professor of the Master of Oral Surgery and Implantology. Dean of the University of Barcelona Dental School. UB-IDIBELL Research group

⁴ MD, DDS, PhD. Chairman of Oral and Maxillofacial Surgery. Director of the Master of Oral Surgery and Implantology. University of Barcelona Dental School. Oral and maxillofacial surgeon of the Teknon Medical Center, Barcelona (Spain). UB-IDIBELL Research group

Correspondence:

Centro Médico Teknon
C/ Vilana 12
08022 – Barcelona (Spain)
cgay@ub.edu

Cortell-Ballester I, Figueiredo R, Berini-Aytés L, Gay-Escoda C. Traumatic bone cyst: A retrospective study of 21 cases. Med Oral Patol Oral Cir Bucal. 2009 May 1;14 (5):E239-43.
<http://www.medicinaoral.com/medoralfree01/v14i5/medoralv14i5p239.pdf>

Received: 16/06/2008
Accepted: 26/09/2008

Article Number: 5123658845 <http://www.medicinaoral.com/>
© Medicina Oral S. L. C.I.F. B 96689336 - pISSN 1698-4447 - eISSN: 1698-6946
eMail: medicina@medicinaoral.com
Indexed in:
-SCI EXPANDED
-JOURNAL CITATION REPORTS
-Index Medicus / MEDLINE / PubMed
-EMBASE, Excerpta Medica
-SCOPUS
-Indice Médico Español

Abstract

Objective: To describe the clinical and radiological characteristics, and surgical findings of traumatic bone cysts.

Study Design: A retrospective observational study was made of 21 traumatic bone cysts. The diagnosis was based on the anamnesis, clinical examination, and complementary tests. Panoramic and periapical X-rays were obtained in all cases, together with computed tomography as decided by the surgeon. A descriptive statistical analysis was made of the study variables using the SPSS v12.0 for Windows.

Results: There was a clear female predominance (14:7). The mean age was 26.5 years (range 8-45 years). The cysts in all cases constituted casual findings during routine radiological exploration. In those cases where computed tomographic images were available, preservation of the vestibular and lingual cortical layers was observed. Five of the 21 patients (23.8%) reported a clear antecedent of traumatism in the affected zone. All the lesions were subjected to surgery, and the cavities were found to be vacant in 90.5% of the cases. In only two patients were vascular contents seen within the cavity. Two of the patients presented postoperative paresthesia of the inferior dental nerve that subsided within two weeks. The 19 patients in whom adequate postoperative follow-up proved possible all showed complete bone healing.

Conclusions: Traumatic bone cysts were a casual finding. During the surgery, most cases showed to be vacant cavity without an epithelial lining. Careful curettage of the lesion favors progressive bone regeneration, offering a good prognosis and an almost negligible relapse rate. Other treatment options only would be justified in cases of relapse.

Key words: Traumatic bone cyst, mandibular pseudocysts.

Introduction

In 1929, Lucas and Blum (1) for the first time described traumatic bone cyst (TBC) as a separate disease entity. However, it was not until 1946 that the diagnostic criteria of this cyst were established. These criteria remain valid today, and comprise a generally single lesion without an epithelial lining, surrounded by bony walls and either lacking contents or containing liquid and/or connective tissue (2).

In the classification of the World Health Organization (WHO), TBCs are included in the group of bone-related lesions, together with the aneurysmal bone cyst, ossifying fibroma, fibrous dysplasia, osseous dysplasia, central giant cell granuloma and cherubism (3).

TBCs have been referred to in different ways: hemorrhagic bone cyst, simple bone cyst, hemorrhagic traumatic bone cyst, progressive bone cavity, unicameral bone cyst, extravasation cyst, and idiopathic bone cavity – thus showing that the underlying etiopathogenesis is not clear. Different causal factors have been proposed: bone tumor degeneration, altered calcium metabolism, low-grade infection, local alterations in bone growth, venous obstruction, increased osteolysis, intramedullary bleeding, local ischemia, or a combination of such factors (4, 5). It has been suggested that any form of trauma, including tooth extraction could give rise to a cyst of this kind (6). Although, it is important to underline that the TBCs' etiology is unknown.

These lesions are generally diagnosed in patients under 30 years, with an approximate mean age of 20 years (7). No differences in terms of gender are usually observed (8, 9), and the cysts tend to be asymptomatic, being diagnosed in routine studies.

Radiologically, TBCs appear as a radiotransparent image with irregular or scalloped but well defined margins. The size is variable, and a fine sclerotic margin is sometimes seen (Figure 1). When the radiotransparency affects the interdental bone spaces, the lesion appears lobular or scalloped (10). Root reabsorption is rare, and can cause disappearance of the hard lamina in 16-62% of cases (3). Swei et al. (11) showed the absence of water-air levels in these cysts, comparing their characteristics in conventional X-rays and in computed tomography scans (CT). This circumstance was traditionally accepted as part of the X-ray features of these lesions.

Histologically, the lesion appears as a cancellous bone cavity that may be vacant and without a lining, or present a thin connective tissue layer with a scant liquid content. In any case, the absence of an epithelial lining is a constant characteristic of these lesions (12).

Surgery is the management of choice, particularly as refers to confirmation of the diagnosis. Simple curettage of the bone walls is performed, with healing after 6-12 months. Clinical and radiological follow-up after surgery is thus indicated (7).

The clinical cases and case series published to date (1, 2, 4-6, 7-9, 12-20) have contributed to establish the clinical and histological characteristics of TBCs. Nevertheless, certain aspects relating to the etiology of these cysts remain unclear, and controversy persists over the course of the lesions after surgical treatment. Some cases of relapse have been documented.

The present study describes the clinical and radiological characteristics, and the surgical findings of traumatic bone cysts in our patients.

Patients and Method

A retrospective study was made of 21 patients diagnosed with TBC and treated in the period 1970-2007 in Vall d'Hebron General Hospital, Granollers General Hospital, and in the context of the Master of Oral Surgery and Implantology of the University of Barcelona Dental School (Barcelona, Spain). In all cases the panoramic X-ray study (carried out for other reasons or as part of the complementary workup of a first clinical appointment) revealed a unilocular radiotransparency located in the mandible. The lesions were of variable size and in some cases appeared between the dental roots. The vitality of the adjacent teeth was preserved, and none of the patients presented symptoms associated with the lesion. Surgery was scheduled after clinical and radiological confirmation of the diagnosis.

The following data were recorded: patient age and gender, symptoms, history of orofacial trauma, radiological characteristics, shape, size and location, the results of complementary tests, treatment and outcome.

The results were processed using the Statistical Package for the Social Sciences version 12.0 (SPSS; Chicago, IL, USA; license of the University of Barcelona).

Results

There was a clear female predominance (14:7), and the mean age was 26.5 years (range 8-45 years). Since none of the patients presented signs or symptoms, the lesions in all cases constituted casual findings in the course of routine radiological explorations (Figure 1). Five of the patients (23.8%) reported a clear antecedent of trauma in childhood, without associated fractures or loss of teeth. In 19 cases the teeth adjacent to the lesion remained vital. All of the TBCs were located in the mandible: 9 on the right side, 9 on the left side, and three in the region of the chin symphysis. The area of the second premolar was the most affected location (Figure 1). Table 1 shows the anatomical distribution of the cysts.

Treatment was surgical in all cases, revealing vacant cyst cavities in 19 of the 21 lesions (Figure 2). The remaining two cysts contained scant material described in the histological study as corresponding to vascular connective tissue, without an epithelial component. Surgery was carried out under general anesthesia with

Table 1. Anatomical distribution of the traumatic bone cysts. All lesions are located in the mandible.

Location	No. of cases	%
Chin symphysis	3	14.3
Lower first premolar	1	4.8
Lower second premolar	12	57.1
Lower first molar	3	14.3
Ascending ramus	2	9.5
Total	21	100%

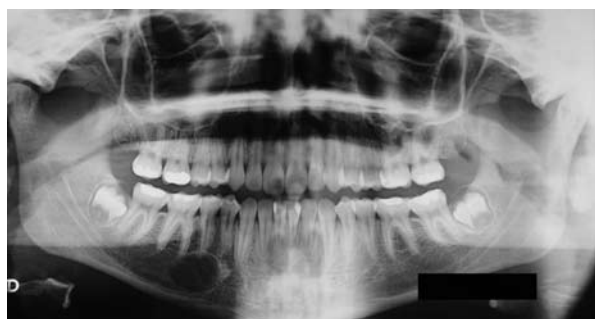

Fig. 1. Panoramic X-ray view. Traumatic bone cyst located in the region of the right lower second premolar.

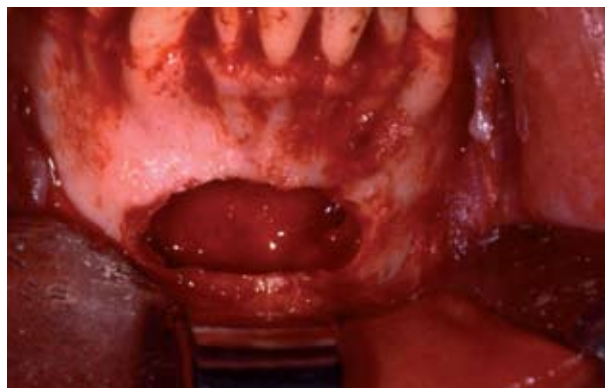

Fig. 2. Surgical approach to a traumatic bone cyst located in the region of the chin symphysis. The cavity of the lesion is seen to be vacant.

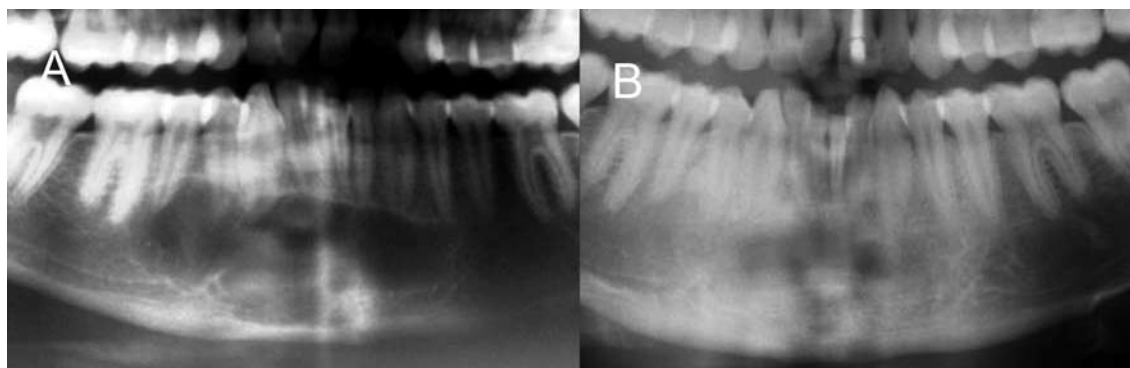


Fig. 3. Traumatic bone cyst located in the region of the chin symphysis. A) Panoramic X-ray detail at the time of diagnosis. B) Panoramic X-ray detail one year after surgical treatment. Complete bone regeneration is observed.

nasotracheal intubation (8 cases), local anesthesia and sedation via the intravenous route (12 cases) and under locoregional anesthesia (1 case). The surgical technique consisted of the raising of a mucoperiosteal flap with access to the lesion by means of an external cortical layer osteotomy using a handpiece and number 8 tungsten carbide drill, careful curettage of the cavity, and flap repositioning and suture without any type of filler material. In the immediate postoperative course, antibiotic coverage was provided (amoxicillin 750 mg, one tablet every 8 hours during 7 days [Clamoxyl®, Glaxo-SmithKline, Madrid, Spain]), together with nonsteroidal antiinflammatory treatment (ibuprofen 600 mg, one tablet every 8 hours during 5 days [Algiadin®, Esteve, Barcelona, Spain]), an analgesic (metamizol 575 mg, one tablet every 4 hours during 4 days [Nolotil®, Boehringer Ingelheim, Sant Cugat del Vallés, Spain]), and local cold application. The patients were instructed on careful oral hygiene. Following treatment, the 19 cases that completed the programmed follow-up all showed adequate healing, with progressive bone regeneration evidenced by the radiological controls (after 2 and 6 months), to complete healing between 8 and 15 months after surgery (Figure 3). The size of the lesions varied from 2.5 x 3 cm to 4 x 3.5 cm in area. In those cases where a CT study was available, no perforation of the vestibular or lingual cortical layers was observed. The fact that in most cases a close relation to the inferior dental nerve was observed explains the appearance of two cases of nerve damage, resulting in lip and chin paresthesia that subsided within two weeks.

Discussion

Traumatic bone cysts are generally detected in patients in the second and third decades of life, though they can also be found in older age groups (12). This agrees with our own observations, since there was a clear predominance of individuals in the 10-20 years age range, and

we also registered patients over 40 years of age. Another interesting epidemiological aspect is the gender distribution. Most reviews describe no important gender differences, though in our series – and in coincidence with Peñarrocha et al. (13) – we observed a clear female predilection.

Only 23.8% of the patients of our series reported antecedents of orofacial traumatism. Other investigators such as Copete et al. (14) and Peñarrocha et al. (13) recorded equally low figures. The importance of trauma in the development of TBCs may thus appear questionable. However, of the pathogenic hypothesis of TBCs evaluated by Howe (5), the most widely accepted mechanism involves microtrauma and subsequent intramedullary bleeding, with osteoclastic activity and the elimination of trabeculae within the cancellous bone compartment, thus giving rise to a cystic cavity. Other authors point to trauma in the form of third molar extraction as a possible cause of TBC (6, 15). Although, as we have noted before, the physiopathologic mechanism that leads to the development of this lesion is unknown.

The location is exclusively mandibular and above the inferior dental canal. The most frequent locations in our patient series were the region of the second premolar, the ascending mandibular ramus and the chin symphysis – in coincidence with the reports of other series (13, 14). The adjacent teeth tend to remain vital, and a lack of vitality appears to be neither a cause nor a result of the presence of these lesions (16).

Clinically, our patients were asymptomatic up until the time of surgery, and the cysts constituted casual findings in all cases – in agreement with the observations in the literature (8, 13).

Radiologically, the images corresponding to our 21 cases did not differ significantly from the classical descriptions: radiotransparencies of variable size and shape, sometimes appearing between the dental roots.

In only 9.52% of the cases could a histological evaluation be made of the material obtained, revealing the presence of vascular connective tissue without evidence of an epithelial component. This suggests that the absence of epithelial tissue is one of the most characteristic features of these lesions.

It has been suggested that TBCs may undergo spontaneous resolution (17). However, an expectant approach to management cannot be recommended, in view of the possibility of diagnostic error. Failure to provide treatment moreover may lead to additional complications such as pathological mandibular fracture (18).

In our series, treatment consisted of careful curettage of the bone walls, with satisfactory results characterized by progressive bone regeneration and the absence of relapses. Nevertheless, Kuttner et al. (19) and Baqain et al. (20) reported two cases of relapse following surgical curettage. In both cases, re-treatment of the

lesions sufficed to solve the problem. Other alternative treatments such as filling of the cavity with bovine lyophilized bone or the introduction of autologous blood with bone from the patient or hydroxyapatite, may be of interest in those cases where conventional management fails (21). These techniques may be particularly useful when osseointegrated implant rehabilitation of the affected zone is required. However, the introduction of radiopaque materials in the cavity may complicate the diagnosis of possible lesion relapse.

Based on the results obtained in our study, it can be concluded that TBC in most cases constitutes a casual finding, and its etiology is until today, unknown. At surgery, the cavity is usually seen to be vacant and without an epithelial lining. Careful curettage of the lesion favors progressive bone regeneration, offering a good prognosis and an almost negligible relapse rate. We thus consider that other treatment options only would be justified in cases of relapse.

References

1. Lucas CD, Blum T. Do all cysts in the jaws originate from the dental system?. *J Am Dent Assoc.* 1929;16:647-61.
2. Rushton MA. Solitary bone cysts in the mandible. *Br Dent J.* 1946; 81:37-49.
3. Barnes L, Eveson JW, Reichart P, Sidransky D, editors. *World Health Organization Classification of Tumours. Pathology and Genetics of Head and Neck Tumours.* Lyon: IARC Press; 2005.
4. Cowan CG. Traumatic bone cysts of the jaws and their presentation. *Int J Oral Surg.* 1980;9:287-91.
5. Howe GL. 'Haemorrhagic cysts' of the mandible. I. *Br J Oral Surg.* 1965;3:55-76.
6. Pogrel MA. A solitary bone cyst possibly caused by removal of an impacted third molar. *J Oral Maxillofac Surg.* 1987;45:721-3.
7. Freedman GL, Beigleman MB. The traumatic bone cyst: a new dimension. *Oral Surg Oral Med Oral Pathol.* 1985;59:616-8.
8. Hansen LS, Sapone J, Sproat RC. Traumatic bone cysts of jaws. *Oral Surg Oral Med Oral Pathol.* 1974;37:899-910.
9. Sapone J, Hansen LS. Traumatic bone cysts of jaws: diagnosis, treatment, and prognosis. *Oral Surg Oral Med Oral Pathol.* 1974;38:127-38.
10. Toller PA. Radioactive isotope and other investigations in a case of haemorrhagic cyst of the mandible. *Br J Oral Surg.* 1964;2:86-93.
11. Swei Y, Tanimoto K, Wada T. Simple bone cyst. Evaluation of contents with conventional radiography and computed tomography. *Oral Surg Oral Med Oral Pathol.* 1994;77:296-301.
12. Saito Y, Hoshina Y, Nagamine T, Nakajima T, Suzuki M, Hayashi T. Simple bone cyst. A clinical and histopathologic study of fifteen cases. *Oral Surg Oral Med Oral Pathol.* 1992;74:487-91.
13. Peñarrocha-Diago M, Sanchis-Bielsa JM, Bonet-Marco J, Minguéz-Sanz JM. Surgical treatment and follow-up of solitary bone cyst of the mandible: a report of seven cases. *Br J Oral Maxillofac Surg.* 2001;39:221-3.
14. Copete MA, Kawamata A, Langlais RP. Solitary bone cyst of the jaws: radiographic review of 44 cases. *Oral Surg Oral Med Oral Pathol Oral Radiol Endod.* 1998;85:221-5.
15. Xanthinaki AA, Choupis KI, Tosios K, Pagkalos VA, Papanikolaou SI. Traumatic bone cyst of the mandible of possible iatrogenic origin: a case report and brief review of the literature. *Head Face Med.* 2006;2:40.
16. Schofield ID. An unusual traumatic bone cyst. *Oral Surg Oral Med Oral Pathol.* 1974;38:198-203.

17. Sapp JP, Stark ML. Self-healing traumatic bone cysts. *Oral Surg Oral Med Oral Pathol.* 1990;69:597-602.
18. Hughes CL. Hemorrhagic bone cyst and pathologic fracture of mandible: report of case. *J Oral Surg.* 1969;27:345-6.
19. Kuttenger JJ, Farmand M, Stöss H. Recurrence of a solitary bone cyst of the mandibular condyle in a bone graft. A case report. *Oral Surg Oral Med Oral Pathol.* 1992;74:550-6.
20. Baqain ZH, Jayakrishnan A, Farthing PM, Hardee P. Recurrence of a solitary bone cyst of the mandible: case report. *Br J Oral Maxillofac Surg.* 2005;43:333-5.
21. Dellinger TM, Holder R, Livingston HM, Hill WJ. Alternative treatments for a traumatic bone cyst: a longitudinal case report. *Quintessence Int.* 1998;29:497-502.