

Journal section: Oral Surgery

Publication Types: Review

Erupted odontomas: A report of three cases and review of the literature

Gabriel Serra-Serra ¹, Leonardo Berini-Aytés ², Cosme Gay-Escoda ³

¹ Resident of the Master of Oral Surgery and Implantology. University of Barcelona Dental School.

² DDS, MD. Professor of Oral Surgery. Professor of the Master of Oral Surgery and Implantology. Dean of the University of Barcelona Dental School.

³ DDS, MD, PhD. Chairman of Oral and Maxillofacial Surgery. Director of the Master of Oral Surgery and Implantology. University of Barcelona Dental School. Oral and maxillofacial surgeon of the Teknon Medical Center, Barcelona (Spain)

Correspondence:

Centro Médico Teknon

C/ Vilana 12

08022 – Barcelona (Spain)

cgay@ub.edu

Serra-Serra G, Berini-Aytés L, Gay-Escoda C. Erupted odontomas: A report of three cases and review of the literature. *Med Oral Patol Oral Cir Bucal*. 2009 Jun 1;14 (6):E299-303.

<http://www.medicinaoral.com/medoralfree01/v14i6/medoralv14i6p299.pdf>

Received: 24/07/2008

Accepted: 21/12/2008

Article Number: 5123658890 <http://www.medicinaoral.com/>
© Medicina Oral S. L. C.I.F. B 96689336 - pISSN 1698-4447 - eISSN: 1698-6946
eMail: medicina@medicinaoral.com

Indexed in:

- SCI EXPANDED
- JOURNAL CITATION REPORTS
- Index Medicus / MEDLINE / PubMed
- EMBASE, Excerpta Medica
- SCOPUS
- Indice Médico Español

Abstract

Introduction: Odontomas are benign odontogenic tumors composed of enamel, dentine, cement and pulp tissue. They are usually clinically asymptomatic, but often associated with tooth eruption disturbances. In exceptional cases the odontoma erupts into the mouth. The present study reports three cases of odontomas erupted into the oral cavity and reviews the literature.

Clinical cases: The first case was an 11-year-old girl with impacted 4.6 associated to a radiopaque mass measuring about 2 cm in diameter. The histological diagnosis was complex odontoma. A clinical and radiological follow-up of 4.6 was carried out until its spontaneous eruption. The second case was a 26-year-old male presenting a hard, yellowish-brown mass located distal to the upper left second molar. Computed tomography confirmed the presence of a radiopaque lesion, and the histopathological study confirmed a complex odontoma. The third patient was a 27-year-old male reporting tongue irritation due to tooth eruption in the inferior lingual region. A periapical radiograph revealed a mixed radiopaque lesion associated to impacted 3.2. The histological report in this case indicated a compound odontoma.

Discussion: Odontomas erupting into the oral cavity are rare. The first case was published in 1980, and since then only 17 cases have been reported in the literature. Eight of the 17 cases were complex odontomas; the rest were compound odontomas. Pain, swelling and infection were the most common symptoms, and 13 cases presented an impacted tooth associated with the lesion.

Keywords: *Odontoma, erupted odontomas, odontogenic tumor, delayed tooth eruption.*

Introduction

Odontomas are benign tumors of odontogenic origin combining mesenchymal and epithelial dental elements. Histologically, they are composed of different dental tissues, including enamel, dentine, cement and, in some cases, pulp tissue (1,2). According to the latest classification of the World Health Organization (WHO, 2005), two types of odontomas can be found: complex odontomas and compound odontomas – the latter being twice as common as the former.

Compound odontomas are usually located in the anterior sector of the upper maxilla, over the crowns of unerupted teeth, or between the roots of erupted teeth. The lesions are usually unilocular and contain multiple radiopaque, miniature tooth-like structures known as denticles (3).

Complex odontomas in turn are found in the posterior mandibular sector, over impacted teeth, and can reach several centimeters in size. Radiologically, these lesions manifest as a radiopaque solid mass with occasional nodular elements, and surrounded by a fine radiotransparent zone. The lesions are unilocular and are separated from the normal bone by a well defined corticalization line. No individual tooth-like structures are seen (1).

Epidemiologically, odontomas are the most frequent odontogenic tumors, with an incidence of 22-67% of all maxillary tumors. The lesions are more often found in children and adolescents, and there are scant differences between males and females (2).

Clinically, these are asymptomatic lesions often associated to alterations in permanent or temporary tooth eruption. The diagnosis is usually established on occasion of routine radiological studies (panoramic and/or intraoral X-rays), or on evaluating the cause of delayed tooth eruption.

The treatment of choice is surgical removal of the lesion in all cases, followed by histopathological study to confirm the diagnosis (1-3).

An exceptional circumstance is spontaneous eruption of an odontoma into the oral cavity, i.e., exposure of the tumor through the oral mucosa. This situation can cause pain, inflammation of the adjacent soft tissues, or infection associated with suppuration (4-6). The present study describes three patients with odontomas erupted into the mouth, and offers a review of the literature, with a view to defining the principal characteristics of these lesions.

Clinical Cases

Case 1: An 11-year-old girl without systemic disease was referred to the Service of Oral Surgery (University of Barcelona, Spain) by her dentist for evaluation of a radiopaque lesion in the retromolar region of the fourth quadrant that caused retention and impaction of the lower right first molar (4-6). The patient reported

pain and slight swelling of the soft tissues in the retromolar region. Compilation of the case history and clinical examination revealed an ulcerated zone in the molar region of the fourth quadrant, with the exposure of a hard, yellowish-brown and dental tissue-like lesion (Fig.1). The complementary radiological tests showed impaction of the lower right first molar, with agenesis of the second and third molars of this same quadrant (4-8). Coronal to 4.6 we identified a well defined radiopaque image measuring about 2 cm in diameter, and compatible with a complex odontoma. The differential diagnosis contemplated radiopaque lesions located at pericoronal level: adenomatoid odontogenic tumor, calcifying epithelial odontogenic tumor, odontoameloblastoma, ameloblastic fibrodentinoma, and osteoma.

The treatment consisted of surgical removal of the lesion, followed by histopathological study, which confirmed the diagnosis of complex odontoma. Relocation of 4.6 was carried out in the same surgical step. Clinical and radiological controls were made, and after 8 months the first molar finally reached the occlusal plane without the need for orthodontic traction.

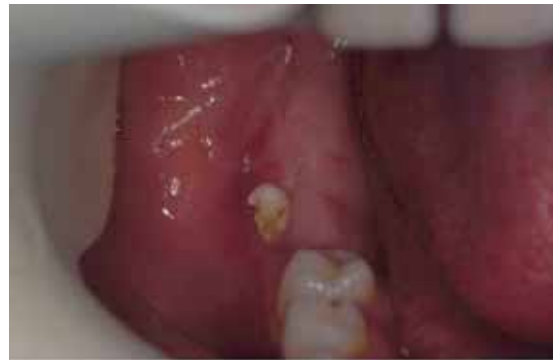

Fig. 1 Intraoral view showing eruption of a fragment of the lesion in the region of the lower right second molar. In addition, 4.6 is seen to be missing (Case 1).

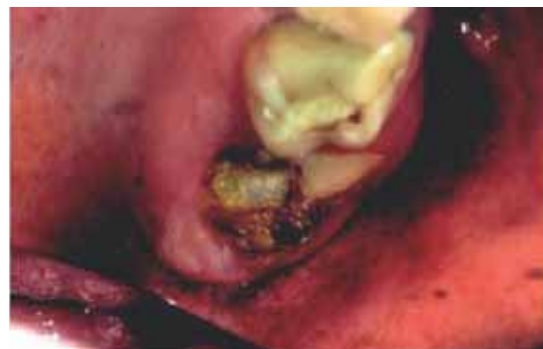

Fig. 2 Intraoral view showing partial eruption of 2.7 (mesial cuspids). Also seen is the distal partial eruption of the lesion (Case 2).

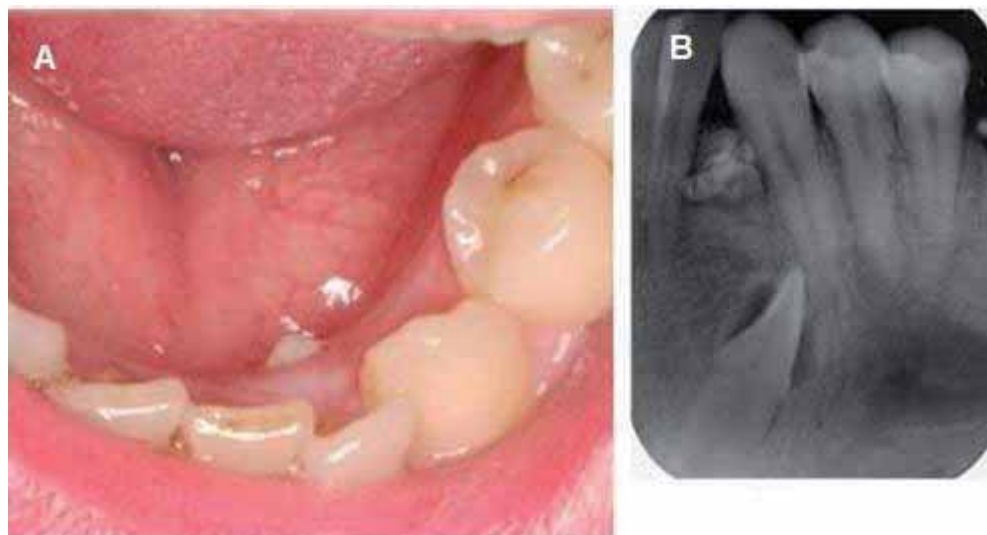


Fig. 3 A) Intraoral view showing the lingual eruption of one of the denticles conforming the compound odontoma. B) Periapical X-ray view showing impacted 3.2 apical to the erupted odontoma (Case 3).

Case 2: A 26-year-old male with no personal or family disease antecedents of interest reported to our Service for evaluation of the removal of the upper left second molar. Clinical intraoral examination revealed a tumor lesion in the second quadrant. The lesion was of hard consistency, yellowish-brown in color and measured about 10 mm in diameter, with a calcified appearance and an irregular and porous surface. It was associated to the distal surface of the upper left second molar, which was only partially erupted due to the retention exerted by the lesion (Fig.2). Complementary studies were requested (panoramic and periapical X-rays, and computed tomography) to establish the precise location and extent of the lesion, as well as its relations to the nearby anatomical structures. Both the panoramic X-ray study and computed tomography scan showed a close relationship between the tumor and the maxillary sinus and roots of the second molar.

Following surgical resection of the odontoma-like lesion and the extraction of 2.7, the specimen was subjected to histological study. Microscopically, the tumor was composed of a disorderly combination of dental tissues in which dentine, enamel, cement and pulp tissue were clearly identified, together with some odontoblastic cells, confirming the diagnosis of complex odontoma.

Case 3: A 27-year-old male reported for evaluation of the removal of an impacted lower left lateral incisor, for orthodontic reasons. The history revealed osteogenesis imperfecta and breathing difficulties that had been surgically resolved by means of a rhinoseptoplasty in 2003. The patient reported discomfort of the tongue mucosa and irritation of the tip of the tongue due to eruption of a tooth at the level of 3.2. Clinical examination showed

the lingual eruption of a small tooth, similar to a conical supernumerary tooth, between 3.1 and 3.3 (Fig.3). There was no inflammation, pain or infection, or erythema or ulceration of the floor of the mouth or tongue. The study was complemented by panoramic and periapical X-ray evaluation of the zone, which revealed the impaction of 3.2 associated to a mixed radiographic image located between the roots of 3.1 and 3.3, and which caused divergence of the roots. The differential diagnosis comprised ameloblastic fibroodontoma, odontoma, peripheral osteoma and supernumerary tooth. Treatment consisted of the surgical removal of 3.2, with resection-biopsy of the lesion. The piece was composed of 5 miniature teeth, and the histological study confirmed the diagnosis of compound odontoma.

Discussion

Odontomas are the most frequent benign odontogenic tumors in oral pathology. They are generally asymptomatic and constitute casual findings in the course of routine radiological studies, particularly in the second and third decades of life (1,2,7). Some sign and/or symptom is occasionally seen – the most common condition being delayed tooth eruption (3,8). There are two types of odontomas: complex odontomas and compound odontomas – the latter being twice as frequent as the former. Compound odontomas show a predilection for the anterior sector of the upper maxilla, while complex odontomas are typically found in the posterior mandibular region (1,7).

The treatment of choice is surgical removal of the lesion in all cases, followed by histopathological study to confirm the diagnosis.

These are generally intrabony lesions, though in exceptional cases the odontoma may spontaneously erupt into the oral cavity (6,9). The first case of an erupted odontoma was described in 1980 by Rumel et al. (10), and since then only 17 cases have been documented in the literature (Table 1). On including our three patients, 12 (60%) of the global series of 20 cases correspond to females and 7 (35%) to males. In one case patient age and sex were not determined. The mean patient age was 25.35 years, thus confirming preferential presentation of these lesions between the second and third decades of life (1,3,11).

Of the 20 reported cases of erupted odontoma, 9 corresponded to compound odontomas and 11 to complex odontomas.

These are usually asymptomatic lesions, and in most cases they are associated to alterations in permanent or temporary tooth eruption. The incidence of this association ranges from 41% according to Katz (12) in a series of 396 odontomas to 87% according to Tomizawa et al. (3). The three cases in our study all showed delayed eruption, and all of the odontomas were located coronal to the affected tooth. Impaction and/or altered eruption occurs because the odontoma obstructs the eruptive trajectory of the teeth (9,13-15). Of the remaining 17 erupted odontomas published to date, 9 (12 in total; 60%) presented an associated impacted tooth (2,4-6, 10,13,16-18).

There is no general agreement on the best management approach for impacted teeth associated to odontomas (6,11). The treatment options comprise surgical extraction, fenestration and posterior orthodontic traction, or simple observation with periodic clinical and radiological controls, to evaluate the course of these teeth (2,12,14,19). In our first patient (case 1), the lesion was surgically removed, with slight repositioning of the impacted tooth 4.6, which after 8 months finally reached the occlusal plane without the need for orthodontic traction. This was probably attributable to the preserved eruptive capacity of impacted teeth in young patients. In our second patient (case 2) extraction of 2.7 proved necessary, since it was in intimate contact with the complex odontoma, and it was not possible to preserve the tooth during surgical removal of the tumor. Finally, in our third patient (case 3), extraction of 3.2 was carried out, since it was located very deep in relation to the occlusal plane, and moreover there was not enough space for repositioning the tooth in the dental arch via relocation and/or orthodontic-surgical treatment.

Of the 9 erupted odontomas associated to impacted teeth reported in the literature, extraction of the tooth was carried out in four cases (2,4,5,13). In three cases the tooth could be positioned in the dental arch either spontaneously or through fenestration and posterior orthodontic traction (6,16,17). The treatment used in the

last two cases is not known (10,18). Morning (20), in a study of 42 odontomas associated to impacted teeth, found 44% of these teeth to erupt spontaneously after removal of the odontoma. The rest of the teeth required fenestration to complete eruption into the mouth. Hisatomi et al. (11) reported that such impacted teeth tend to erupt, regardless of the degree of root formation. Thus, the treatment of choice for these impacted teeth associated to odontomas appears to be removal of the lesion with preservation of the impacted tooth. The latter in turn require clinical and radiological follow-up for at least one year. If no changes in the position of the tooth are seen during this period, fenestration followed by orthodontic traction is indicated. Extraction should be carried out in those cases where the tooth is ectopic or heterotopic, with morphological alterations, or presenting cystic lesions (3,6,14).

Lastly, it should be commented that although odontomas are usually asymptomatic, their eruption into the mouth can give rise to pain, inflammation and infection. One of our three cases was asymptomatic, while the other two patients reported pain, swelling and tongue irritation. These signs and symptoms are similar to those reported in literature for erupted odontomas. In some cases facial asymmetry (13), halitosis (16), malocclusions (18,21) and recurrent infections were recorded (17). Ferrer et al. (4) reported the case of a 22-year-old woman with several infection episodes associated to an erupted odontoma in the upper maxilla, with malaise, fever, pain, inflammation and suppuration. Following broad spectrum antibiotic treatment of the infection (amoxicillin and clavulanic acid, clindamycin), surgical resection of the odontoma was carried out, together with the removal of 2.7. The clinical manifestations subsequently disappeared.

Unlike with most odontomas, the above case shows that odontomas which erupt into the oral cavity can give rise to moderately serious conditions – particularly in the presence of overinfection of the lesion.

In conclusion, odontomas rarely erupt into the mouth and tend to be associated to impacted teeth. Despite their benign nature, however, their eruption into the oral cavity can give rise to pain, inflammation and infection. The treatment of choice is surgical removal of the odontoma, followed by histological analysis. In the case of odontomas associated to impacted teeth, the latter should be preserved in wait of spontaneous eruption, or alternatively fenestration followed by orthodontic traction are indicated.

References

1. Philipsen H, Reichart P, Praetorius F. Mixed odontogenic tumours and odontomas. Considerations on interrelationship. Review of the literature and presentation of 134 new cases of odontomas. *Oral Oncol.* 1997;32:86-99.
2. Amado Cuesta S, Gargallo Albiol J, Berini Aytés L, Gay Escoda

- C. Revisión de 61 casos de odontoma. Presentación de un odontoma complejo erupcionado. *Med Oral*. 2003;8:366-73.
3. Tomizawa M, Otsuka Y, Noda T. Clinical observations of odontomas in Japanese children: 39 cases including one recurrent case. *Int J Paediatr Dent*. 2005;15:37-43.
 4. Ferrer M, Silvestre F, Estelles E, Grau D. Infección recurrente de un odontoma complejo tras su apertura a la boca. *Med Oral*. 2001;6:269-75.
 5. Junquera L, de Vicente J, Roig P, Olay S, Rodríguez Recio O. Odontoma intraóseo erupcionado: Una infrecuente patología. *Med Oral Patol Oral Cir Bucal*. 2005;10:248-51.
 6. Litonjua L, Suresh L, Valderrama L, Neiders M. Erupted complex odontoma: A case report and literature review. *Gen Dent*. 2004;52:248-51.
 7. Patiño Illa C, Berini Aytés L, Sánchez Garcés M, Gay Escoda C. Odontomas complejos y compuestos: Análisis de 47 casos. *Arch Odontostomatol*. 1995;11:423-9.
 8. Cildir S, Sencift K, Olgac V, Sandalli N. Delayed eruption of a mandibular primary cuspid associated with compound odontoma. *J Contemp Dent Pract*. 2005;6:152-9.
 9. Ragalli C, Ferreira J, Blasco L. Large erupting complex odontoma. *J Oral Maxillofac Surg*. 2000;29:373-4.
 10. Rumel A, de Fritas A, Birman E, Tannous L, Chacon P, Borkas S. Erupted complex odontoma. Report of a case. *Dentomaxillofac Radiol*. 1980;9:5-9.
 11. Hisatomi M, Asaumi J, Konouchi H, Honda Y, Wasaka T, Kishi K. A case of complex odontoma associated with an impacted lower deciduous second molar and analysis of the 107 odontomas. *Oral Dis*. 2002;8:100-5.
 12. Katz R. An analysis of compound and complex odontomas. *J Dentist Child*. 1989;56:445-9.
 13. Vengal M, Arora H, Ghosh S, Pai K. Large erupting complex odontoma: A case report. *J Can Dent Assoc*. 2007;73:169-73.
 14. Frank C. Treatment options for impacted teeth. *J Am Dent Assoc*. 2000;131:623-32.
 15. Ozec I, Kilic E, Yeler H, Goze F, Yeler D. Large complex odontoma associated with a primary tooth. *Quintessence Int*. 2007;38:521-4.
 16. Gomel M, Seckin T. An erupted odontoma: A case report. *J Oral Maxillofac Surg*. 1989;47:999-1000.
 17. Al-Sahhar W, Putrus S. Erupted odontoma. *Oral Surg Oral Med Oral Pathol*. 1985;59:225-6.
 18. López-Areal L, Silvestre-Donat F, Gil-Lozano J. Compound odontoma erupting in the mouth: 4 - year follow-up of a clinical case. *J Oral Pathol Med*. 1992;21:285-8.
 19. Liu J, Hsiao C, Chen H, Tsai M. Orthodontic correction of a mandibular first molar deeply impacted by an odontoma: A case report. *Quintessence Int*. 1997;28:381-5.
 20. Morning P. Impacted teeth in relation to odontomas. *Int J Oral Surg*. 1980;9:81-91.
 21. Nik-Hussein N, Majid Z. Erupted compound odontoma. *Ann Dent*. 1993;52:9-11.