

Journal section: Oral Surgery

Publication Types: Case Report

Florid osseous dysplasia: Report of a case presenting acute cellulitis

Poramate Pitak-Arnnop^{1,2}, Kittipong Dhanuthai³, André Chaine⁴, Jacques-Charles Bertrand⁴, Chloé Bertolus⁴

¹ Department of Oral, Craniomaxillofacial and Facial Plastic Surgery, Faculty of Medicine, University Hospital of Leipzig, Leipzig, Germany

² Laboratory of Medical Ethics and Legal Medicine, Faculty of Medicine, University Paris 5 (René Descartes), Paris, France

³ Department of Oral Pathology, Faculty of Dentistry, Chulalongkorn University, Bangkok, Thailand

⁴ Department of Maxillofacial Surgery, AP-HP, Pitié-Salpêtrière University Hospital, Faculty of Medicine, University Paris 6 (Pierre et Marie Curie), Paris, France

Correspondence:

Klinik und Poliklinik für Mund-,
Kiefer- und Plastische Gesichtschirurgie,
Universitätsklinikum Leipzig AöR,
Nürnberger Str. 57, 04103 Leipzig, Deutschland
poramate.pitakarnnop@gmail.com

Pitak-Arnnop P, Dhanuthai K, Chaine A, Bertrand JC, Bertolus C. Florid osseous dysplasia: Report of a case presenting acute cellulitis. Med Oral Patol Oral Cir Bucal. 2009 Sep 1;14 (9):e461-4.
<http://www.medicinaoral.com/medoralfree01/v14i9/medoralv14i9p461.pdf>

Received: 16/01/2009
Accepted: 20/03/2009

Article Number: 2669 <http://www.medicinaoral.com/>
© Medicina Oral S. L. C.I.F. B 96689336 - pISSN 1698-4447 - eISSN: 1698-6946
eMail: medicina@medicinaoral.com
Indexed in:
-SCI EXPANDED
-JOURNAL CITATION REPORTS
-Index Medicus / MEDLINE / PubMed
-EMBASE, Excerpta Medica
-SCOPUS
-Indice Médico Español

Abstract

In this review, we examined a 45-year-old Asian man who had been diagnosed with florid osseous dysplasia (FOD) of the mandible and acute perimandibular cellulitis. This presentation occurred after a history of off-and-on swellings of the jaw and multiple treatments received at another hospital. An aggressive resection of the jaw was planned; however, the patient denied the treatment and came to our clinic to seek a second opinion. The patient was successfully treated by conservative surgery and antibiotic treatment with preservation of the jaw integrity and the mandibular neurovascular canal. Intraoperatively, a piece of a calcified mass was removed and submitted for histopathological examination. The specimen showed woven bone and densely sclerotic mass of calcified materials exhibiting reversal lines and inflammatory cell infiltration of the connective tissue. The definitive diagnosis was FOD with a secondary infection. Treatments for FOD were discussed.

Key words: Florid osseous dysplasia, fibro-osseous lesion, jaw disease, cellulitis.

Introduction

The World Health Organization (WHO) workshop group on head and neck tumours has classified osseous dysplasia (OD) into 4 subtypes based upon the extent and radiographic appearances: periapical osseous dysplasia in the anterior mandible, focal osseous dysplasia or focal cemento-osseous dysplasia (FCOD) in a posterior region of the jaws, florid osseous dysplasia (FOD) involving many quadrants of the jaws, and familial gigantiform cementoma (1). FOD is a benign jaw lesion and discovered most fre-

quently in the mandible of middle-aged black females. Many authors use its several synonyms, such as multiple enostoses, multiple cemento-ossifying fibromas, multiple periapical osteofibromatosis, florid cemento-osseous dysplasia and gigantiform cementoma (1-3). This amalgamates FOD with other diseases of bone, thereby confounding the literature.

In general, FOD lesions are usually asymptomatic and detected incidentally during routine dental examination (1,3,4). This article reports a case of 45-year-old Asian man presenting with FOD of the mandible and acute

perimandibular cellulitis, which was successfully treated by conservative surgery and antibiotic treatment.

Case Report

A 45-year-old Asian man presented with acute right perimandibular cellulitis with a history of off-and-on swellings and multiple treatments. A few months ago, the last exacerbation was treated by incision and drainage in another hospital. An aggressive resection of the jaw was planned in case of refractory infection, and then the patient came to our clinic for a second opinion. He was otherwise healthy, and denied having numbness of any area of the face. His medical and familial histories were unremarkable.

Head and neck examination revealed no abnormalities other than cellulitis of the right perimandibular space with intra-oral pus discharge, a piece of sequestrum and excessive salivary drooling. He was totally edentulous and did not wear any denture. An area of calcified tissue was observed on the right mandibular alveolar crest. A panoramic film showed a mixed radiopaque-radiolucent lesion with ill-defined borders at the right body of the mandible, and sclerotic bone at the left molar area. (Fig.1A, B) The inferior cortex of the both sides was obliterated. Jaw expansion and disruption, and displacement of the mandibular canal were not found.

Because clinical and radiographic findings were consistent with a benign bone lesion, the patient underwent conservative débridement and peripheral ostectomy of the bony bed via an intra-oral approach, and an antibiotic therapy (amoxicillin 500 mg three time a day for 1 week). Intraoperatively, a piece of a calcified mass with the dimension of approximately 4x3x2 cm³ was removed and submitted for histopathological examination. The mass was easily extirpated with the preservation of surrounding tissues and mandibular neurovascular canal. The postoperative period was uneventful.

Photomicrograph of the specimen showed woven bone and densely sclerotic mass of calcified materials exhibiting reversal lines. (Fig.2A, B) Since the lesions were scattered in both sides of the mandible, the definite diagnosis was FOD with a secondary infection.

Five years after the treatment, the patient's clinical condition remained stable. Neither recurrence of the enucleated lesion nor any symptom of the silent lesion of the left mandible has been observed. However, he denied further dental rehabilitation.

Ethical approval of this article was not required by the Committee of Human Subject Protection in Biomedical Research of Paris and its suburb (Comité de Protection des Personnes [CPP] de l'île de France), whilst we followed the national guideline "Déclaration de Commission Nationale de l'Informatique et des Libertés (CNIL)" in order to protect patient confidentiality in a rare case report.

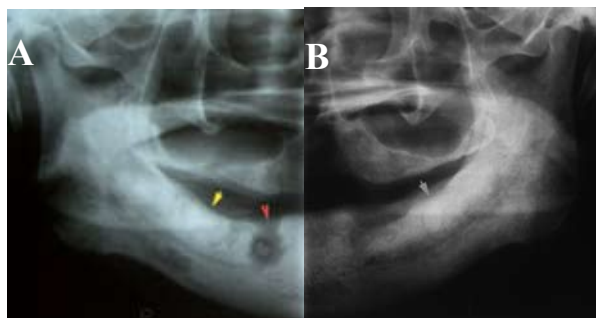


Fig. 1. Parts of panoramic radiographs showing FOD lesions. A: The lesion at the right mandible presented with cellulitis (yellow arrow). A poorly-demarcated radiolucent area close to the right mental foramen corresponded to the purulent discharge (red arrow). B: The silent FOD lesion at the left mandible (grey arrow).

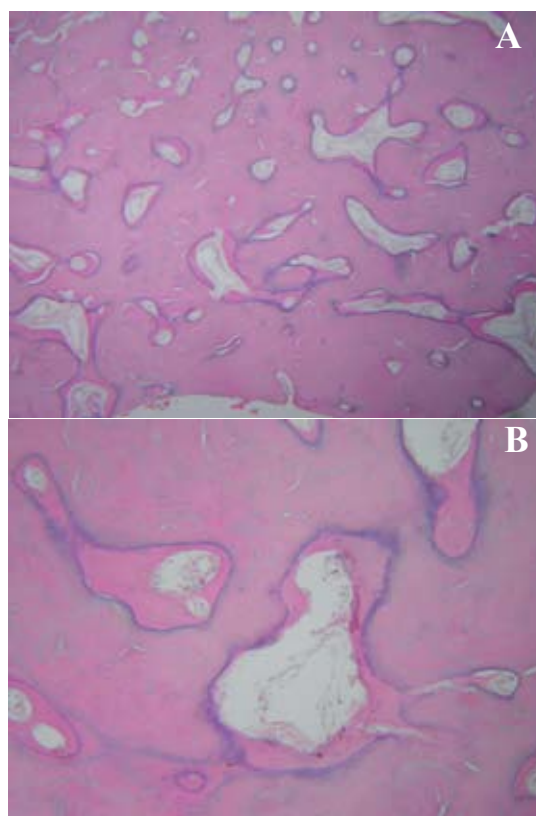


Fig. 2. Photomicrograph showing large sclerotic mass of bone-and cementum-like material in the fibrous connective tissue. (Haematoxylin & eosin stain, original magnification, A: 4x and B: 10x).

Discussion

The WHO classifies FOD as a type of fibro-osseous lesions (other two are cemento-osseous fibroma [COF] and fibrous dysplasia) (5). The definite diagnosis of these 3 diseases cannot be reached by clinical ground, but only by histopathologic examination.

Microscopically, FOD comprises trabeculae of bone-or cementum-like structures in cellular fibrous connective tissue background. When the lesion matures, dense, acellular and avascular calcified tissues is markedly found (1-3). Su et al. (6) analysed 241 FCOD cases, and suggested that this form of OD contained uncapsulated, multiple tiny fragments. Free haemorrhage, sinusoidal vascularity and loose collagen fibres predominantly interspersed throughout the lesion between thick curvilinear ('ginger root') bony trabeculae. In contrast, osteoblastic rimming of the trabeculae and ovoid cementoid deposits, which were characteristic of COF, were absent in cases of FCOD. The histological features of FCOD may be applied for FOD because they are in the same entity (1).

It should be emphasised that symmetrical and/or multifocal distribution of the lesions within the jaw is a unique clue for the diagnosis of FOD. However, a unilateral fashion often occurs in younger populations. It may result from the discrepancy in the stage of development and/or the degree of involvement before the lesion matures (3,4).

The main differential diagnoses for FOD are chronic diffuse sclerosing osteomyelitis (CDSO) and Paget's disease of bone (PD) (2,3,7). CDSO usually produces signs and symptoms of infection and it is usually limited in extent, whereas FOD is usually asymptomatic and affects at least 2 or more quadrants of the jaw. PD is often polyostotic lesions involving several bones of the body apart from the jaw, and produces biochemical changes such as elevated alkaline phosphatase. In the maxillofacial region, PD shows the characteristic cotton wool radiographic appearance and loss of dental lamina dura. Moreover, PD patients often have bone pain and neurological symptoms. Conversely, FOD is strictly confined to only tooth-bearing area of the jaw and does not elicit biochemical changes, and most of the patients are asymptomatic unless secondarily infected (2,3,7).

The aetiology of FOD remains unknown; nonetheless, it may be associated with reactive or dysplastic changes of the periodontal ligament to chronic, low-grade injury (8) FOD can occur in any area of the jaw. Initially, FOD evolves from a radiolucent or mottled, mixed radiopaque-radiolucent lesion. Its mineralisation increases with time, and the same lesion may appear in various stages depending upon the degree of calcification. Immature FOD usually presents with densely sclerotic lobular or irregular-shaped radiopacities with a radiolucent halo which separates the lesion from the surrounding bone. With maturation, FOD involves multiple

sites throughout the jaw. On occasion, a radiopaque lesion blends with the adjacent bone (1,3,4).

Although the disease may be totally asymptomatic, some patients present with pain, swelling, purulent discharge and sequestrum formation (4). It can be hypothesised that the aetiological factors such as wearing dentures, tooth extraction, make avascular tissue of the lesion exposed to the oral cavity. Traumatic episodes of this calcified tissue cause retrograde infection, and subsequent cellulitis, sequestration or even osteomyelitis. The hypovascular nature of the disease increases the severity when infection of the lesion occurs (3,4). In severe cases, mandibular nerve paresthesia and/or jaw expansion, albeit rare, may be found (3).

A solitary bone cyst (traumatic bone cavity) coexists in some FOD cases (9). A possible explanation for this occurrence may be that the fibro-osseous proliferation obstructs the interstitial fluid drainage, resulting in cystic degeneration within the FOD lesion (9). This collision phenomenon necessitates surgical exploration and histopathological examination to establish a definite diagnosis. Malignant fibrous histiocytoma developing in FOD was also reported in one patient, but the prognosis was good (10).

FOD is a benign, non-neoplastic, self-limiting lesion. Hence, complete surgical removal of the entire disease which may cause discontinuity of the jaw is absolutely unnecessary. An asymptomatic individual requires only a periodic follow-up to ensure that there is no change in the disease behaviour. Surgical management is indicated only for a progressive lesion that produces orofacial disfigurement. Since tissue diffusion of the lesion is commonly poor, antibiotic treatment may be ineffective for an infected lesion (1-3).

An accurate differential diagnosis is important. When the diagnosis of FOD is suspected, an incisional biopsy and/or elective tooth extraction in the unaffected (asymptomatic) area of the lesion is best avoided because they may cause acute (and possibly, serious) infection in that region. Notable, progressive bone atrophy under a denture can also create significant clinical problems due to exposure of the lesion. Good oral care to prevent tooth loss, and denture maintenance are, therefore, pivotal (1-3).

References

1. Waldron CA. Fibro-osseous lesions of the jaws. *J Oral Maxillofac Surg.* 1993;51:828-35.
2. Miyake M, Nagahata S. Florid cemento-osseous dysplasia. Report of a case. *Int J Oral Maxillofac Surg.* 1999;28:56-7.
3. Beylouni I, Farge P, Mazoyer JF, Coudert JL. Florid cemento-osseous dysplasia: Report of a case documented with computed tomography and 3D imaging. *Oral Surg Oral Med Oral Pathol Oral Radiol Endod.* 1998;85:707-11.
4. MacDonald-Jankowski DS. Florid cemento-osseous dysplasia: a systematic review. *Dentomaxillofac Radiol.* 2003;32:141-9.
5. Kramer IR, Pindborg JJ, Shear M. The World Health Organization

- histological typing of odontogenic tumours. Introducing the second edition. Eur J Cancer B Oral Oncol. 1993;29B:169-71.
6. Su L, Weathers DR, Waldron CA. Distinguishing features of focal cemento-osseous dysplasias and cemento-ossifying fibromas: I. A pathologic spectrum of 316 cases. Oral Surg Oral Med Oral Pathol Oral Radiol Endod. 1997;84:301-9.
 7. Singer SR, Mupparapu M, Rinaggio J. Florid cemento-osseous dysplasia and chronic diffuse osteomyelitis. Report of a simultaneous presentation and review of the literature. J Am Dent Assoc. 2005;136:927-31.
 8. Coleman H, Altini M, Kieser J, Nissenbaum M. Familial florid cemento-osseous dysplasia--a case report and review of the literature. J Dent Assoc S Afr. 1996;51:766-70.
 9. Wakasa T, Kawai N, Aiga H, Kishi K. Management of florid cemento-osseous dysplasia of the mandible producing solitary bone cyst: report of a case. J Oral Maxillofac Surg. 2002;60:832-5.
 10. Schneider LC, Dolinsky HB, Grodjesk JE, Mesa ML, Doyle JL. Malignant spindle cell tumor arising in the mandible of a patient with florid osseous dysplasia. Oral Surg Oral Med Oral Pathol Oral Radiol Endod. 1999;88:69-73.

Acknowledgement

This article was completed as a partial fulfilment of the requirements for the "Doctorat en sciences" (PhD/DSc) degree at the University Paris 5 (René Descartes) and the "Doktor der Zahnheilkunde" (Dr. med.dent.) degree at the University of Leipzig by the primary author.

Disclosure of potential conflicts of interest

The authors indicate full freedom of manuscript preparation and no potential conflicts of interest.