


Research Article

The Efficacy and Patient Satisfaction with a Mini-Scleral Lens after penetrating Keratoplasty

Cristina Peris-Martínez^{*1,2}, Magdalena Catalán-Gómez¹, Esteban Porcar-Izquierdo³, Juan Carlos Montalt-Rodrigo³, María José Roig-Revert¹

Abstract

Background: To analyse the efficacy and patient satisfaction of fitting a mini-scleral lens (SL) after keratoplasty surgery in patients unsatisfied with their visual outcomes.

Material and Methods: A retrospective chart review of 22 consecutive patients was performed between 2018 and 2019. Demographic data, indications for keratoplasty, ocular parameters, and visual results were evaluated. In addition, subjective visual quality (SVQ) and comfort, complications, daily wear time, and the reason for discontinuing SL wear during the 6-month follow-up were analysed.

Results: Twenty-two eyes of 22 patients (6 females and 16 males; mean age 48.82 ± 17.19 years) were assessed. Keratoconus was the main indication for keratoplasty (9 eyes, 40.9%), followed by corneal opacities (5 eyes), and Fuchs endothelial dystrophy (4 eyes). High refractive anisometropia was found in 14 eyes (63.6%) and 6 eyes presented significant irregular astigmatism. LogMAR visual acuity improved significantly with SL when compared with the best spectacle-correction (mean, 0.12 ± 0.12 vs 0.52 ± 0.33 , respectively; $p < 0.01$). Six patients discontinued SL wear (27.3%). Among the other 16 patients, the mean daily wear time was 11.47 ± 1.52 h; of these, 14 (87.5%) were successfully fitted and enjoyed favourable SVQ and comfort. No significant complications were found during the follow-up period.

Conclusions: Mini-scleral lenses may be a safe and effective alternative for treating complicated eyes after keratoplasty; they may provide optimal visual rehabilitation and/or restore binocular vision with significant efficacy and patient satisfaction.

Keywords: Penetrating keratoplasty; Keratoconus; Irregular astigmatism; Scleral contact lenses

Introduction

Keratoplasty surgery is a procedure in which the damaged cornea is replaced entirely (penetrating keratoplasty) or partially (lamellar keratoplasty) with a donated corneal graft [1,2]. The main indication for keratoplasty is keratoconus, followed by Fuchs endothelial dystrophy, pseudophakic bullous keratopathy, fungal keratitis, corneal scarring and others [2,3]. Despite good graft clarity that can be achieved after keratoplasty, some patients can still present unsatisfactory visual outcomes. For example, a previous study reported that after surgery, 18 out of 104 eyes (17%) proved unsatisfactory with the best spectacle-correction [2]. These patients mainly presented an increase in higher-order aberrations, significant degrees of astigmatism and/

Affiliation:

¹Fundación de Oftalmología Médica (FOM) de la Comunitat, Valenciana, Valencia, Spain

²Faculty of Medicine and Odontology, University of Valencia, Spain

³Department of Optics, Optometry and Vision Sciences, Physics College, University of Valencia, Burjassot, Valencia, Spain

*Corresponding author:

Cristina Peris Martínez, Fundación de Oftalmología Médica (FOM) de la Comunitat, Valenciana, Valencia, Spain

Citation: Cristina Peris-Martínez, Magdalena Catalán-Gómez, Esteban Porcar-Izquierdo, Juan Carlos Montalt-Rodrigo, María José Roig-Revert. The Efficacy and Patient Satisfaction with a Mini-Scleral Lens after penetrating Keratoplasty. Journal of Surgery and Research. 6 (2023): 167-173.

Received: March 17, 2023

Accepted: April 12, 2023

Published: April 27, 2023

or high refractive anisometropia [2-5]. A previous study reported that higher-order aberrations in these cases can be 5.5 times more than normal eyes [5]. Consequently, in these cases, nonsurgical options to achieve visual rehabilitation and binocularity are mainly directed toward fitting rigid gas-permeable lenses [6-23]. These lenses are able to mask higher-order aberrations with the tear film between the posterior surface of the lens and the anterior surface of the cornea [24]. Other previous studies also reported fitting other types of lenses, such as soft and hybrid lenses, although to a lesser extent [25,26]. Previous studies have described different types of rigid gas-permeable lenses (corneal, semi-scleral, and mini or large scleral lenses) fitted on eyes after keratoplasty [6-23]. Firstly, large diameter corneal lenses (10 to 12 mm) were fitted to achieve a better centration [6-10]. These lenses had different back surface designs and/or lens eccentricity, depending on the different corneal profiles [8]. Therefore, the fitting procedure of these special designs (e.g. toric, bitoric, reverse geometry and others) can be difficult and require more time. Moreover, the results in some cases with high astigmatism can be unsuccessful. In recent years, scleral lenses (SL) have gained popularity because the fitting procedure is easier than that of corneal lenses; moreover, as their diameter is large, SL vault the whole cornea [17]. There are different diameter SL available for post-keratoplasty eyes (large and mini-SL). Some previous studies report fitting SL with diameters of 18.50 or 19 mm (large SL); [15,16] however, eye care providers are mainly fitting mini-SL with diameters ranging from 15.80 to 16.50 mm [17-19,23]. For example, a study showed that the mean SL diameter was 16.6 mm (range 15.6 to 18.4 mm) [18]. Recently, a study based its strategy for treating cases of irregular corneas, including post-keratoplasty eyes, with lenses of 16.50 mm in diameter [23]. On the other hand, previous studies reported that visual acuity is significantly improved after fitting SL on post-keratoplasty eyes [15-19], however, little is known in the literature about the efficacy and patient satisfaction (subjective visual quality and comfort) wearing these lenses. In addition, criteria of success were not reported [15,23]. The present study describes the efficacy and patient satisfaction, as well as visual rehabilitation results, success rate, complications and clinical experience when fitting a mini-scleral lens (15.80 to 16.50 mm in diameter) in complicated eyes that have undergone keratoplasty surgery with suboptimal visual outcomes.

Material and Methods

Patients

A retrospective review of clinical data from the records of 22 patients who were fitted with a mini-SL (MSK; Conóptica SL, Hecht Contactlinsen) after keratoplasty was performed. Patients presented unsatisfactory visual outcomes with the best spectacle-correction or other types of contact lenses (except SL). They were selected from a database at Fundación

de Oftalmología Médica (FOM) de la Comunitat Valenciana, between January 2018 and December 2019. A single optometrist at the FOM fitted the lenses in all cases. None of the patients presented ocular-surface diseases, allergies or systemic diseases. Moreover, they did not use medication that would have interfered in contact lens wear, nor had they undergone ocular surgery (except keratoplasty). All patients had consented to the use of their clinical data for research purposes. This study complied with the ethical standards required by the FOM and the University of Valencia, which concurs with the tenets of the Declaration of Helsinki.

Data collection

The data retrieved from medical records included demographic aspects (age and gender), initial diagnosis, previous ocular and contact lens wear history, time elapsed after keratoplasty surgery until fitting contact lenses, and the eye examination values before fitting the lens. The eye examination outcomes assessed were visual acuity with the best spectacle correction, corneal topographic analysis using the Pentacam Eye Scanner (Oculus Inc., Wetzlar, Germany) and visual acuity obtained with the contact lens. Moreover, the SL parameters (such as diameter, back optic zone radius and power), number of visits and lenses required until the SL was optimal for dispense were recorded. Finally, subjective visual quality on a typical five-level Likert scale (1, very poor; 2, poor; 3, neither poor nor favourable; 4, favourable; and 5, very favourable), subjective comfort on a typical five-level Likert scale (1, highly uncomfortable; 2, uncomfortable; 3, neither uncomfortable nor comfortable; 4, comfortable; and 5, very comfortable), daily wear time, complications, and the reason for discontinuing SL wear during the 6-month follow-up were studied.

Criteria of success

With regard to successful fitting criteria (including efficacy and patient satisfaction), complete success was considered when the patient had the following results [27,28]:

- 1) Visual acuity with SL improved two or more decimal lines when compared to the best spectacle-corrected visual acuity;
- 2) Contact lens daily wear time greater than, or equal to, 10h;
- 3) And subjective visual quality and comfort (patient satisfaction) values over 3 (i.e. favourable or very favourable for visual quality, and comfortable or very comfortable for subjective comfort; values 4 or 5 in a range of 1 to 5).

Partial success in fitting was considered when a parameter did not improve when compared to the previous conditions for complete success, and it was deemed unacceptable if two parameters were worse. The wear time criteria as a measure of success was based on the study by Ortenberg et al [15].

Lens Used

The lens in the present study is made of a high-DK gas-permeable material (Hexafocon B) Boston® X02 (Polymer Technology Corp., Wilmington, MA, USA). Its oxygen transmissibility ISO FATT Method: Dk is $141 \times 10^{-11} \text{cm}^3 \text{O}_2(\text{cm})/[(\text{sec.})(\text{cm}^2)(\text{mm Hg})]@35^\circ\text{C}$. The parameters of this lens are the following:

Diameter 12.30 to 16.50 mm (in 0.10-mm steps; standard diameters, 16.50 / 15.80 / 15.20 mm).

Base curves range from 5.00 to 10 mm (in 0.05-mm steps),

Power ranges from +30.00 to -30.00 D (in 0.25-D steps).

As described by the manufacturer, the lens is available in two exclusive profiles, normal MSK (for a prolate cornea) and reverse MSK (for an oblate cornea), so they can be fitted optimally to any corneal profile.

Fitting procedure

All contact lenses were fitted by the trial-lens method. The lens was selected using a specific software developed by the manufacturer (the apex scleral fit). This program shows the profile of the trial lens for four areas in the fitting procedure (the central, para-central and limbal corneal zones, as well as the peripheral or scleral zone). This process makes it easy to modify the sagittal heights in these four areas and it simulates the appropriate fitting. Parameters of corneal topography, eccentricity, visible iris diameter and corneal profile (prolate or oblate) are necessary for this estimation. Once the trial lens had been decided upon (by taking into

account its suitability with the corneal and scleral surfaces), it was inserted in the eye for at least 30 minutes. Then, suitable fitting of the lens on the ocular surface was verified with a slit lamp. In addition, the lens was checked for good position and optimum movement. Finally, an over-refraction was performed which, together with the four parameters of the lens, was necessary in order to manufacture the lenses. At the next visit, the manufactured SL was inserted and allowed to settle on the eye for 2 hours, so that it could be verified that there were no adverse ocular effects or compression on the conjunctival vessels under the contact lens. If the lens did not show an appropriate fit, its parameters or over-refraction were changed. Finally, the patients were instructed in lens care and handling and they were advised to increase lens wear by 1 hour a day, until the following visit 1 week later. After 8 hours of lens wear, the appropriate fit was again evaluated following the same previous procedures (verification of visual acuity, lens position and movement, no corneal staining, and no compression on corneal areas or on the conjunctival vessel under the contact lens; Figure 1). Follow-up appointments were made for 1, 3, and 6 months later.

The mean logMAR visual acuity before keratoplasty was 0.77 ± 22 . After keratoplasty, logMAR visual acuity improved with the best spectacle-correction (0.52 ± 0.33 ; $p = 0.33$). An average of 5 months (range 3 to 8) elapsed before fitting the SL. Once fitted, patients improved up to 0.12 ± 0.12 ($p = 0.01$, when compared to the best spectacle-correction. These outcomes were maintained during the 6-month follow-up (Figure 2).

Table 1: Demographic and clinical data after keratoplasty surgery (N = 22).

Parameters		Patients (%)
Sex	Male	16 (72.7)
	Female	6 (27.3)
Age	< 20 years	1 (4.5)
	21-40 years	5 (22.7)
	41-60 years	9 (40.9)
	> 60 years	7 (31.8)
Refractive error (Spherical Equivalent)	Hyperopia > 10.00 D	2 (9.1)
	Hyperopia (0.00 to +10.00 D)	6 (27.3)
	Low myopia (-0.25 to -6.00 D)	6 (27.3)
	Medium myopia (-6.25 to -10.00 D)	2 (9.1)
	ImpRACTICABLE assessment	6 (27.3)
Corneal astigmatism	0.00-2.00 D	1 (4.5)
	2.25-4.00 D	8 (36.4)
	4.25-6.00 D	5 (22.7)
	> 6.00 D	2 (9.1)
	ImpRACTICABLE assessment	6 (27.3)

Data analysis

Statistical analysis was performed using SPSS 26.0 software (SPSS Inc., Chicago, IL, USA). A nonparametric statistical test (the Wilcoxon test) was used to compare differences in visual acuity before and after keratoplasty with the best spectacle-correction, as well as with the contact lens. All visual acuities were converted to logMAR (logarithm of the minimum angle of resolution) for statistical analysis. The level of statistical significance was taken as $P < 0.05$.

Results

Table 1 shows the demographic and clinical data of the twenty-two post-keratoplasty eyes. The mean \pm SD age of the sixteen Caucasian males and six Caucasian females was 48.82 ± 17.19 years (range 19 to 74 years). All patients underwent keratoplasty in only eye, keratoconus being the main indication, followed by corneal opacities or corneal scars and Fuchs endothelial dystrophy (Table 2). After keratoplasty, high refractive anisometropia was found in fourteen patients (63.6%), and they all had prolate corneas, except three cases (oblate cornea). Moreover, six eyes presented significant irregular astigmatism and/or abnormal corneal profiles; hence, it was difficult to determine refractive status. The mean logMAR visual acuity before keratoplasty was 0.77 ± 0.22 . After keratoplasty, logMAR visual acuity

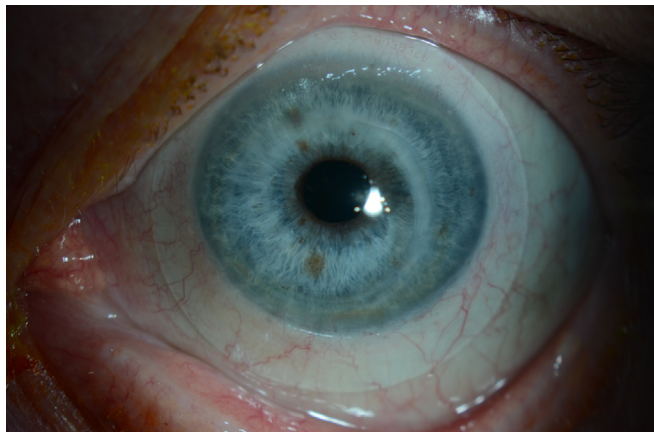

Figure 1: A mini-scleral contact lens fitted after keratoplasty surgery in this study.

Table 2: Indications for keratoplasty surgery (N = 22)

Corneal Anomalies	Patients (%)
Keratoconus	9 (40.9)
Corneal opacities	5 (22.7)
Fuchs endothelial dystrophy	4 (18.2)
Herpes simplex virus	1 (4.5)
Pseudomonas keratitis	1 (4.5)
Reticular corneal dystrophy	1 (4.5)
Corneal perforation	1 (4.5)

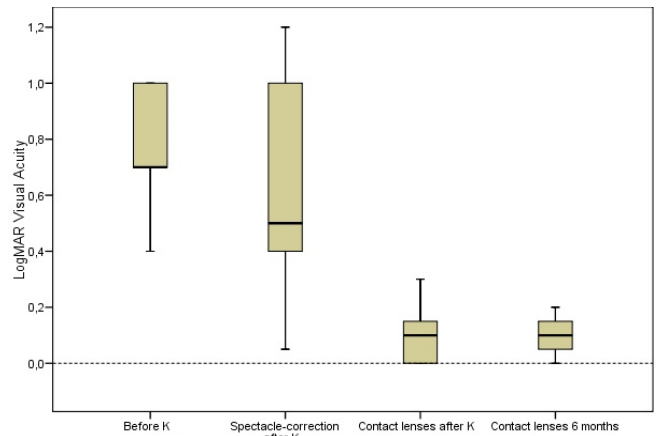


Figure 2: LogMAR visual acuity before and after keratoplasty surgery, as well as with a mini-scleral contact lens, and after 6 months of lens wear. K = keratoplasty surgery.

improved with the best spectacle-correction (0.52 ± 0.33 ; $p = 0.33$). An average of 5 months (range 3 to 8) elapsed before fitting the SL. Once fitted, patients improved up to 0.12 ± 0.12 ($p = 0.01$, when compared to the best spectacle-correction). These outcomes were maintained during the 6-month follow-up (Figure 2). Fourteen eyes were fitted with SL measuring 16.50 mm in diameter and eight eyes with SL measuring 15.80 mm in diameter. The mean back optic zone radius was 7.89 ± 0.68 . A prolate MSK design was manufactured for 19 lenses and a reverse MSK design for 3. An average of 1.33 ± 0.50 lenses (range 1 to 2) were required until deemed optimal for dispensing, and 2.68 ± 0.75 visits (range 2 to 4) were needed to complete the fitting process. During the follow-up period (6 months), six patients discontinued SL wear (27.3%). The reasons for discontinuation were that 2 patients had corneal graft rejection, 2 experienced intolerance or discomfort, 1 was dissatisfied with his/her vision, and 1 found it difficult to insert and remove the SL. Among the other 16 patients, the mean daily wear time was 11.47 ± 1.52 h. Fourteen patients stated that SL were comfortable or very comfortable, and 2 reported them to be neither uncomfortable nor comfortable. In addition, all of them improved two or more decimal lines when compared to the best spectacle-corrected vision and reported that their visual quality was favourable or very favourable. These results demonstrate that 14 of 16 patients (87.5%) achieved a completely successful fitting. No significant adverse ocular events occurred during this period.

Discussion

The patients in the present study were mainly males (16/6) and the mean age was 48 years. These demographic values concur with those of previous studies fitting SL in post-keratoplasty eyes, where the proportion of males was significantly higher than females (approximately 2/3 males and 1/3 females).¹⁵⁻¹⁸ In addition, the mean age in these

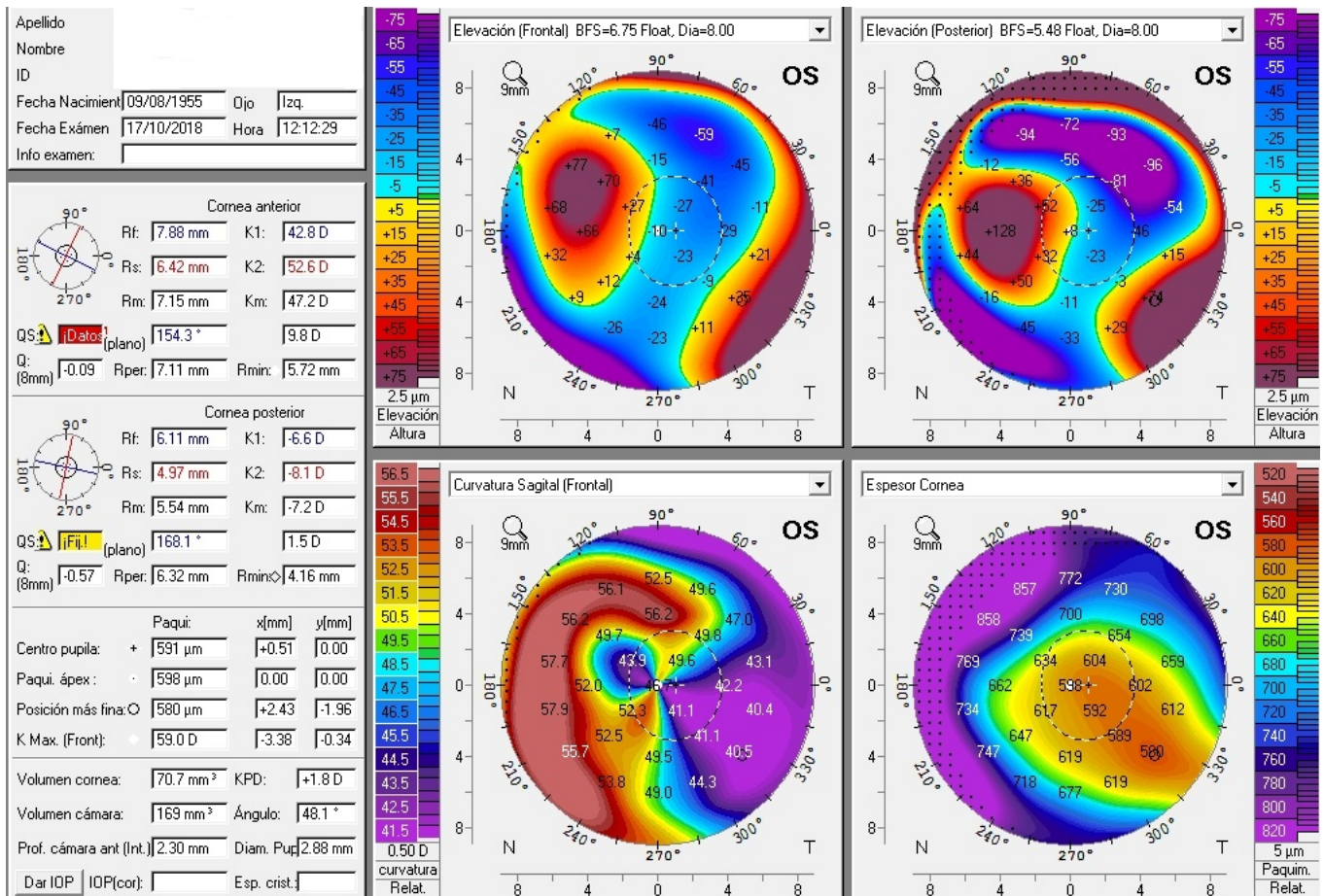


Figure 3: Pentacam corneal topography in a post-keratoplasty left eye. Anterior elevation map (top left). Posterior elevation map (top right). Keratometric map (bottom left). Pachymetry map (bottom right).

studies ranged between 43 to 59 years, and they reported that keratoconus was the main indication for keratoplasty, as do the results in this study. After keratoplasty, in some cases, fitting contact lenses represents a unique challenge. It should be noted that the reattachment of the corneal graft in the bed of the new cornea may cause a complex irregular corneal shape. Commonly, there is no continuous transition from the centre to the periphery of the cornea, and it presents irregular areas where there is a different flattening between the meridians (Figure 3). Moreover, keratoplasty can be steeper or flatter than the host cornea, and in many cases a mixture of both in different areas of the cornea. Therefore, a great variability of corneal profiles can be found in these patients. Consequently, when visual outcomes are suboptimal with the best spectacle-correction, contact lenses (mainly rigid gas-permeable as reported previously) are a suitable option for visual rehabilitation and/or restoring binocular vision (if refractive anisometropia occurs). The fitting procedure of SL was based on the sagittal depth. The lens should vault the cornea with sufficient central, paracentral and limbal clearance (approximately 200, 100, 50 µ after lens settling, respectively). A sagittal depth that is too great may cause

central bubbles under the lens, as well as less visual acuity. The landing curve should rest on the sclera aligned parallel to the conjunctiva. An excessive compression on conjunctival blood vessels or impingement should be avoided [18,29]. In the process of selecting the trial lens, the software used to simulate the fit was significantly helpful, so much so that 16 of 22 cases (72.7%) only needed one lens for dispensing, and in the other 6 cases, only two were needed. Changes were made to increase the corneal clearance (2 cases), and variations in the limbal and/or landing curve for the other four cases. Moreover, the majority of cases only needed two or three visits to complete the fitting process. Therefore, the fitting procedure appears to be feasible for the mini-SL used in the present study. Although patients achieved an improved of visual acuity after keratoplasty (0.52 ± 0.33), they were still unsatisfied with their best spectacle-correction. However, after fitting the mini-SL, they achieved an average of 0.12 ± 0.12 logMAR visual acuity, which concurs with previous studies in fitting SL in post-keratoplasty eyes (range 0.09 to 0.21).¹⁵⁻¹⁹ It should be noted that those previous studies that fitted greater diameters (18.50 or 19 mm) presented slightly worse logMAR visual acuity values

[15,16]. A greater amount of fluid-reservoir behind the lens could be the cause in these cases.²⁹ Therefore, fitting mini-SL with diameters between 15.80 and 16.50mm (as in the present study) may provide better visual rehabilitation [17-19]. After 6 months the follow-up, the rate of discontinuation of mini-SL wear was 27.3% (6 of 22 cases). Two previous studies on post-keratoplasty eyes reported similar values (35.4% and 27%);^{18,15} however, in other studies these rates were lower than 20% [16,19]. The concept of successful fitting (including efficacy and patient satisfaction) is rarely reported in the literature. Ortenberg et al. referred to success in wearing time as being able to wear a SL for at least 10 h a day.¹⁵ Another study developed a questionnaire to determine subjective aspects of the patients having a mini-SL fitted.²³ On a scale of 0 to 10 points, patients were asked about aspects of "Comfort", "Visual quality", "Handling rating", and "Wearing time". The authors referred to these aspects as subjective scores for efficacy in successfully fitted patients. However, no success criteria were reported. Recently, studies fitting corneo-scleral lenses in keratoconus patients used the same successful fitting criteria as those used in the present study [27,28]. According to the successful fitting criteria used, of the 16 patients who completed this study, 14 patients achieved complete success (daily wear time \geq 10h, comfortable or very comfortable lens wear, favourable or very favourable subjective visual quality, and decimal visual acuity improved two or more lines compared to the best spectacle-correction after keratoplasty), and two patients were considered as partially successful (subjective comfort was neither uncomfortable nor comfortable). The mean daily wear time of the 16 patients was 11.47 h. Other previous studies fitting SL in post-keratoplasty eyes also reported similar values (range 9.62 to 11.8 h a day) [15-17]. Finally, no significant complications were found during the follow-up period. Two cases presented mild adverse events, such as slight conjunctival hyperaemia. These cases were resolved with a lubricant and weak hypotonic ophthalmic solution (0.1 % of sodium hyaluronate) without preservatives, moreover removal and cleaning of the lens after 6 h of wear. Future studies with a greater sample size are needed to confirm the outcomes of this study.

Conclusions

Mini-scleral lenses may be a valid alternative option for eye care providers when treating complicated eyes after keratoplasty surgery with a significant degree of astigmatism and/or refractive anisometropia, like the cases presented in this manuscript. Hence, they may provide visual rehabilitation and/or restoring binocular vision with significant efficacy and patient satisfaction.

The authors report no proprietary or commercial interest in any product mentioned or concept discussed in this article.

References

1. Reinhart WJ, Musch DC, Jacobs DS, et al. Deep anterior lamellar keratoplasty as an alternative to penetrating keratoplasty; a report by the American Academy of Ophthalmology. *Ophthalmology* 118 (2011): 209-218.
2. Asena L, Altinors DD, Yilmaz G, et al. Visual rehabilitation after penetrating keratoplasty. *Exp Clin Transplant* 14 (2016): 130-134.
3. Wietharn BE, Driebe WT. Fitting contact lenses for visual rehabilitation after penetrating keratoplasty: *Eye Contact Lens Sci Clin Pract* 30 (2004): 31-33.
4. Bruce AS, Catania LJ. Clinical applications of wavefront refraction. *Optom Vis Sci* 91 (2014): 1278-1286.
5. Pantanelli S, MacRae S, Jeong TM, et al. Characterizing the wave aberration in eyes with keratoconus or penetrating keratoplasty using a high-dynamic range wavefront sensor. *Ophthalmology* 114 (2007): 2013-2021.
6. Eggink FA, Nuijts RM. A new technique for rigid gas permeable contact lens fitting following penetrating keratoplasty. *Acta Ophthalmol Scand* 79 (2001): 245-250.
7. Lin JC, Cohen EJ, Rapuano CJ, et al. RK4 (Reverse-Geometry) contact lens fitting after penetrating keratoplasty. *Eye Contact Lens* 29 (2003): 44-47.
8. Gruenauer-Kloevekom C, Kloevekom-Fischer U, Duncker GI. Contact lenses and special back surface design after penetrating keratoplasty to improve contact lens fit and visual outcome. *Br J Ophthalmol* 89 (2005): 1601-1608.
9. Geerards AJ, Vreugdenhil W, Khazen A. Incidence of rigid gas-permeable contact lens wear after keratoplasty for keratoconus: *Eye Contact Lens* 32 (2006): 207-210.
10. Phan VA, Kim YH, Yang C, et al. Bitoric rigid gas permeable contact lenses in the optical management of penetrating keratoplasty. *Contact Lens Anterior Eye* 37 (2014): 16-19.
11. Segal O, Barkana Y, Hourovitz D, et al. Scleral contact lenses may help where other modalities fail. *Cornea* 22 (2003): 308-310.
12. Visser ES, Visser R, Van Lier HJ, et al. Modern scleral lenses part I: clinical features. *Eye Contact Lens* 33 (2007): 13-20.
13. Visser ES, Visser R, Van Lier HJ, et al. Modern scleral lenses part II: patient satisfaction. *Eye Contact Lens* 33 (2007): 21-25.
14. Romero-Jiménez M, Flores-Rodríguez P. Utility of a semi-scleral contact lens design in the management of the irregular cornea. *Cont Lens Anterior Eye* 36 (2013): 146-150.

15. Ortenberg I, Behrman S, Geraisy W, et al. Wearing time as a measure of success of scleral lenses for patients with irregular astigmatism. *Eye Contact Lens* 39 (2013): 381-384.
16. Severinsky B, Behrman S, Frucht-Pery J, et al. Scleral contact lenses for visual rehabilitation after penetrating keratoplasty: long term outcomes. *Cont Lens Anterior Eye* 37 (2014): 196-202.
17. Alipour F, Behrouz MJ, Samet B. Mini-scleral lenses in the visual rehabilitation of patients after penetrating keratoplasty and deep lamellar anterior keratoplasty. *Cont Lens Anterior Eye* 38 (2015): 54-58.
18. Barnett M, Lien V, Li JY, et al. Use of scleral lenses and miniscleral lenses after penetrating keratoplasty: *Eye Contact Lens* 42 (2016): 185-189.
19. Rocha GA, Miziara PO, Castro AC, et al. Visual rehabilitation using mini-scleral contact lenses after penetrating keratoplasty. *Arq Bras Oftalmol* 80 (2017): 17-20.
20. Abou Samra WA, Badawi AE, Kishk H, et al. Fitting tips and visual rehabilitation of irregular cornea with a new design of corneoscleral contact lens: objective and subjective evaluation. *J Ophthalmol* 12 (2018): 1-8.
21. De Luis Eguileor B, Etxebarria Ecenarro J, Santamaria Carro A, et al. Irregular corneas: improve visual function with scleral contact lenses. *Eye Contact Lens* 44 (2018): 159-163.
22. Ozek D, Kemer OE, Altıaylık P. Visual performance of scleral lenses and their impact on quality of life in patients with irregular corneas. *Arq Bras Oftalmol* 81 (2018): 475-480.
23. Suarez C, Madariaga V, Lepage B, et al. First Experience With the ICD 16.5 mini-scleral lens for optic and therapeutic purposes. *Eye Contact Lens* 44 (2018): 44-49.
24. Gemoules G. Therapeutic effects of contact lenses after refractive surgery. *Eye Contact Lens* 31 (2005): 12-22.
25. Katsoulos C, Nick V, Lefteris K, et al. Fitting the post-keratoplasty cornea with hydrogel lenses. *Cont Lens Anterior Eye* 32 (2009): 22-26.
26. Altay Y, Balta O, Burcu A, et al. Hybrid contact lenses for visual management of patients after keratoplasty. *Niger J Clin Pract* 21 (2017): 451-455.
27. Montalt JC, Porcar E, España-Gregori E, et al. Visual quality with corneoscleral contact lenses for keratoconus management. *Cont Lens Anterior Eye* 41 (2018): 351-356.
28. Montalt JC, Porcar E, España-Gregori E, et al. Visual quality with corneo-scleral contact lenses after intracorneal ring segment (ICRS) implantation for keratoconus management. *Cont Lens Anterior Eye* 42 (2019): 111-116.
29. Van der Worp E. *A Guide to Scleral Lens Fitting, Version 2.0* [monograph of the Internet]. Forest Grove, OR: Pacific University; 2015 [cited 30 Jan 2020]. Available from: <http://commons.pacificu.edu/mono/10/>