



Case Series

Treatment of Interface Fluid Syndrome after Laser-Assisted In Situ Keratomileusis with Descemet Membrane Endothelial Keratoplasty in Three Patients with Corneal Endothelial Dysfunction

Guillermo Rodríguez-Iranzo^{1*}, María José Roig-Revert¹, Ester Fernández-López¹, Cristina Peris-Martínez¹⁻³

¹Department of Cornea and External Diseases, Fundación Oftalmológica Médica (FOM), Valencia, Spain

²Department of Surgery, University of Valencia, Ophthalmology, Valencia, Spain

³Aviñó, Peris Eye Clinic, Valencia, Spain

***Corresponding author:** Guillermo Rodríguez Iranzo, Department of Cornea and External Diseases, Fundación Oftalmológica Médica (FOM), Av. Pío Baroja 12, 46015 Valencia, Spain

Citation: Rodríguez-Iranzo G, Roig-Revert MJ, Fernández-López E, Peris-Martínez C (2023) Treatment of Interface Fluid Syndrome after Laser-Assisted In Situ Keratomileusis with Descemet Membrane Endothelial Keratoplasty in Three Patients with Corneal Endothelial Dysfunction. J Surg 8: 1765 DOI: 10.29011/2575-9760.001765

Received Date: 21 March, 2023; **Accepted Date:** 24 March, 2023; **Published Date:** 27 March, 2023

Abstract

Descemet Membrane Endothelial Keratoplasty (DMEK) has become a first-line treatment in corneal endothelial diseases owing to its exceptional clinical outcomes and low complication rates. Thanks to its refractive predictability and the ability to reshape the superficial cornea, DMEK is now also considered for managing cases with endothelial decompensation following previous refractive procedures. This article reviews the clinical outcomes of DMEK in three patients with Interface Fluid Syndrome (IFS), a complication of laser-assisted in situ keratomileusis (LASIK) in which endothelial failure can play a major role.

Keywords: Descemet membrane; Endothelial keratoplasty; Interface fluid; Keratomileusis

Introduction

IFS is a potentially vision-threatening complication of LASIK which is mainly triggered by a rise in IOP secondary to prolonged steroid application and typically arises several weeks to a few months after LASIK [1]. However, endothelial cell dysfunction has also been described as a significant cause of IFS, secondary to Fuchs' Endothelial Dystrophy (FED) [2-5], cataract surgery [6,7]

or uveitis [8]. In cases of endothelial decompensation, the onset of IFS may be years or decades after LASIK. Fluid accumulates in the stromal interface owing to its relative weakness and richness in fibrin bound proteoglycans which mainly absorb water compared with the rest of the corneal stroma [9].

We present three cases of IFS after LASIK which were successfully treated with DMEK and we also provide a review of some technical details that we have to consider during surgery to avoid LASIK-flap dislocation.

Cases Description

Case 1

A 64-year-old male was referred to our hospital for decreasing visual acuity in the Right Eye (RE) over the previous months. Fifteen years earlier, he had undergone bilateral external LASIK for the correction of myopia (about -5 diopters). Cataract surgery was performed in the RE 6 months prior to this visit, with no complications and intraocular lens (IOL) implantation in the capsular bag. His Best-Corrected Visual Acuity (BCVA) in the RE at presentation was Counting Fingers (CF) at 1/2 meter. Intraocular Pressure (IOP) was 2 mmHg measured with Goldmann Applanation Tonometer (GAT). Anterior segment (Figure 1) and fundus examination of the RE disclosed anterior stromal haze and edema, diffuse subepithelial bullae, LASIK flap in the corneal periphery, well positioned IOL, myopic central retinopathy and tilted optic disc. Central Corneal Thickness (CCT) (Pentacam® HR, Oculus Optikgeräte GmbH, Wetzlar, Germany) measured 664 µm. Endothelial cell density could not be assessed in the RE due to the advanced bullous keratopathy but in the Left Eye (LE) it was normal. Anterior segment optical coherence tomography (AS-OCT) (Visante OCT; Carl Zeiss Meditec, Jena, Germany) of the RE showed a fine hyporeflective interface between the LASIK-flap and the residual stromal bed, corresponding to an IFS (Figures 2 and 3).

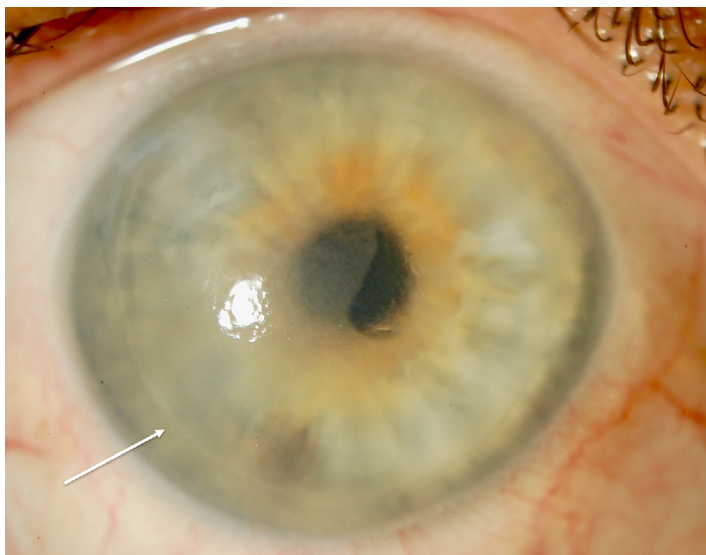


Figure 1: Anterior segment photograph of the RE at initial presentation showing stromal haze and edema with diffuse subepithelial bullae. Note the presence of the LASIK flap in corneal periphery, near the limbus (white arrow).

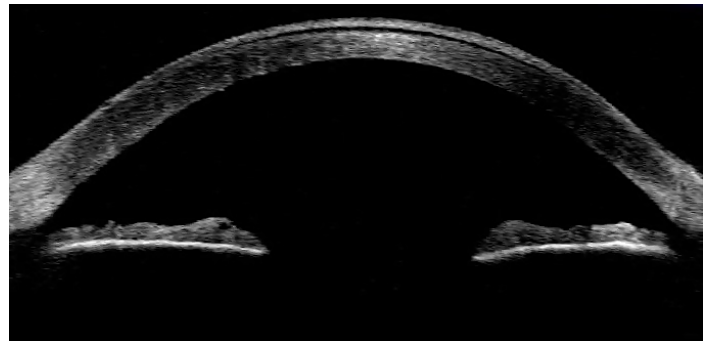


Figure 2: AS-OCT of the RE at initial presentation which reflects a fine hyporeflective interface between the LASIK-flap and the residual stromal bed, corresponding to an IFS. The underlying central hyperreflective edema can also be noticed.

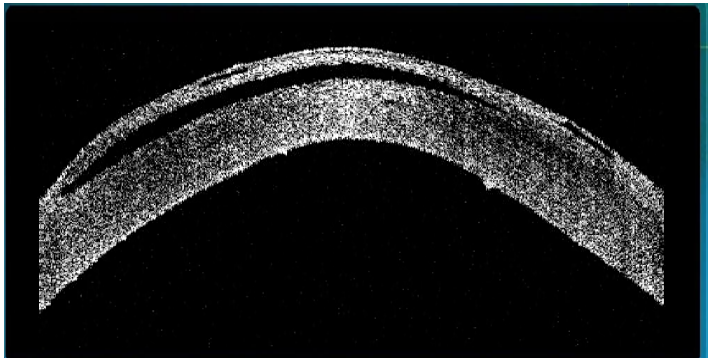


Figure 3: AS-OCT of the RE at initial presentation showing the IFS and the underlying edematous cornea. Subepithelial bullae can also be observed in the context of a pseudophakic bullous keratopathy.

Assuming that IFS and corneal stromal edema were due to insufficient corneal endothelial function, an intensive medical management with topical and subconjunctival steroids together with antihypertensive drops was initiated with no objective improvement of corneal decompensation at subsequent visits. Finally, DMEK was carried out 6 months after the initial consultation without complications. A 8 mm central descemetorrhexis was done prior filling of the Anterior Chamber (AC) with air, avoiding excessive tensile forces against the inner corneal surface. Main incision of 2.75 mm was completed outside the flap area at 12 o'clock. 3 more accessory smaller incisions were performed. After staining (0.06% Trypan blue solution, VisionBlue; DORC® International), the DMEK graft was loaded into an injector (DMEK-inserter; DORC® International) and introduced into the AC. After proving correct orientation, graft unfolding and centration were accomplished with minimal manipulation from the outer corneal surface, pulling the graft carefully with a cannula from the Descemet side towards the required location. Sulfur hexafluoride (20%) gas was used to

attach the donor lamella. In addition, intraoperative iridectomy was performed to prevent the gas from causing pupillary block. Postoperative medication included topical antibiotics and steroids. At 1 day after surgery, the DMEK graft was completely attached. However, the interface cleft seemed to be enlarged (Figure 4). IOP assessed by rebound tonometry (Icare ic100®) was 4.0 mmHg. Within 1 month, the graft continued attached, cornea became clearer (Figure 5), BCVA improved to + 0.70 LogMAR with reabsorption of all the interface fluid (Figure 6) and CCT decreased to 566 µm. At 6 months, the refraction in the RE was sph + 1.00 cyl -1.50 x 50 degrees and BCVA 0.15 LogMAR.

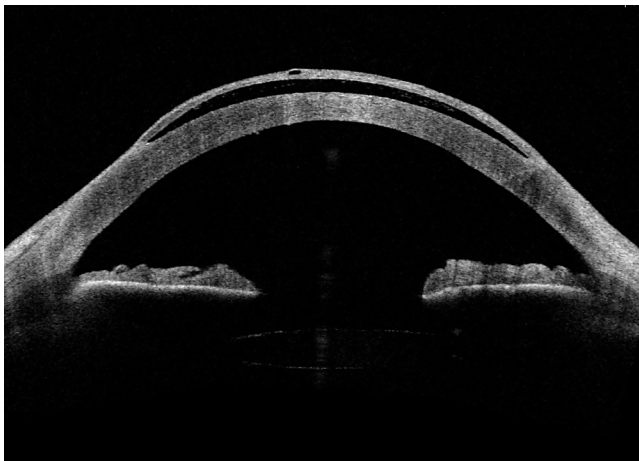


Figure 4: Postoperative day 1 status after DMEK surgery. AS-OCT of the RE demonstrating the fully attached functioning DMEK graft. Note that the interface cleft seems enlarged.

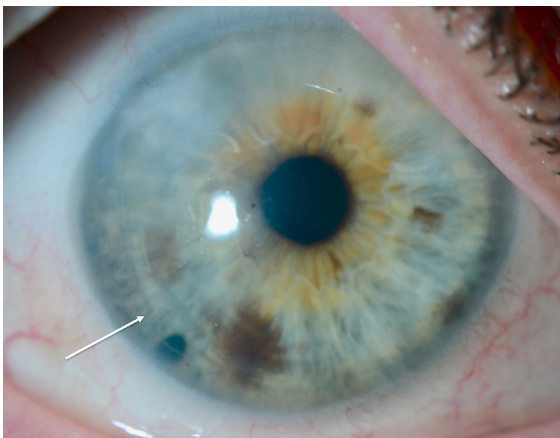


Figure 5: Postoperative 1 month status after DMEK surgery. Slit-lamp photograph of the RE which illustrates a clear cornea. LASIK flap is again observed in the corneal periphery with no visible edema next to the wound (white arrow). Inferior iridectomy is also showed.

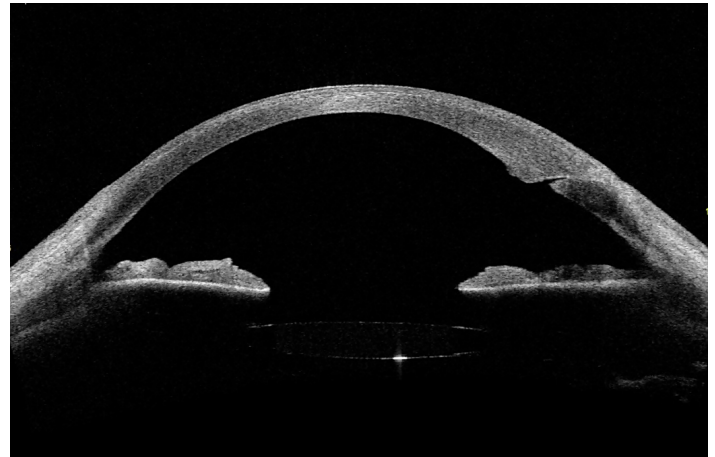


Figure 6: Postoperative 1 month status after DMEK surgery. AS-OCT of the RE showing resolution of interface fluid accumulation, stromal bed thinning and the attached functioning DMEK graft.

Case 2

A 57-year-old male complained of progressive vision in the LE over the previous year. Twenty years earlier, he had undergone bilateral external LASIK together with the insertion of a phakic Artisan IOL (Ophtec BV, Groningen, The Netherlands) in both eyes for the correction of hypermetropia and astigmatism. This IOL was explanted in the LE one year before the initial consultation in our hospital due to the accelerated endothelial cell loss and the initial corneal decompensation. His BCVA in the LE at presentation was 0.4 LogMAR. IOP was 10 mmHg measured with GAT. Slit-lamp examination of the LE disclosed moderate corneal opacity, guttae, LASIK flap in the corneal periphery and a nuclear cataract. Endothelial cell density showed a FED in both eyes. First, phacoemulsification with IOL was performed without complications in his LE. Three months after surgery, the anterior segment exploration showed edema around the LASIK flap and the AS-OCT showed an IFS (Figure 7). BCVA was 1.0 LogMAR and IOP was 4 mmHg measured with GAT. Four months after phacoemulsification, DMEK was carried out without complications and following the same surgical steps and postoperative measures as in case report one.

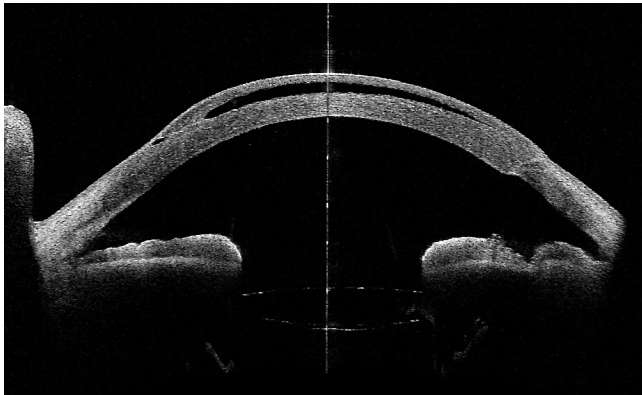


Figure 7: AS-OCT of the LE 3 months after cataract surgery. Fluid is present at the LASIK interface and a thickened stromal bed is also observed.

At 1 day after DMEK surgery, the graft was completely attached and the IFS remained similar; IOP, assessed by rebound tonometry (Icare ic100®) was 6.0 mmHg. However, corneal edema continued at subsequent visits despite intensive topical steroid drops and a new DMEK was performed. After one month of the second graft surgery, cornea was clearer, the DMEK continued attached and the IFS was completely solved (Figures 8 and 9). At 6 months after this second graft, the refraction in the LE was sph + 5.00 cyl -1.50 x 50 degrees and BCVA 0.1 LogMAR.

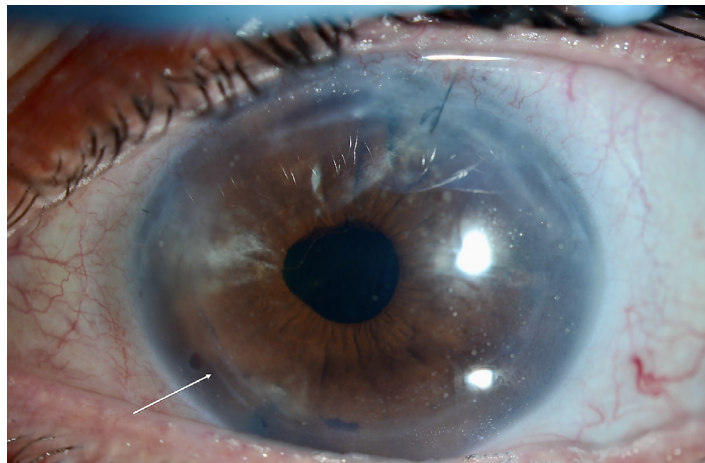


Figure 8: Anterior segment photograph of the LE taken 1 month after the second DMEK surgery, showing corneal transparency. Note the presence of LASIK flap in corneal periphery (white arrow), an inferior iridectomy and a single superior Nylon 10/0 suture.

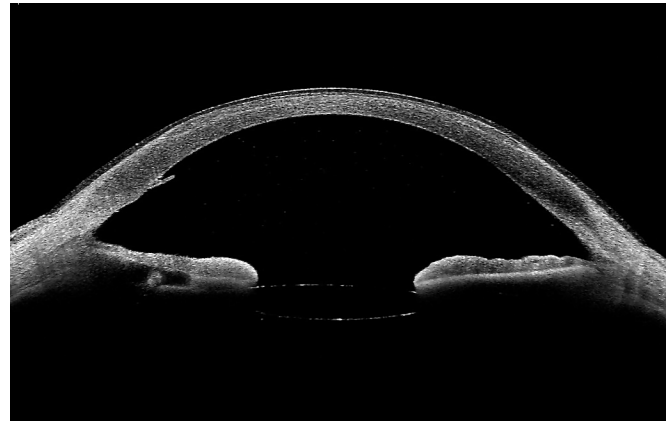

Figure 9: Postoperative 1 month status after the second DMEK surgery. AS-OCT of the LE which illustrates the resolution of IFS, stromal bed thinning and an attached functioning DMEK graft.

Case 3

An 81 year-old male presented at our hospital for cataract surgery. Thirty years earlier, he had undergone LE LASIK for the correction of myopia. His BCVA in the LE at presentation was 0.5 LogMAR. IOP was 10 mmHg measured with GAT. Slit-lamp examination of the LE disclosed guttae, LASIK flap in the corneal periphery and a corticonuclear cataract. Endothelial cell density showed a FED in both eyes. First, phacoemulsification with IOL was done without complications in his LE. In the immediate postoperative period, corneal edema was noticed, the LASIK flap was swollen and the AS-OCT showed an IFS. One month after cataract surgery, cornea remained edematous despite intensive steroid topical treatment and the IFS improved but a mild fluid accumulation was still present (Figure 10). BVCA was CF at 1/2 metre. DMEK was carried out 3 months after phacoemulsification without complications following the same surgery steps and postoperative measures as in clinical cases 1 and 2. At 1 day after surgery, the DMEK graft was completely attached. The IOP, assessed by rebound tonometry (Icare ic100®) was 12.0 mmHg. Within 1 month, the graft continued attached, cornea became clearer with reabsorption of all the interface fluid (Figure 11). At 6 months, the refraction in the LE was cyl - 5.00 x 35 degrees with a BCVA of 0.5 LogMAR.

The demographic characteristics of the three cases described are summarized in Table 1.

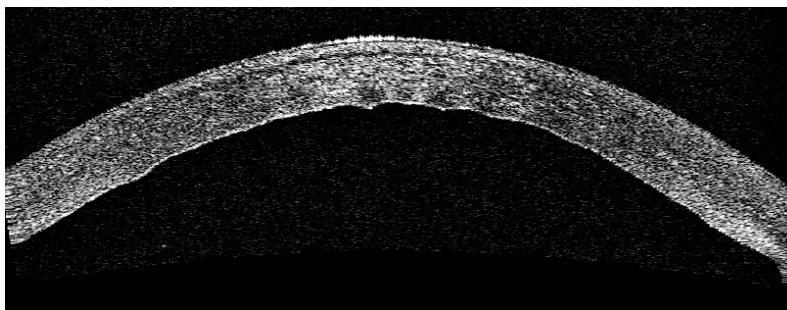


Figure 10: AS-OCT of the LE at initial presentation which reflects a mild accumulation of fluid in the LASIK interface. The underlying central hyperreflective edema can also be noticed.

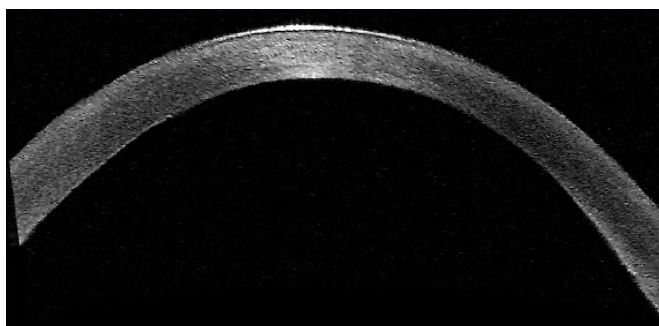


Figure 11: Postoperative 1 month status after DMEK surgery. AS-OCT of the LE demonstrating complete resolution of IFS and an attached DMEK graft.

	Case 1	Case 2	Case 3
Patient's age	64 years old	57 years old	81 years old
BCVA before DMEK	CF	1.0 LogMAR	CF
IFS latency period (after LASIK)	15 years	20 years	25 years
FED	No	Yes	Yes
IFS triggering factor	Phacoemulsification	idem	idem
IFS time of resolution after DMEK	1 month	1 month (after 2 nd DMEK)	1 month
BCVA 6 months after DMEK	0.15 LogMAR	0.1 LogMAR (after 2 nd DMEK)	0.5 LogMAR

Table 1: Comparison of the main variables in the 3 reported cases. Legend: BCVA - best corrected visual acuity; DMEK – Descemet membrane endothelial keratoplasty; CF – counting fingers; IFS: Interface fluid syndrome; LASIK: laser-assisted in situ keratomileusis; FED: Fuchs' endothelial dystrophy.

Discussion

The three clinical cases reported highlight the mechanism of IFS based on endothelial dysfunction. FED could be detected in two patients and phacoemulsification acted as a trigger for corneal decompensation and the IFS onset in all of them. Treatment options for IFS include conservative topical therapy or surgical approach in the form of corneal lamellar graft using a DMEK [2,3,10] or a Descemet's stripping automated endothelial keratoplasty (DSAEK) [11]. Surgical treatment for corneal decompensation can improve IFS due the capacity of DMEK to remodelate the entire corneal architecture and not only the posterior surface. In our case, DMEK was proposed to restore corneal endothelial dysfunction and secondarily solve the IFS, both objectives successfully achieved in the

postoperative period in the three cases, although in one patient it was necessary to perform a new DMEK. During DMEK surgery in a patient who has undergone previous LASIK, corneal incisions should be performed outside the flap area to avoid flap dislocations, excessive tensile lines during descemetorrhexis are forbidden and graft manipulation from the outer corneal surface should be reduced. After surgery, the interface cleft may seem to have initially increased due to the immediate functionality of endothelial cells as happened in the first case and in the one described by Luceri et al [3].

Although the published evidence is limited and consists of a few numbers of cases, the resolution of IFS is usually fast after endothelial keratoplasty, with few complications. Only one case in the literature showed a Descemet's stripping endothelial keratoplasty and flap elevation ending with a full-thickness keratoplasty [12]. The average time for fluid reabsorption in our case series was 1 month. Any intraocular procedure could promote the onset of IFS in a context of endothelial dysfunction, despite the vast majority of cases are described after cataract surgery. One example of this is explained by Wolf et al [4] in a clinical case in which DMEK is assumed that triggered the IFS. Finally, we emphasize a careful management of the IOP in the early postoperative period after DMEK surgery in order to avoid the onset or recurrence of the IFS and prevent any secondary damage of the optic nerve.

Conclusion

In short, DMEK is a safe and effective surgery to reverse IFS after LASIK in an eye with endothelial dysfunction. Due to the increasing incidence of this vision-impairing eye disease, it is worth keeping the IFS in mind when grading LASIK surgical risk. Certain details during surgery must be taken into account in these patients in order to avoid LASIK-flap dislocation.

References

1. Kang SJ, Dawson DG, Hopp LM, Schmack I, Grossniklaus HE, et al. (2006) Interface fluid syndrome in laser in situ keratomileusis after complicated trabeculectomy. *J Cataract Refract Surg* 32: 1560-1562.
2. Shajari M, Rafiezadeh P, Pavlovic I, Kubiak KB, Köhnen T, et al. (2017) Management of interface fluid syndrome after LASIK by Descemet membrane endothelial keratoplasty in a patient With Fuchs' corneal endothelial dystrophy. *J Refract Surg* 33: 347-350.
3. Luceri S, Baksoellah Z, Ilyas A, Baydoun L, Melles GR (2016) Interface fluid syndrome after laser in situ keratomileusis (LASIK) because of Fuchs endothelial dystrophy reversed by Descemet Membrane Endothelial Keratoplasty (DMEK). *Cornea* 35: 1658-1661.
4. Wolf BJ, Ma L, Batta P (2021) Interface fluid syndrome after Descemet membrane endothelial keratoplasty. *J Refract Surg Case Rep* 1: 1795.
5. Galvis V, Berrospi RD, Tello A, Santaella G (2019) Interface Fluid Syndrome (IFS) following Toxic Anterior Segment Syndrome (TASS): not related to high intraocular pressure but to endothelial failure. *Saudi J Ophthalmol* 33: 88-93.
6. Ortega-Usobiaga J, Martín-Reyes C, Llovet-Osuna F, Damas-Mateache B, Baviera-Sabater J (2012) Interface fluid syndrome in routine cataract surgery 10 years after laser in situ keratomileusis. *Cornea* 31: 706-707.
7. Han SB, Woo SJ, Hyon JY (2012) Delayed-onset interface fluid syndrome after laser in situ keratomileusis secondary to combined cataract and vitreoretinal surgery. *J Cataract Refract Surg* 38: 548-550.
8. Tendolkar S, Murthy SI, Chandran K, Joseph J (2021) Acute interface fluid syndrome after laser in situ keratomileusis in a case of cytomegalovirus (CMV) endotheliitis and secondary glaucoma. *BMJ Case Rep* 14: e236742.
9. Dawson DG, Schmack I, Holley GP (2007) Interface fluid syndrome in human eye bank corneas after LASIK: causes and pathogenesis. *Ophthalmology* 114: 1848-1859.
10. Moura-Coelho N, Arrondo E, Papa-Vettorazzi MR (2022) DMEK for the treatment of interface fluid syndrome secondary to failed DSAEK graft: A case report and review of the literature. *Am J Ophthalmol Case Rep* 27: 101656.
11. Srirampur A, Kalwad A, Mansoori T, Agraharam S (2019) Reversal of laser in situ keratomileusis interface fluid after Descemet stripping automated endothelial keratoplasty for pseudophakic bullous keratopathy. *Indian J Ophthalmol* 67: 1740-1742.
12. Hoffman RS, Fine IH, Packer M (2008) Persistent interface fluid syndrome. *J Cataract Refract Surg* 34: 1405-1408.